HKCEM JCM OSCE

06 March 3013

AED POH

Case 1

- M/52
- Walk unaided to AED
- c/o left foot sprain few days ago during working
- P/E swelling, tender over dorsum of foot


Se:7106
Im:1
Study Date:20/07/2012
Study Time:19:39:21
MRN:
C8192
W16384


Se:7106
Im:2
Study Date:20/07/2012
Study Time:19:39:21
MRN:
C8192
W16383

Questions

- What were the X ray findings
  - Avulsion fracture at the base of 2nd MT
  - Widened 1st and 2nd intermetatarsal joint space
  - Old fracture shaft of 3rd MT
- What was the name of the sign showed in X-ray?
  - Fleck's sign
- What was this injury call?
  - Lisfranc fracture dislocation

- What was the classification of this injury
  - Quenu and Kuss
    - Homolateral, isolated and divergent

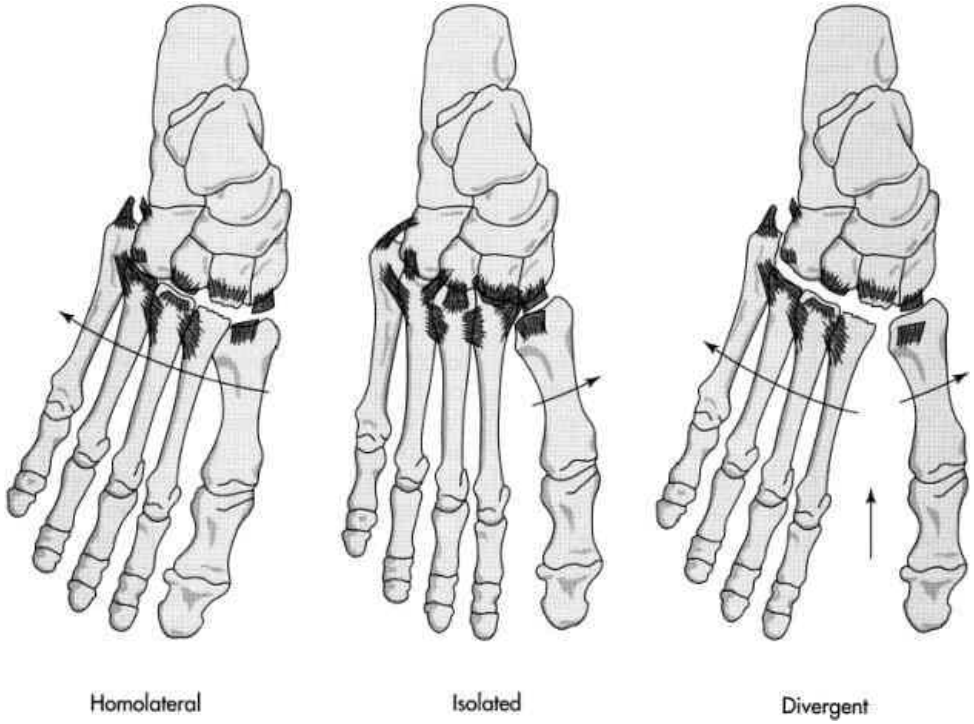

- What was the optimal management
  - ORIF
- What were the important complications
  - Acute:
    - compartment syndrome
    - Neurovascular injury
  - Chronic
    - Post-traumatic arthritis causing chronic pain

Case 2

- M/42
- Hx of stepping to nail
- Left sole wound unhealed for 6 months
- P/E: 4mm size ulcer in left sole, discharge +ve
- X ray left foot was taken


Study Date:29/12/2012
Study Time:12:38:53
MRN:
Se:8068
Im:2
C8183
W16533


Se:8496
Im:1
Study Date:08/01/2013
Study Time:17:14:14
MRN:
C8182
W16532

Questions

- What was the X ray finding
  - A tiny radio-opacity in the space between 4th and 5th metatarsal bone
- What you were suspected?
  - Retained foreign body in left foot
- What further investigations you would like to do to confirm the diagnosis?
  - Bedside ultrasound

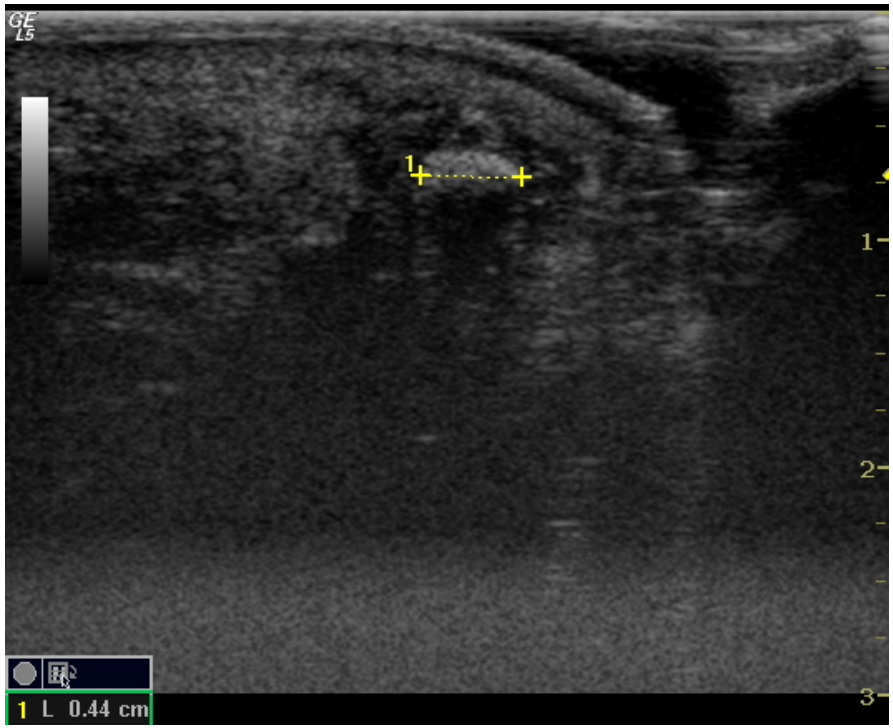
GE
L5
1
2
3
1 L 0.44 cm

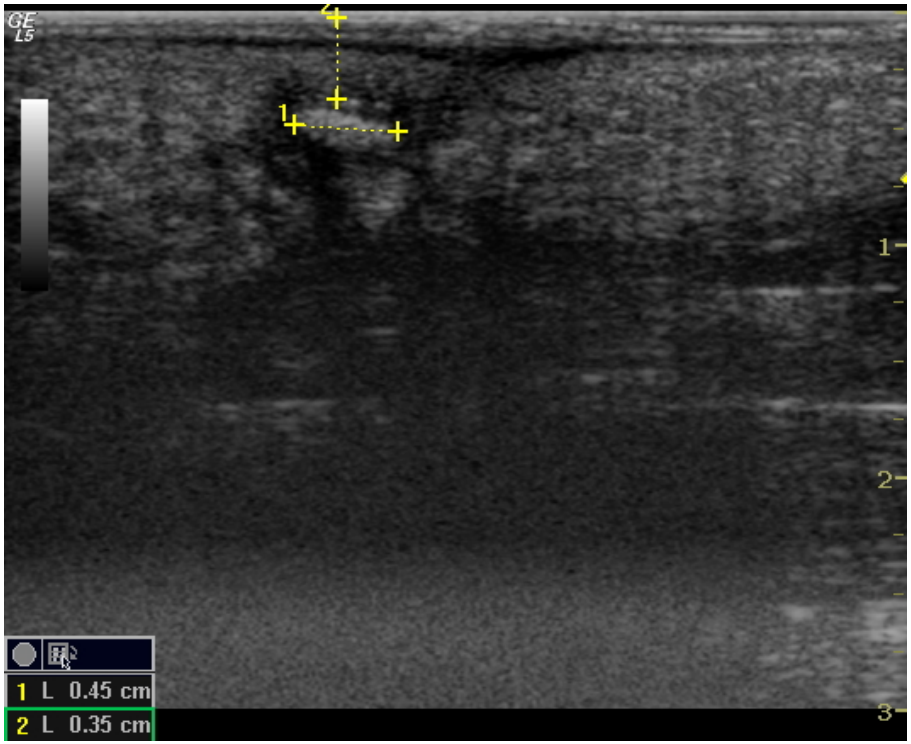
GE
L5
1
2
3
1 L 0.45 cm
2 L 0.35 cm

Questions

- Describe the ultrasound finding
  - A 0.45 cm echogenic focus with posterior ascoutic shadowing
  - It was located about 0.35 cm from the skin
  - It was surrounded by a hypoechoic halo

- What did you think about the nature of material that caused the problem? (Metal, glass, plastic or wood) Why?

	Ultrasonic Characteristic		X-ray Characteristic
	Echogenicity	Shadowing	Radio-opacity
Metal	++++	Comet tail artifact +	Highly radio-opaque
Glass	+++	Comet tail artifact +/-	Mostly radio-opaque
Wood	++	acoustic shadowing +	Mostly radiolucent
Plastic	+	acoustic shadowing +	Slightly radio-opaque

- What other investigation you would consider?
  - CT scan

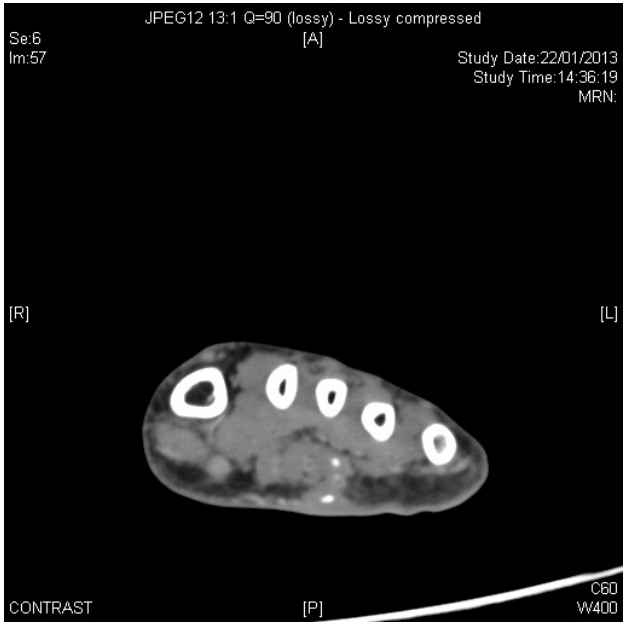

- What is your management?
  - Admit orthopedic for exploration and FB removal

Case 3

- F/59
- c/o: abd pain, vomiting and diarrhea x 1/7
- T 36
- Abd.:
  - Soft,
  - tender over lower abd., G^o/R^o
  - Mass -ve

Questions

- What bedside investigations you would consider?
  - Bedside glucose test (Hstix 5.8)
  - Urine for multistix (all negative)
  - Bedside ultrasound

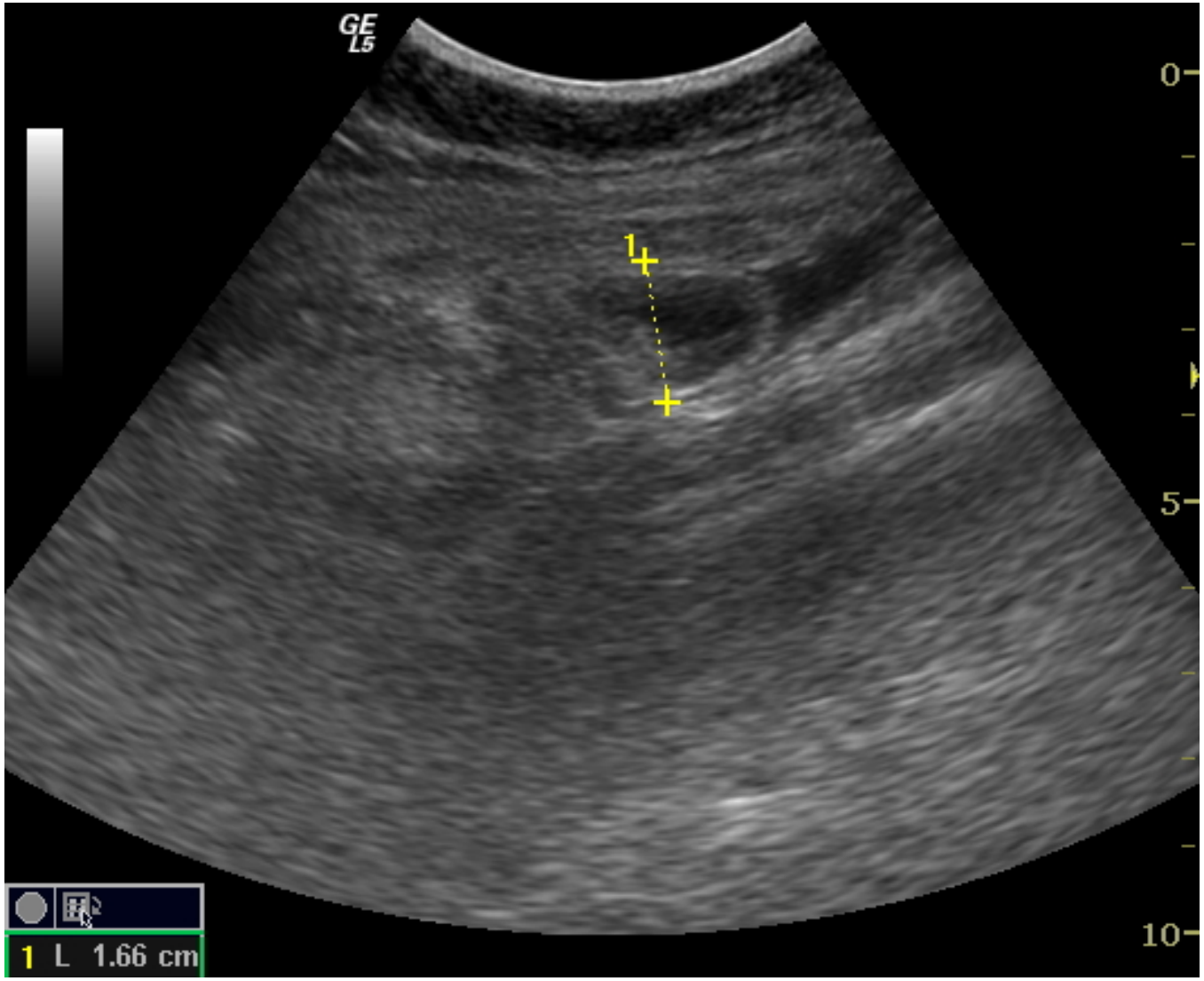
GE
L5
0
5
10
1
1 L 1.66 cm

- What were the ultrasound findings?
  - A long blind-ended tubular structure
  - The diameter was 1.66 cm
  - There was hypoechoic area at the tip of the structure suggesting of fluid collection
- What was the diagnosis?
  - Acute appendicitis

- What were the ultrasonic features of acute appendicitis?
  - (1) appendix on axial view >6mm in diameter
  - (2) non-compressible
  - (3) aperistaltic appenix
  - (4) peri-appendix fluid collection
  - (5) presence of an appendicolith (echogenic focus with posterior shadowing)

- Name 3 clinical signs of acute appendicitis
  - Psoas sign
  - Obturator sign
  - Rovsing's sign
- Name one scoring system for acute appendicitis
  - Alvarado scoring system

Alvarado Score for acute appendicitis

Symptoms	Score
Migratory right iliac fossa pain	1
Nausea/Vomiting	1
Anorexia	1
Sign	
Tenderness in right iliac fossa	2
Rebound tenderness in right iliac fossa	1
Elevated temperature	1
Laboratory findings	
Leukocytosis	2
Left shift of neutrophils	1
Total	10

5-6 → possible
7-8 → probable
>9 → very probable

Case 4

- M/40
- IVDA
- Personality disorder
- c/o LBP for 3 days
- No injury
- Could not walk

Questions

- What were the red flags of LBP?

Red flags for the cauda equina syndrome include:

- Saddle anaesthesia.
- Recent onset of bladder dysfunction or faecal incontinence.
- Major motor weakness.

Red flags that suggest spinal fracture include:

- Sudden onset of severe central pain in the spine which is relieved by lying down.
- Major trauma such as a road accident or fall from a height.
- Minor trauma, or even just strenuous lifting, in people with osteoporosis.
- Structural deformity of the spine.

Red flags that suggest cancer or infection include:

- Onset in a person over 50 years, or under 20 years, of age.
- History of cancer.
- Constitutional symptoms, such as fever, chills, or unexplained weight loss.
- Intravenous drug abuse.
- Immune suppression.
- Pain that remains when supine; aching night-time pain disturbing sleep; and thoracic pain *(which also suggests aortic aneurysm)*.

The basis for these red flag recommendations is from the synthesis of national and international guidelines which are largely based on expert opinion.

Reproduced from Back pain (low) and sciatica.


Se:676
Im:1
Study Date:12/10/2012
Study Time:05:52:37
MRN:
L
C8192
W16384

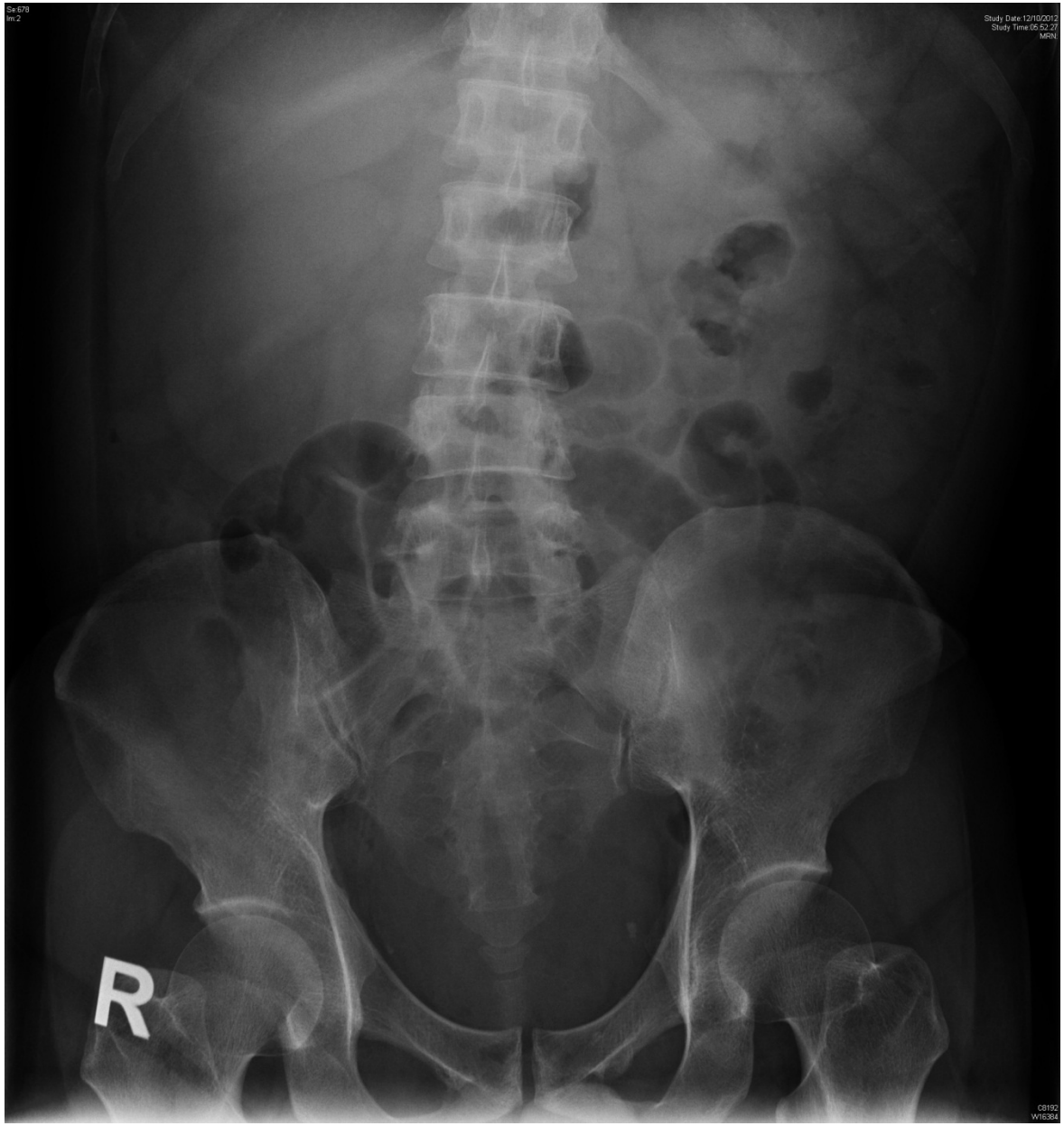
Se:678
Im:2
Study Date:12/10/2012
Study Time:05:52:37
MRN:
R
C8192
W16384

- What were the X ray findings?
  - Loss of lumbar lordosis
  - Decreased disc space of L3/4
  - Bone erosion in L4 body and upper end plate
- What were the differential diagnosis?
  - The DDx of non-traumatic LBP
    - Degenerative spondyloarthropathy
    - Infective (osteomyelitis, intraspinal abscess)
    - Inflammatory spondyloarthropathy (AS, IBD, psoriatic spondylitis, Reiter's syndrome)
    - Vascular (spinal epidural haematoma)
    - Malignancy (primary or secondary)

- What other imaging Ix you would consider?
  - MRI lumbar spine

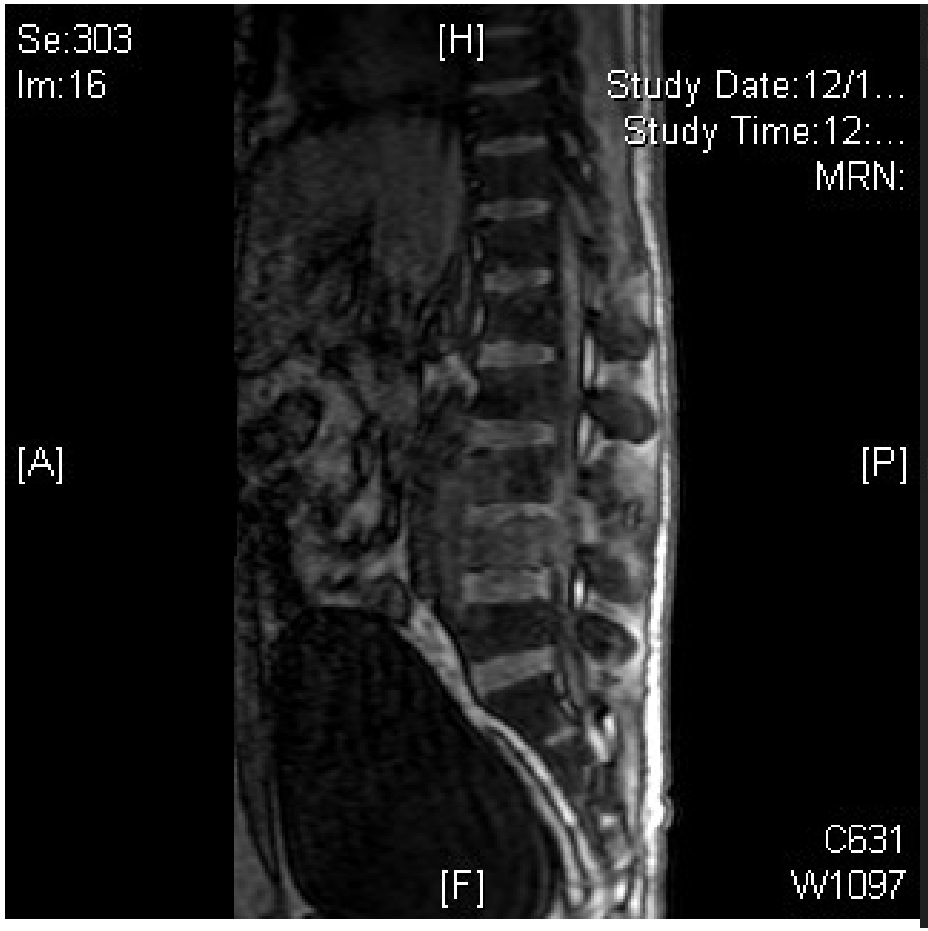

- How to manage this patient?
  - Admit orthopedics
    - exploration and decompression in spinal canal
    - surgical drainage of epidural abscess

Case 5

- M/35
- Amateur body builder
- c/o sudden sharp pain in left upper arm while practicing weight lifting

Questions

- Describe the abnormality showed in the clinical photo
  - A bulge in the upper arm above the elbow, with a dent closer to the shoulder
- What was the sign called?
  - 'Popeye' sign
- What bedside investigation would help in diagnosis in ED?
  - Bedside ultrasound

Figure 1

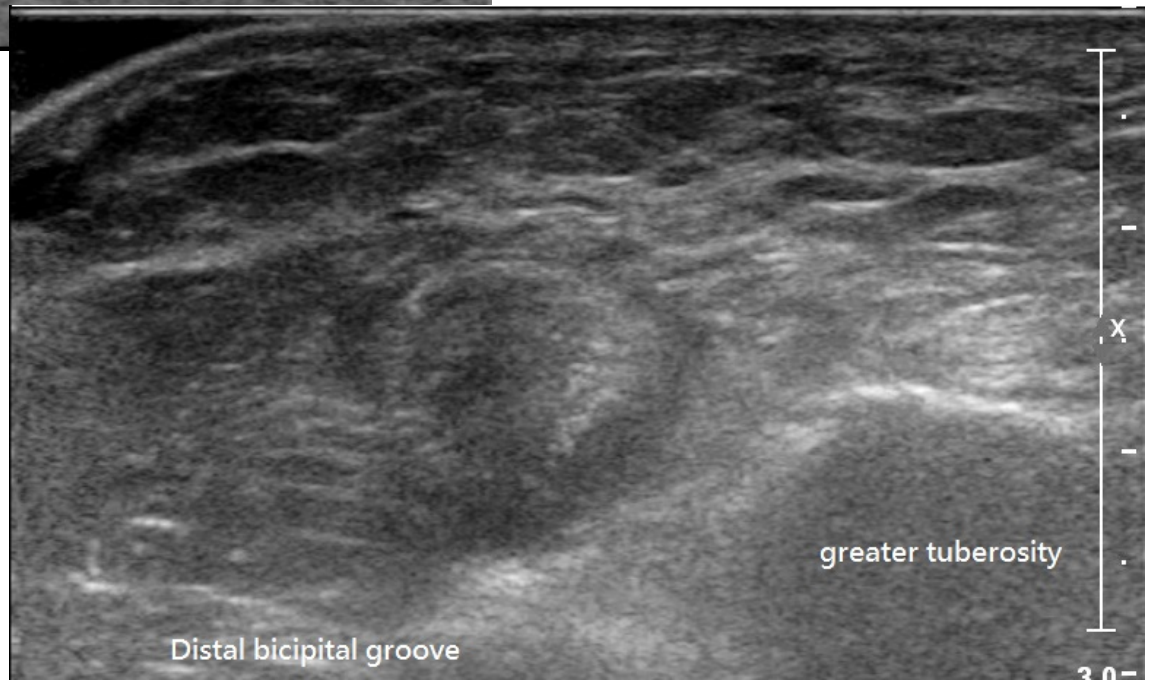

Figure 2

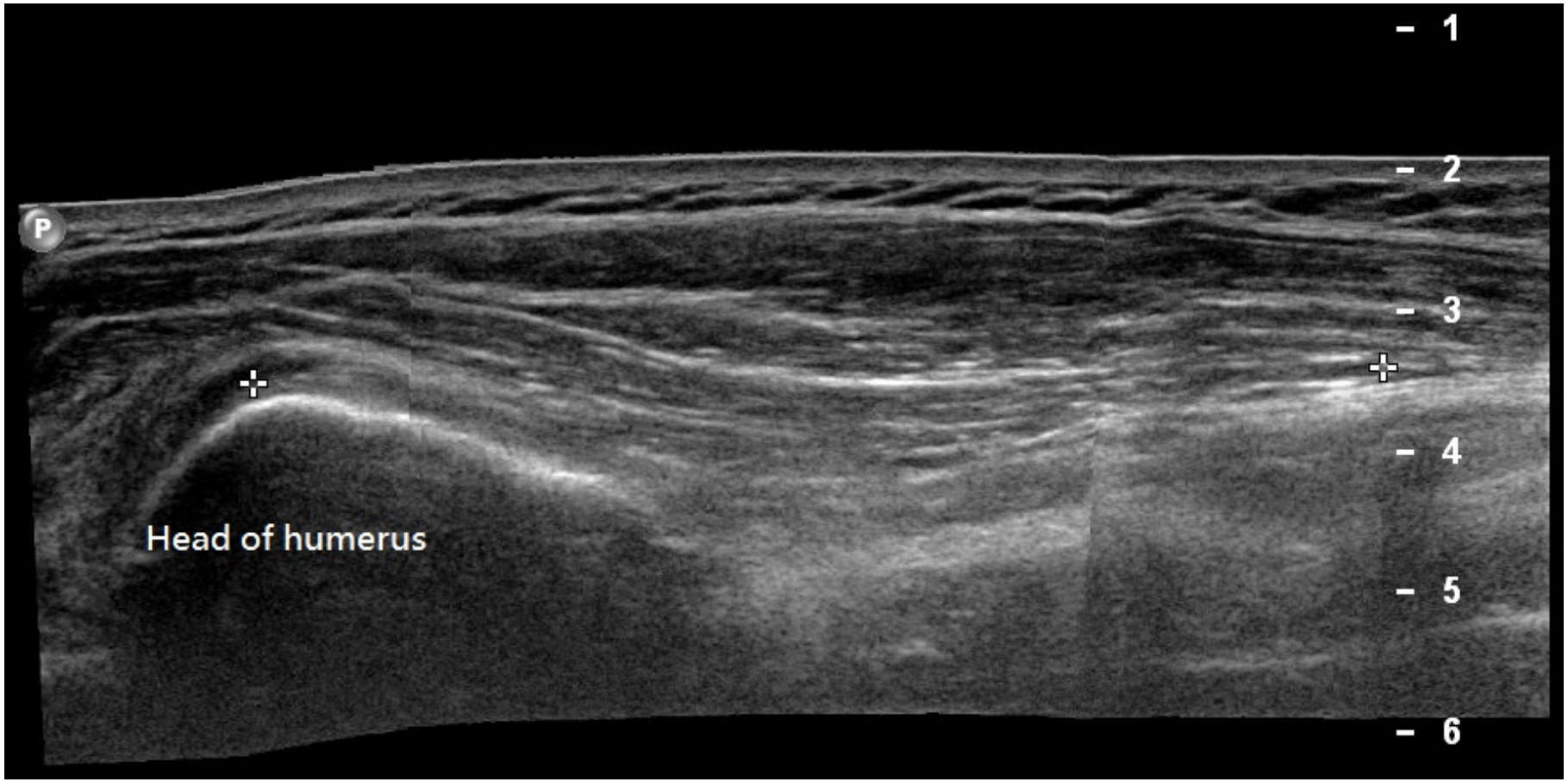

Figure 3

- Describe the ultrasound findings
  - Figure 1 showed the short axis view at the proximal bicipital groove, there was loss of normal biceps tendon (long head), the groove was filled with hypoechoic fluid instead
  - Figure 2 showed the short axis view at the distal biciptial groove, the biceps tendon had a heterogeneous echogenicity signifying some degree of tendon tear. There was also hypoechoic fluid collection around the tendon
  - Figure 3 showed the composite long axis view, there was partial tear of the bicep tendon with surrounding hypoechoic fluid collection

- What was the diagnosis?
  - Partial rupture of the long head of biceps
- What were the management options for the patient?
  - Conservative (treatment of choice of less physically demanding person)
  - Operative, (preferred in this case as the patient is an amateur athlete)