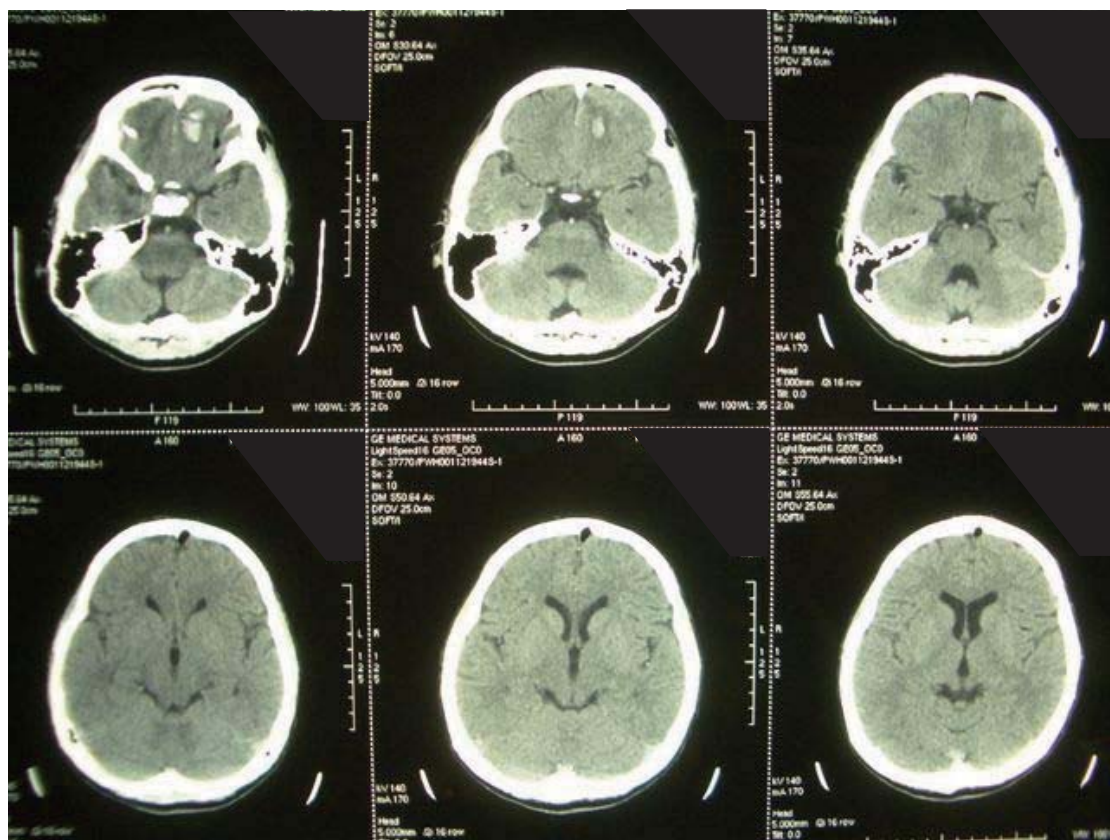
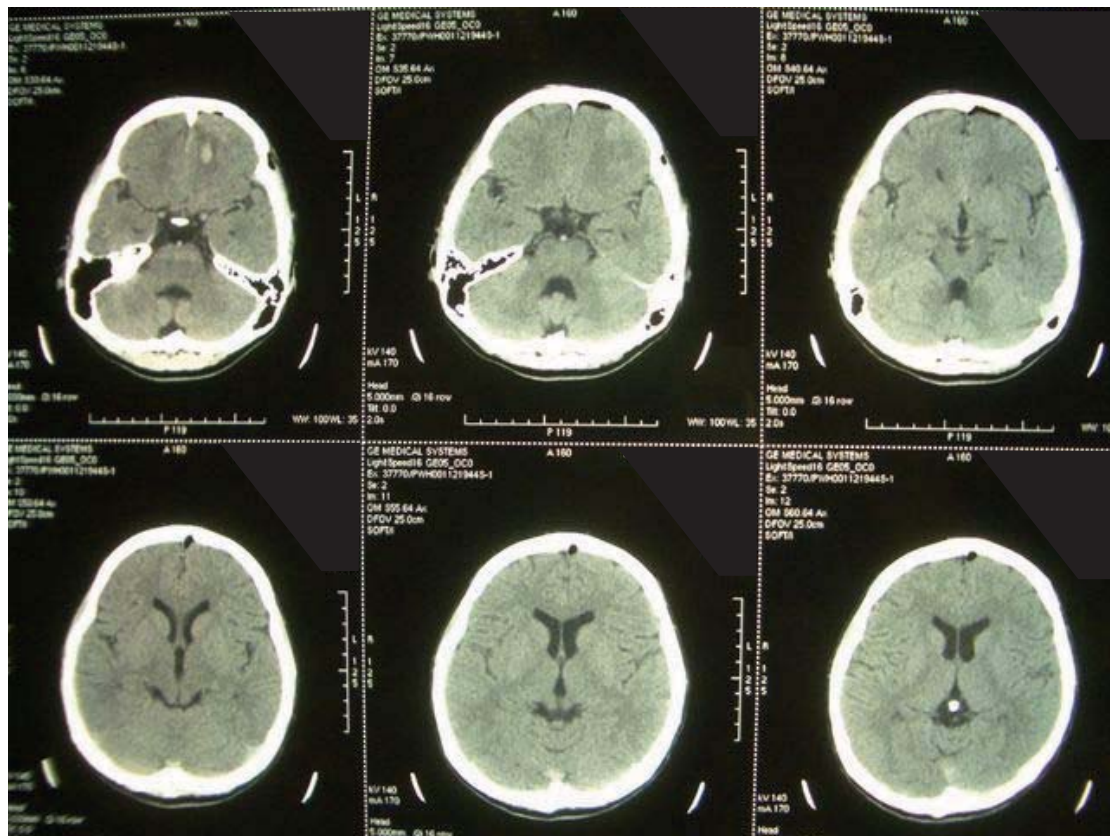


## Question 1



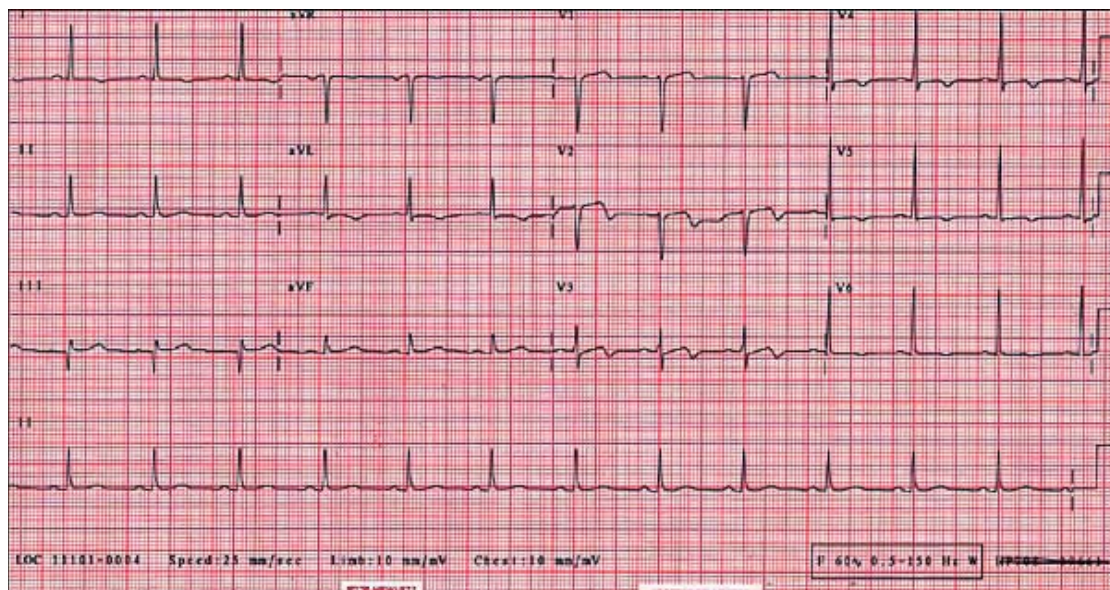
### **Question 1**

A 13 year-old boy sustained a head injury after a fall, LOC for 10 min

What are the CT abnormalities?

What is the treatment of choice?

### **Question 2**



### **Question 2**

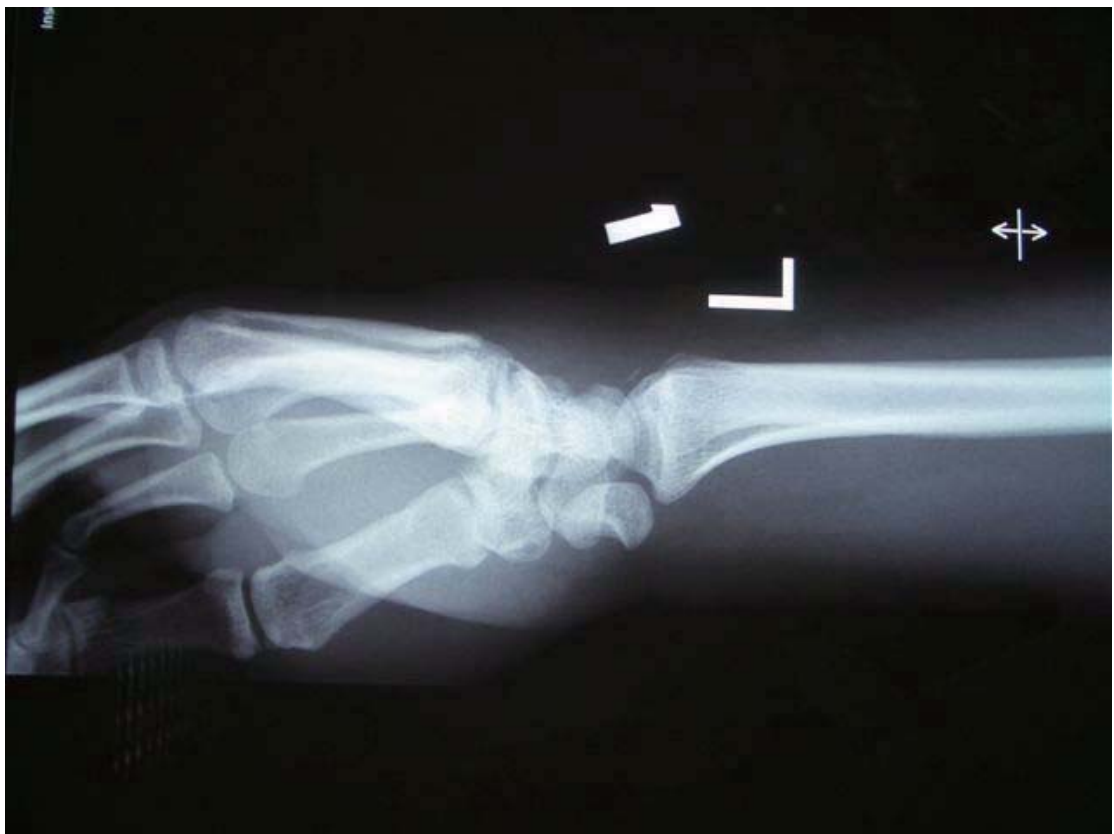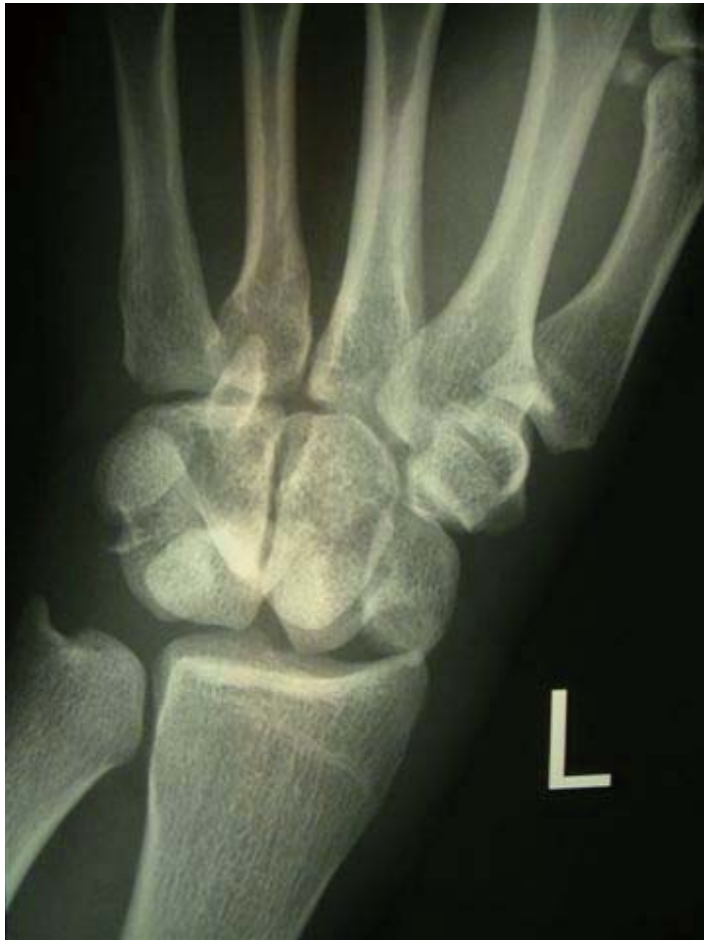38 year-old good past health Gentleman presented with sudden onset chest pain

What is the ECG finding?

What is the management plan?



Question 3



### **Question 3**

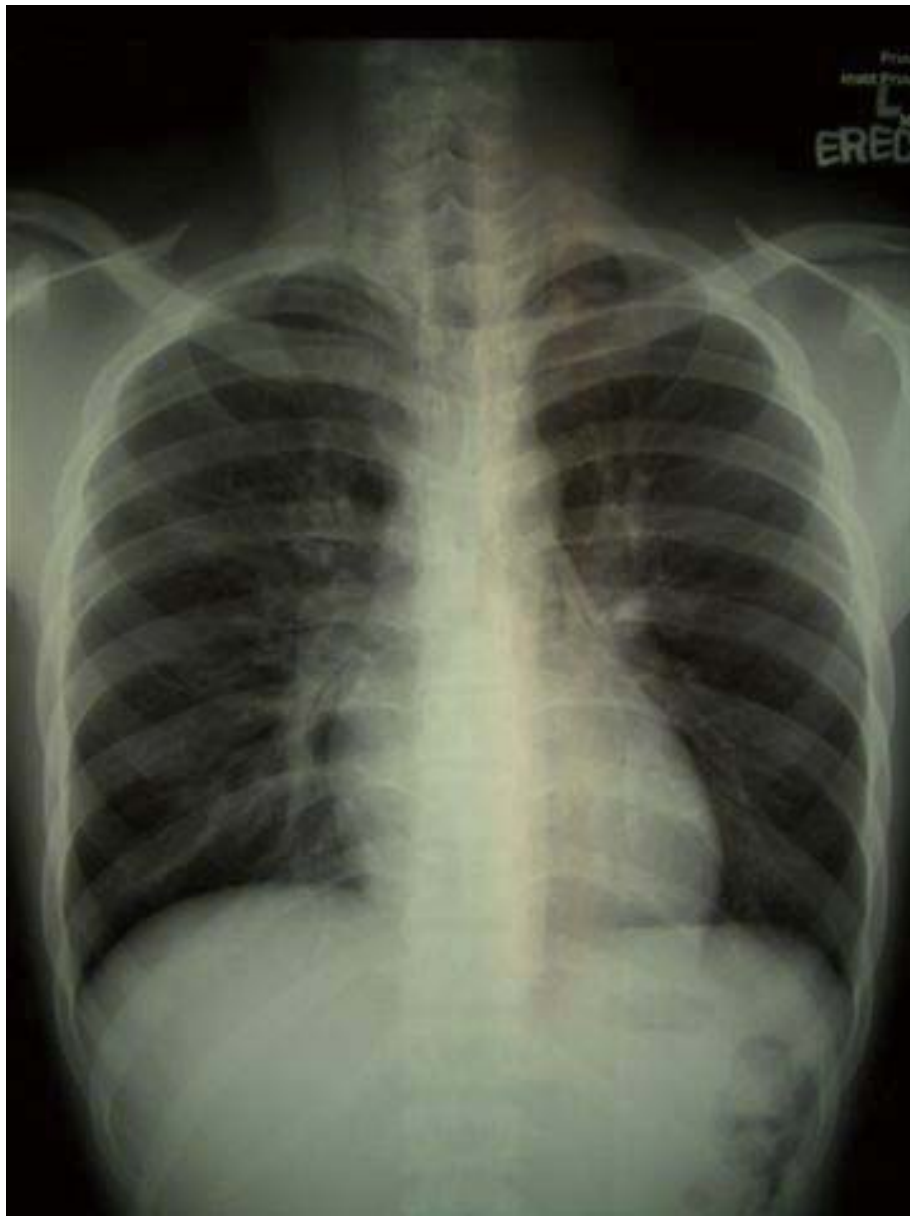28/M fell on level ground with wrist injury

Describe the x ray

What is the common associated injury?

What is the management plan?

### **Question 4**



#### **Question 4**

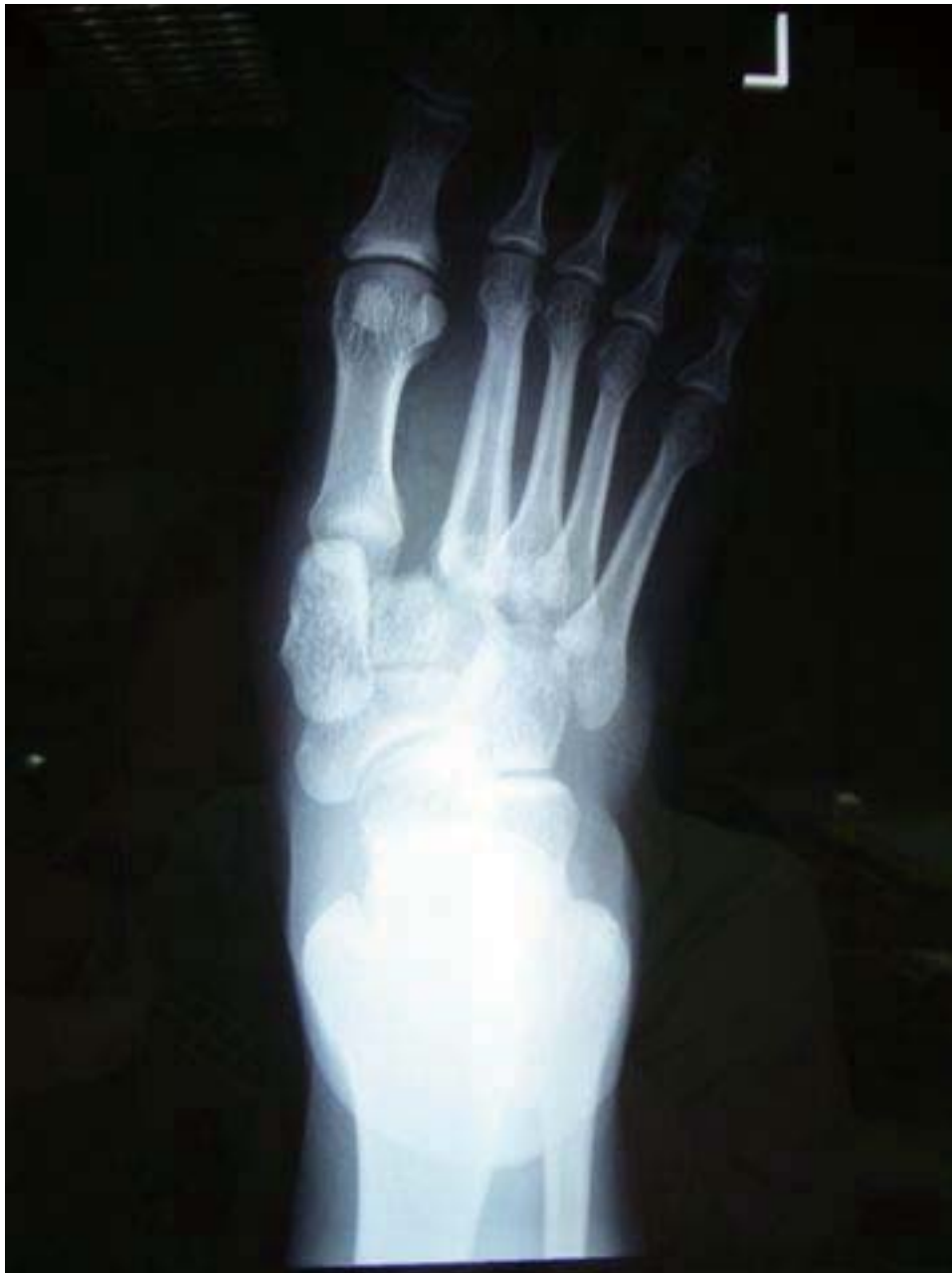25 year-old boy presented with chest pain for one day

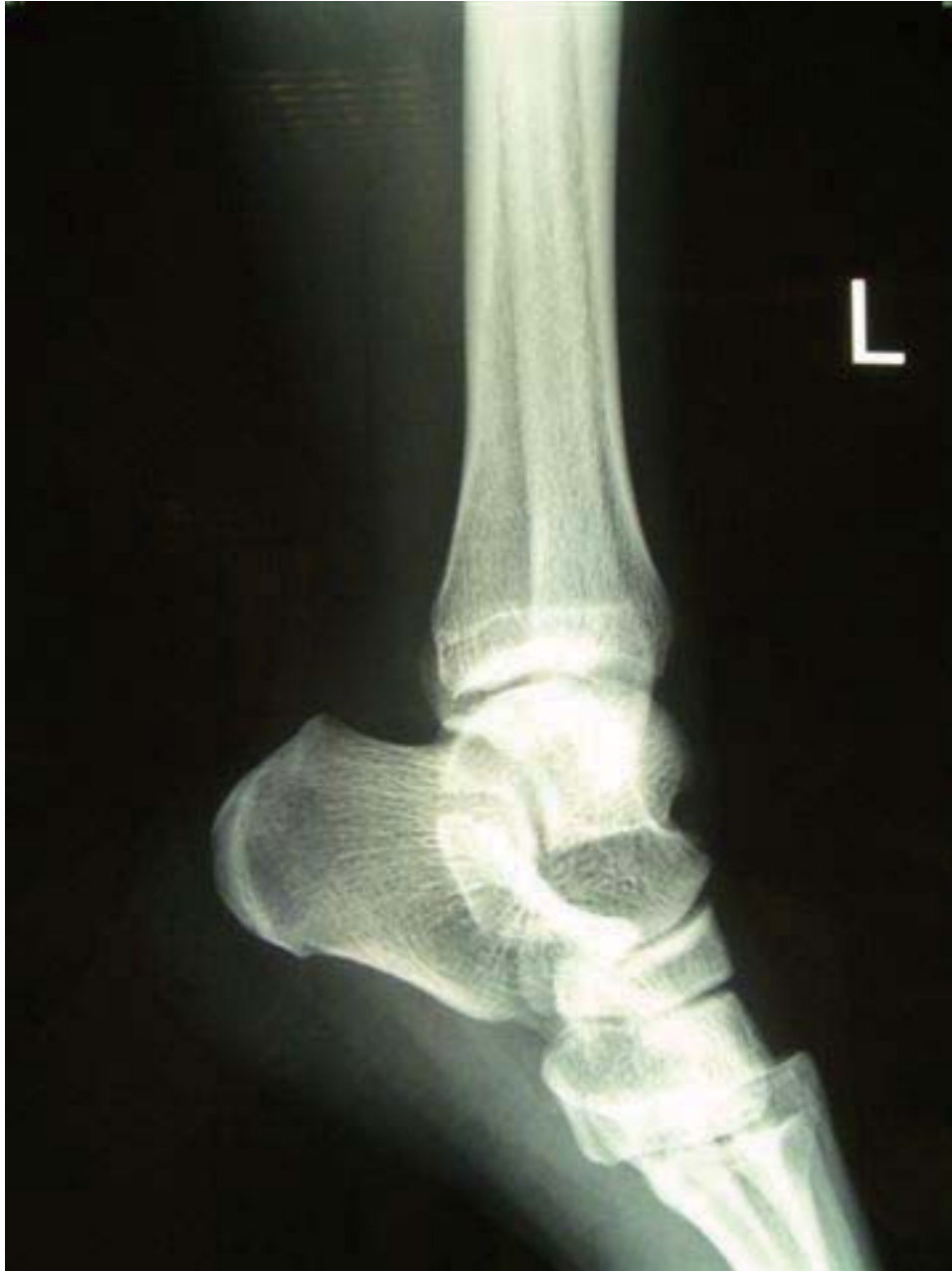What are the important points in the history?

What is the chest X ray finding

What is the treatment?

#### **Question 5**





**Question 5**

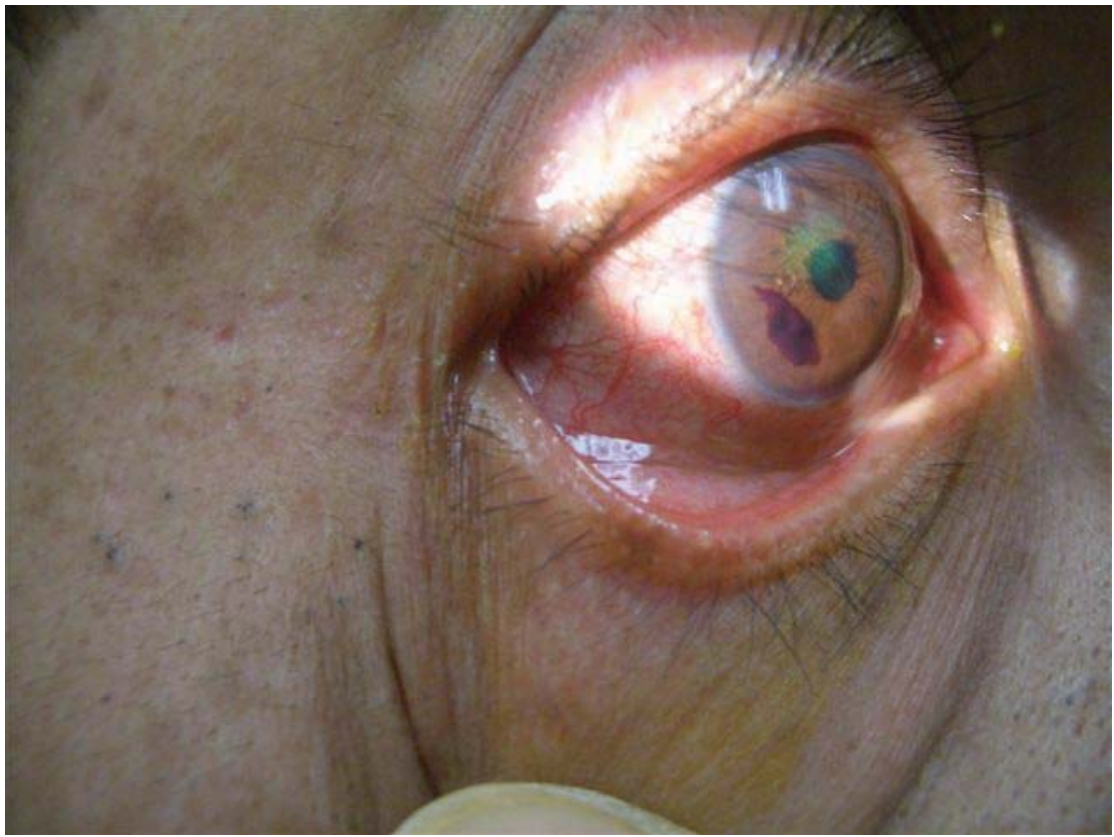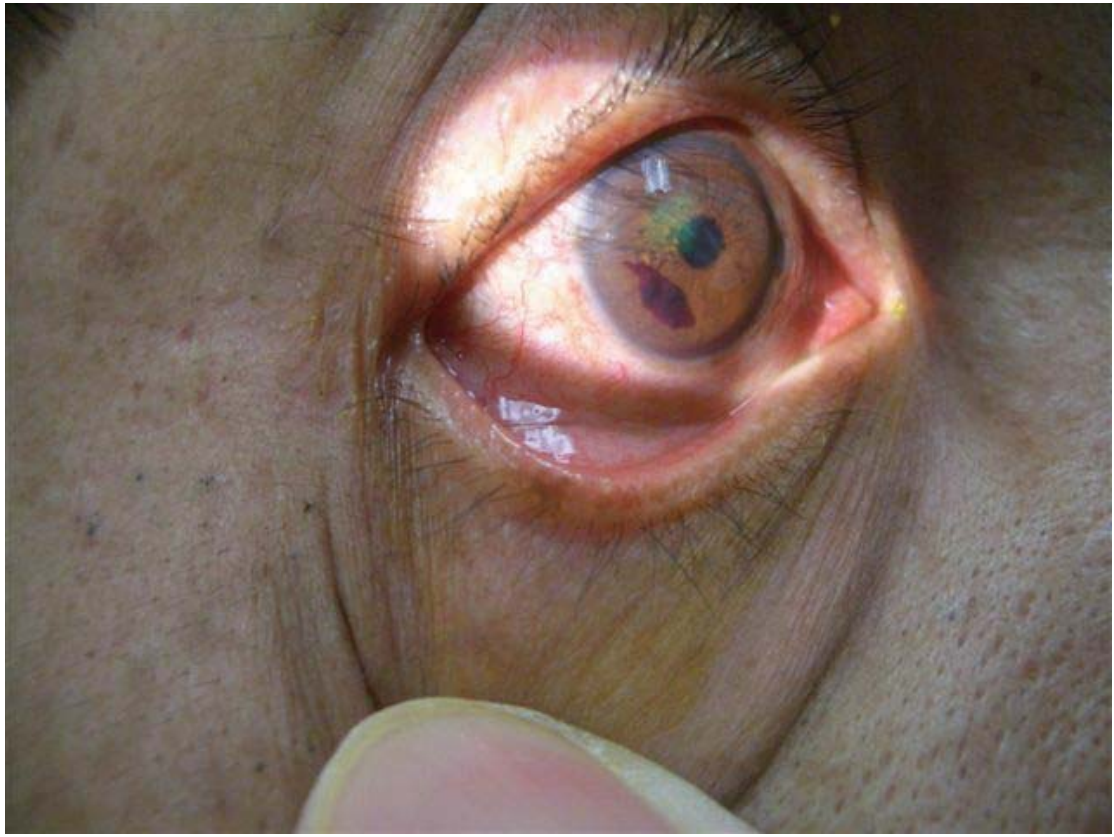37 male have ankle sprain

Describe the x ray

What is the name of the pathology?

What is the treatment?

**Question 6**



### **Question 6**

The picture shows the right eye of a constructional site worker

What is the abnormality?

What further investigation you would order

What is the treatment?