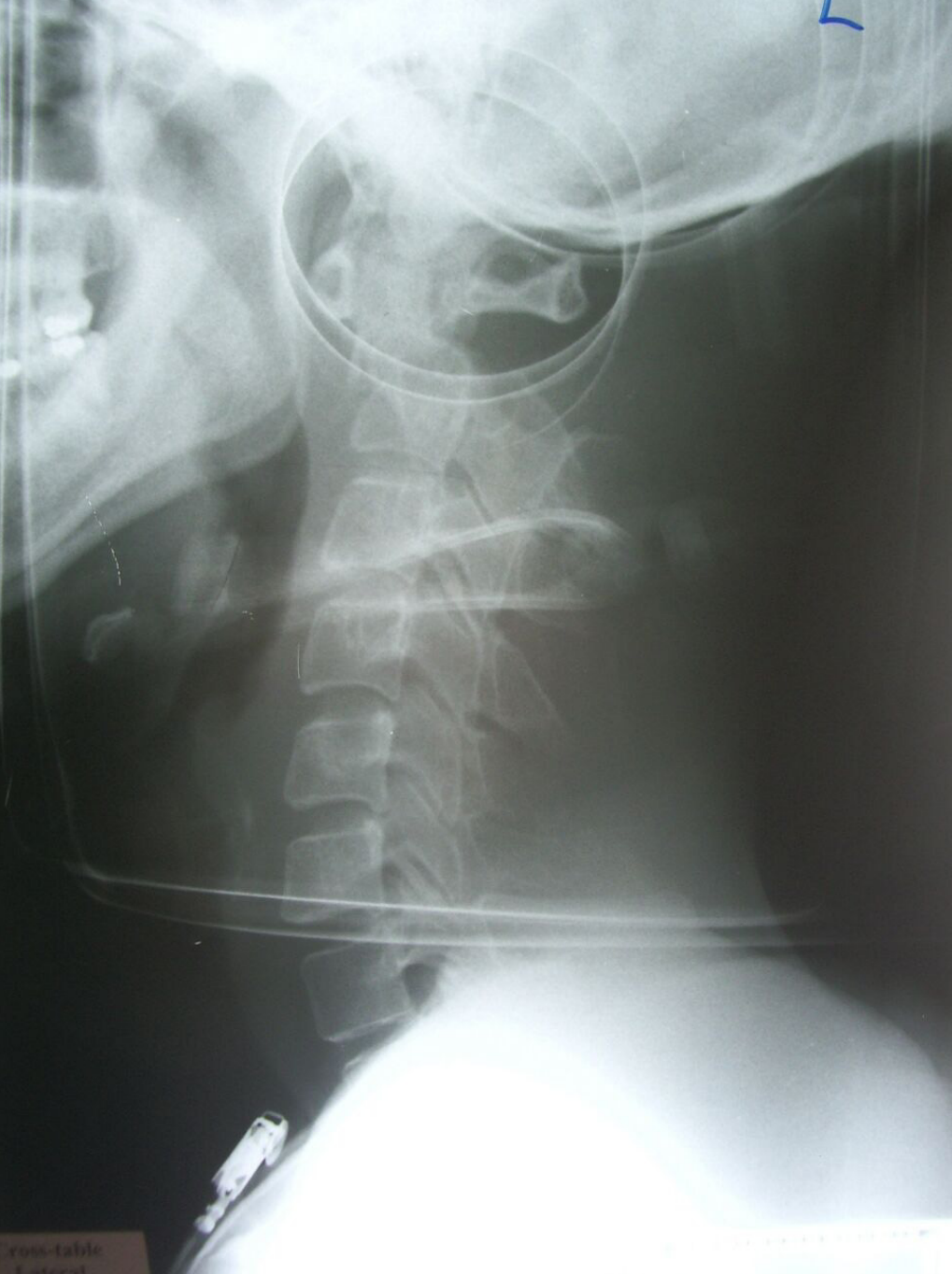

OSCE

Questions

6 June, 2007

AED, PMH



Question 1

M/32

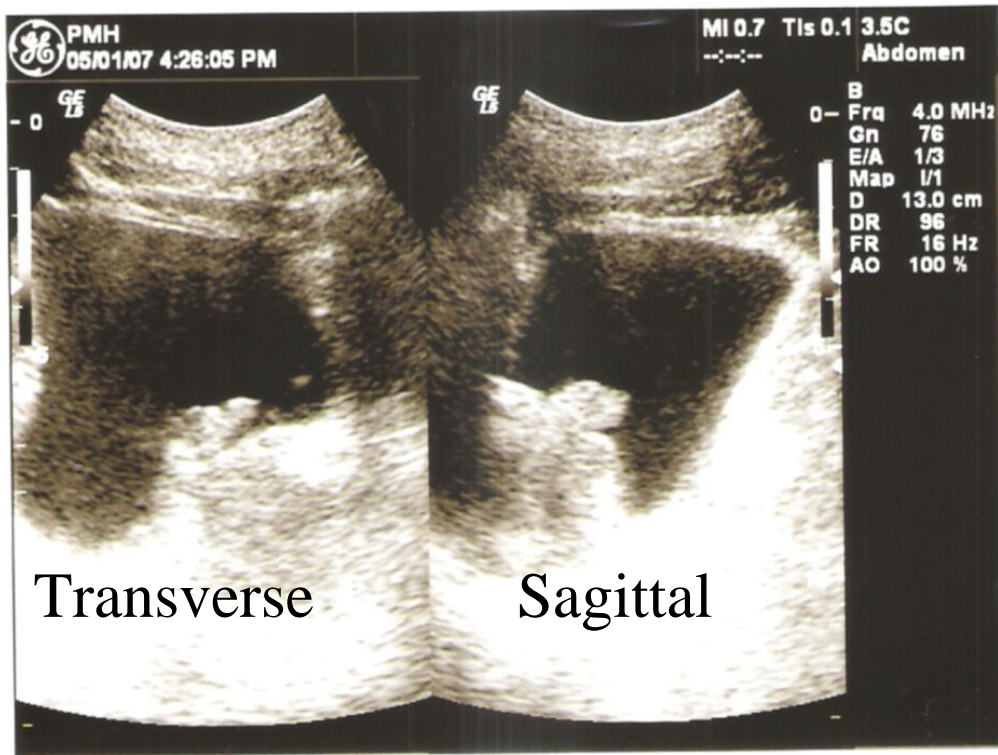
Truck driver in traffic
accident

C/O: Neck pain

X-ray cervical spine

Question 1

- a. What is your diagnosis?
- b. What are the two immediate emergencies that may happen?
- c. Describe the classification of this problem.



Question 2

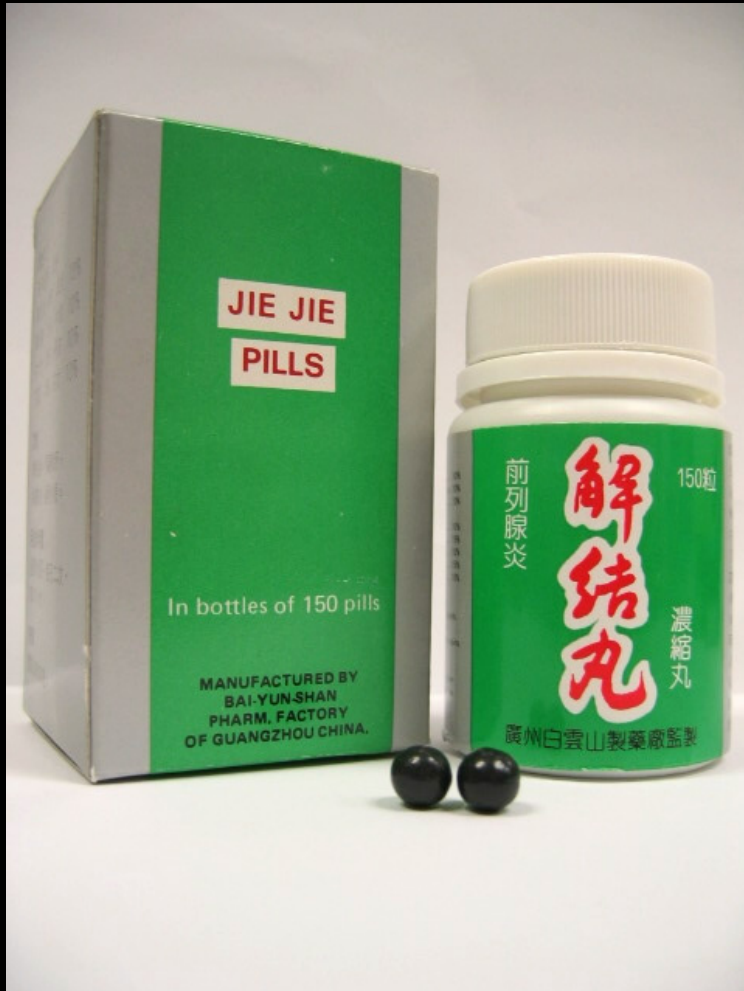45 years old man
with painless gross
haematuria for 1
month. P/E: afebrile

USG of kidneys:
normal

USG of urinary
bladder is shown.

Question 2

- a. Give two possibilities which may account for the ultrasonographic abnormality. (Put the more likely one as your first answer)
- b. How can you differentiate the two differentials?
- c. Give 4 information in the history that is important.



Question 2

It was found that the patient was taking herbal tablets (Jie Jie Pills) for several years.

d. What ingredient in the herbal tablet may cause his problem?

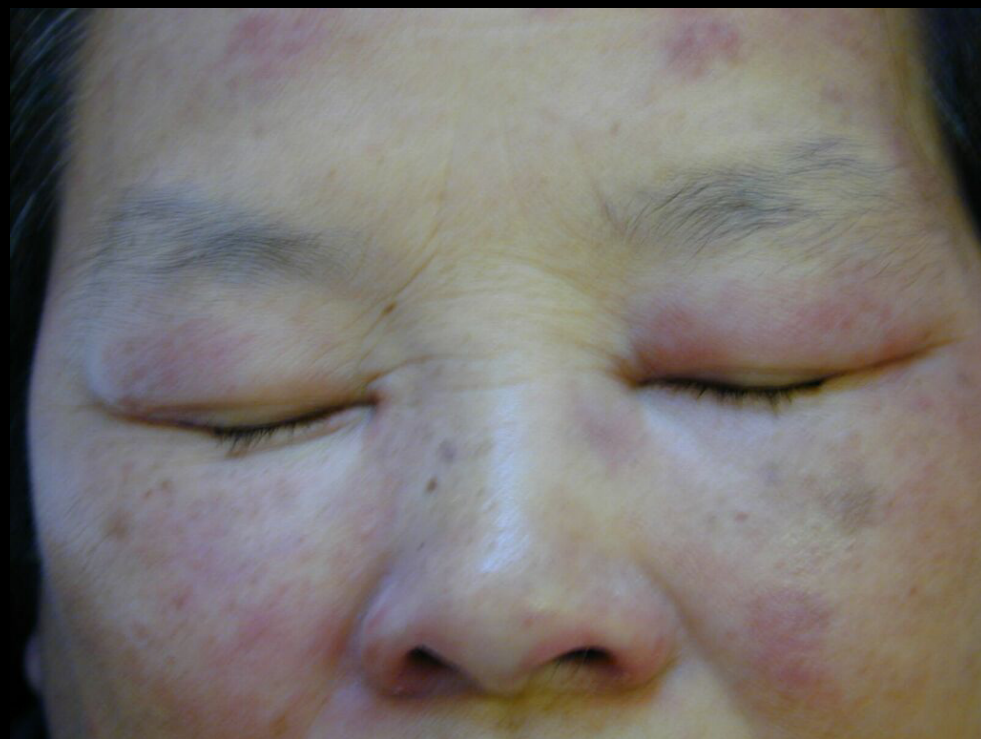Question 3

F/48

Attended A&E skin rash
malaise and difficult to
climb upstairs in recent
one month.

P/E: afebrile, GCS: 15

Normal BP/P



Question 3

- a. What is the physical sign?
- b. What two other physical signs would you look for ?
- c. Give two investigations you would perform in A&E for this patient

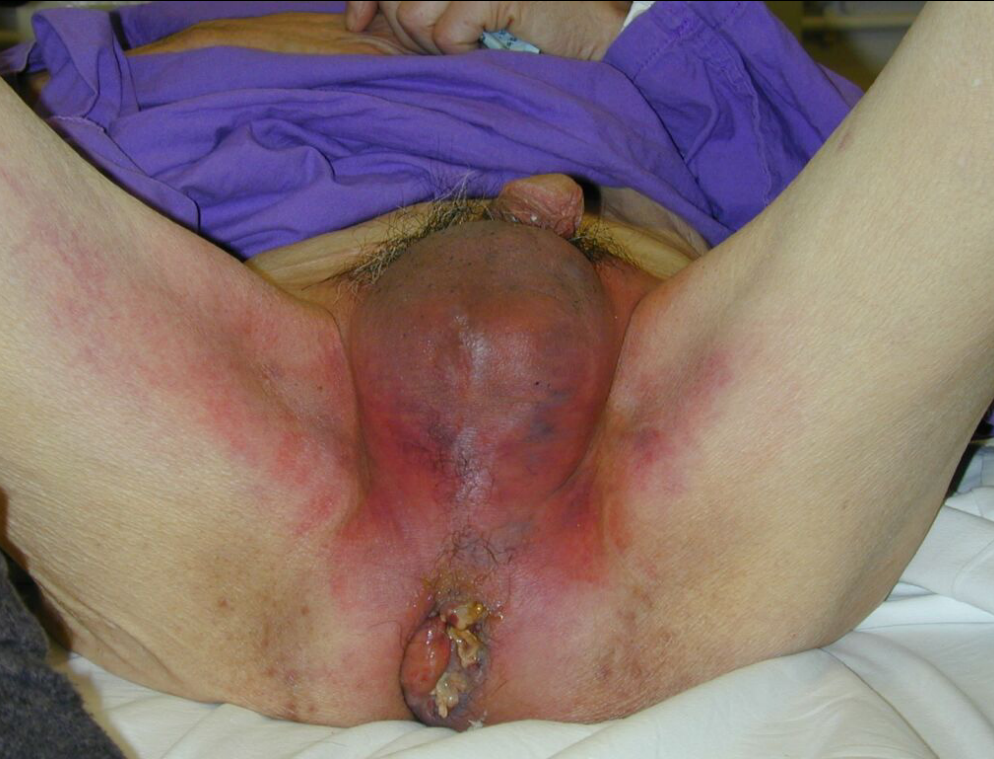Question 4

M/70, Chronic
drinker

Known case of Type
II diabetes mellitus

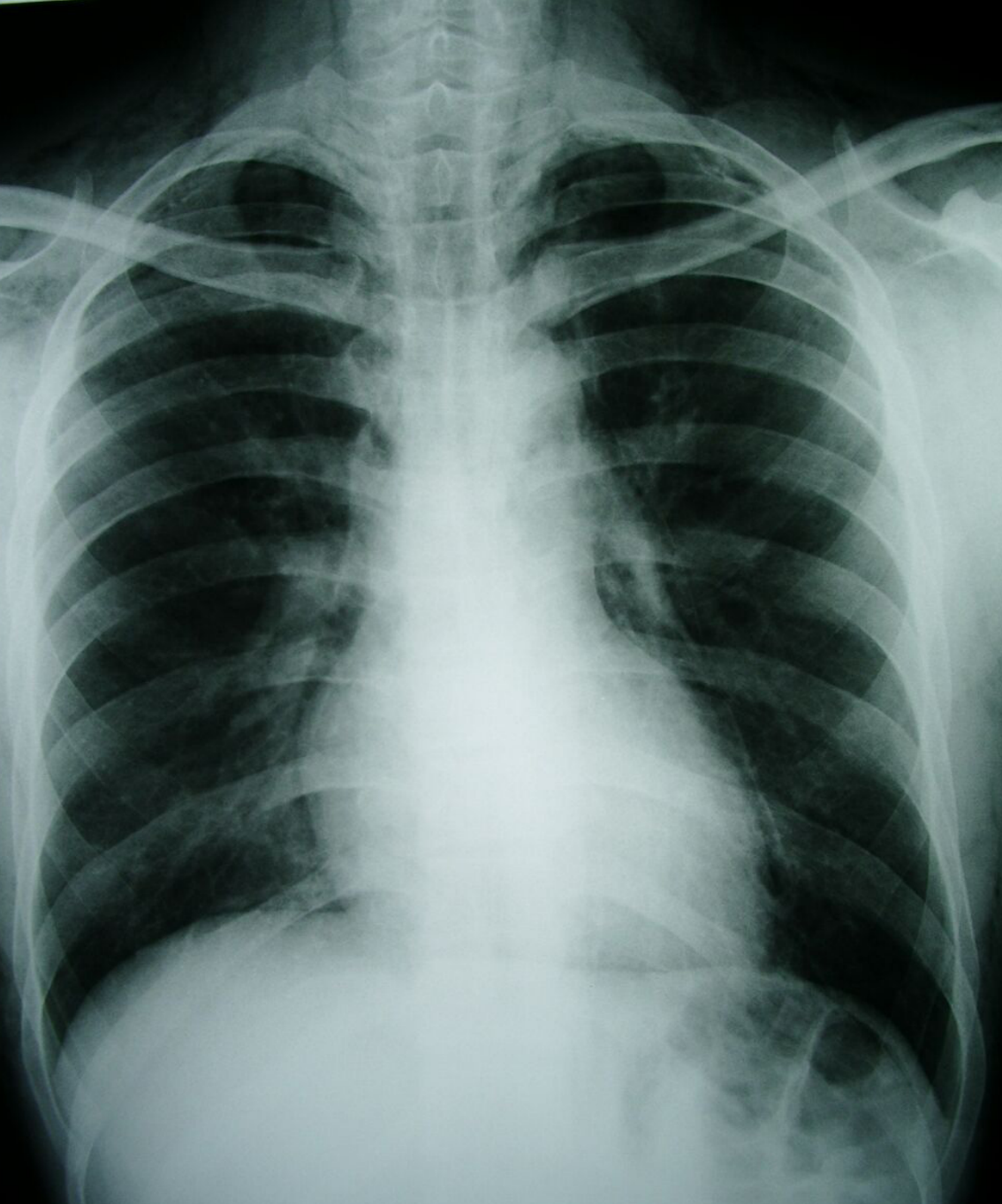
Attended AED
because of groin pain,
swelling, chills for 3
days.

P/E: 38°C, P:120/min,
BP: 110/50.



Question 4

- a. What is your diagnosis?
- b. Name 4 most common pathogens for this problem.
- c. Give 3 treatment in order of priority.



Question 5

M/25

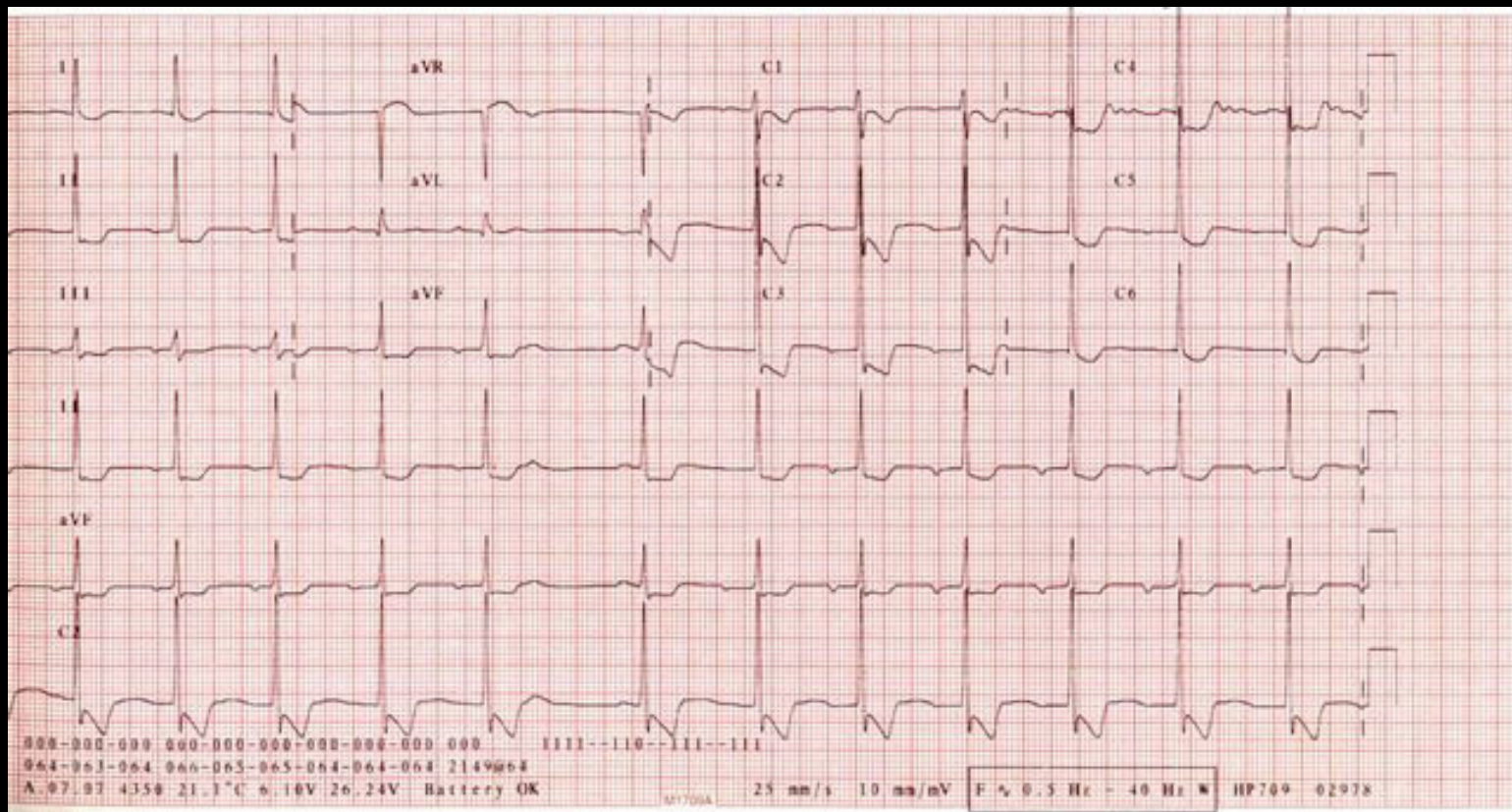
Complain of
Neck pain and
retrosternal
pain on
swallowing
after Karaoke

P/E: afebrile.

Normal vital
signs

Question 5

- a. Give two radiological abnormalities
- b. Name two physical signs that may be present
- c. Give 4 risk factors for such problem



Question 6

M/72

Attempt suicide by taking 60 tabs of his wife's medication who has chronic rheumatic heart disease

Question 6

- a. Give 3 ECG abnormalities
- b. What drug has been taken?
- c. Give 4 indications for antidote.