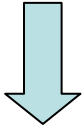


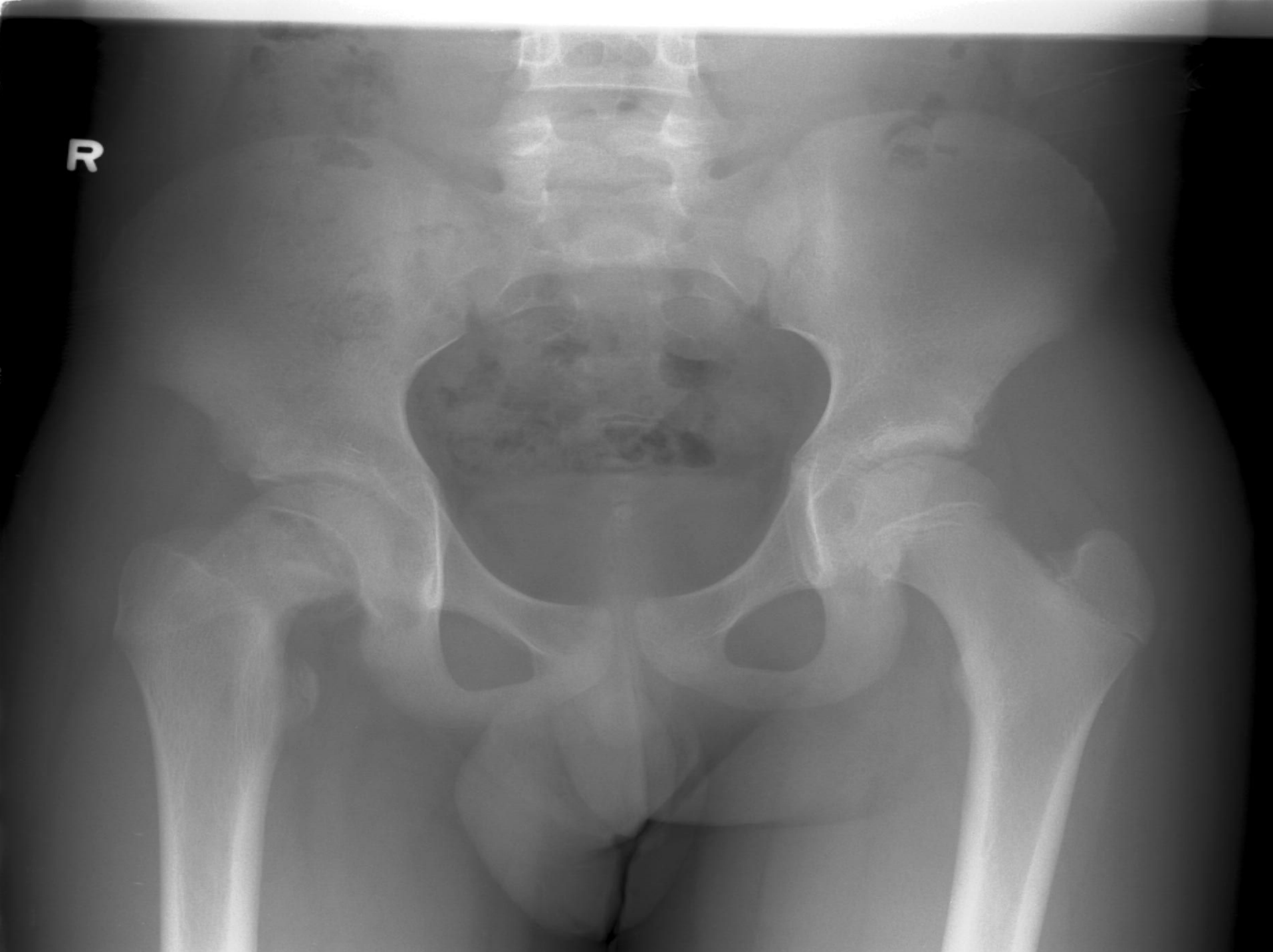# JCM OSCE July 2007

North District Hospital

# Case 1

- 14 yr old girl
- right hip pain x 2/52
- no hx of trauma
- Exam:
  - afebrile
  - tenderness over R hip
  - R hip ROM 
  - cannot bear weight on RLL

R

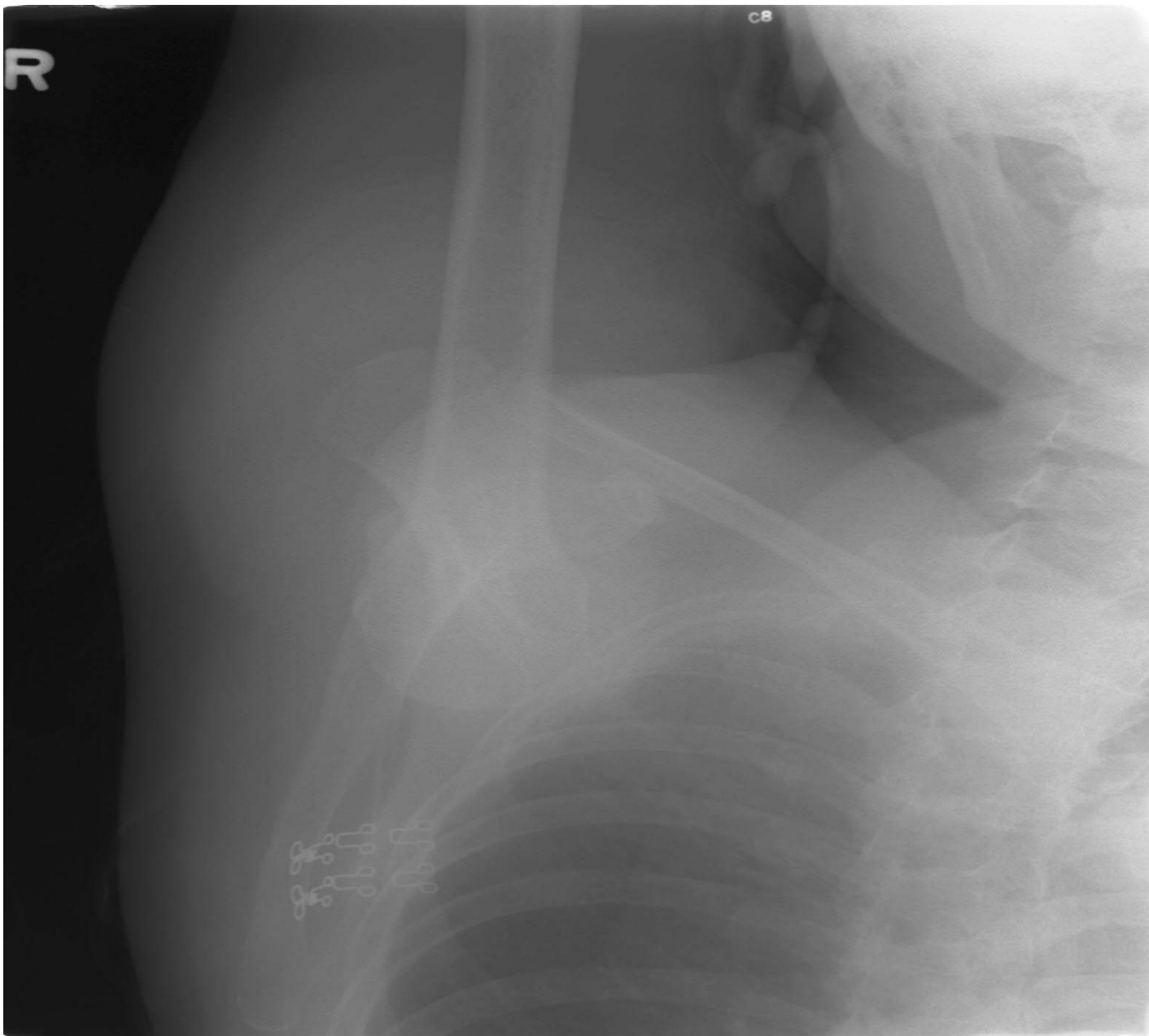


# Questions (1)

- a) What are the possible Dx / DDx?
- b) Which X-ray views would you order to detect this abn, esp in the early stage?
- c) What radiological signs may establish your Dx?

# Case 2

- 66 yr old lady
- S/F in the afternoon on level ground
- Exact MOI not known
- c/o R shoulder severe pain & unable to move
- R shoulder held in abducted position and cannot put it down because of pain +++



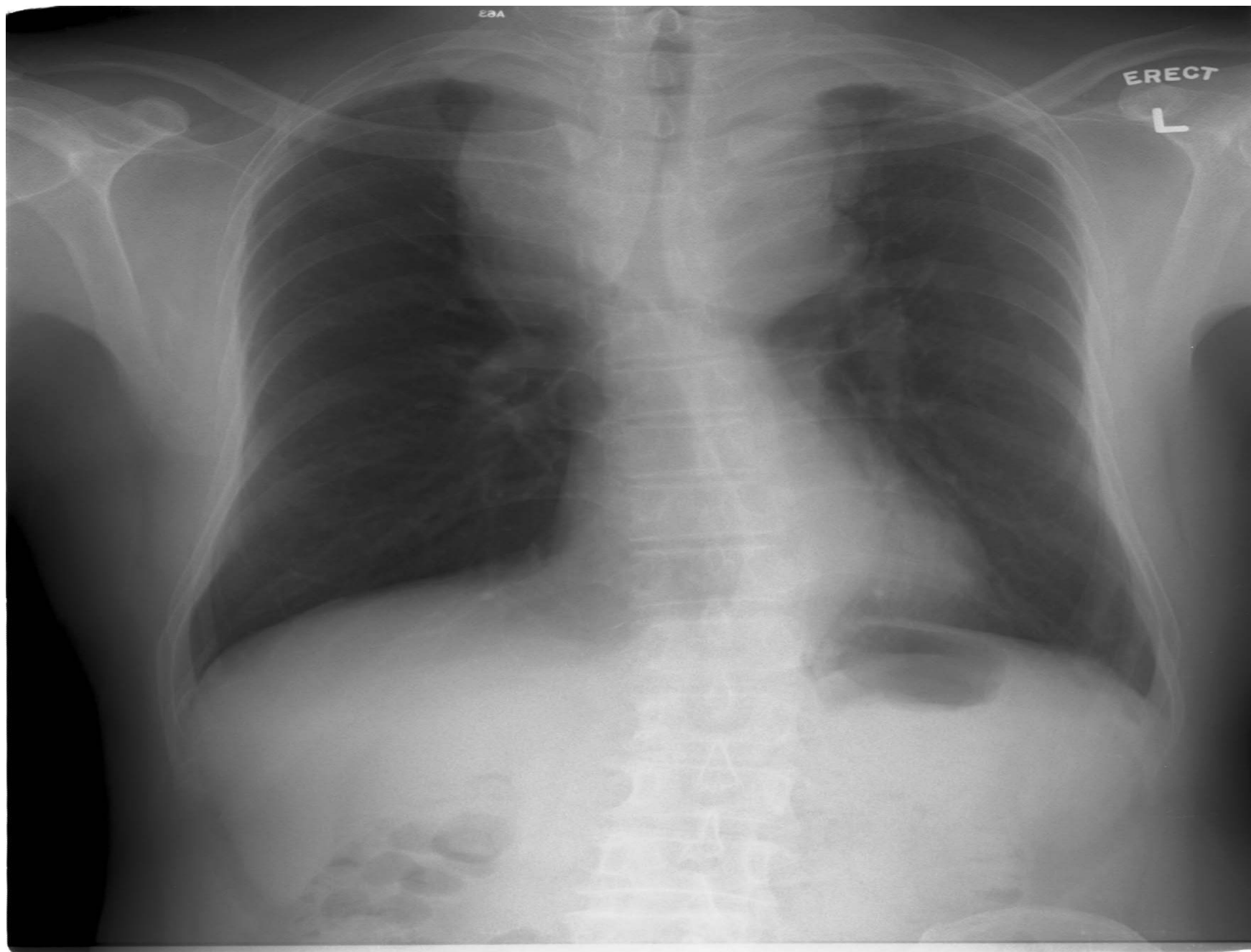# Questions (2)

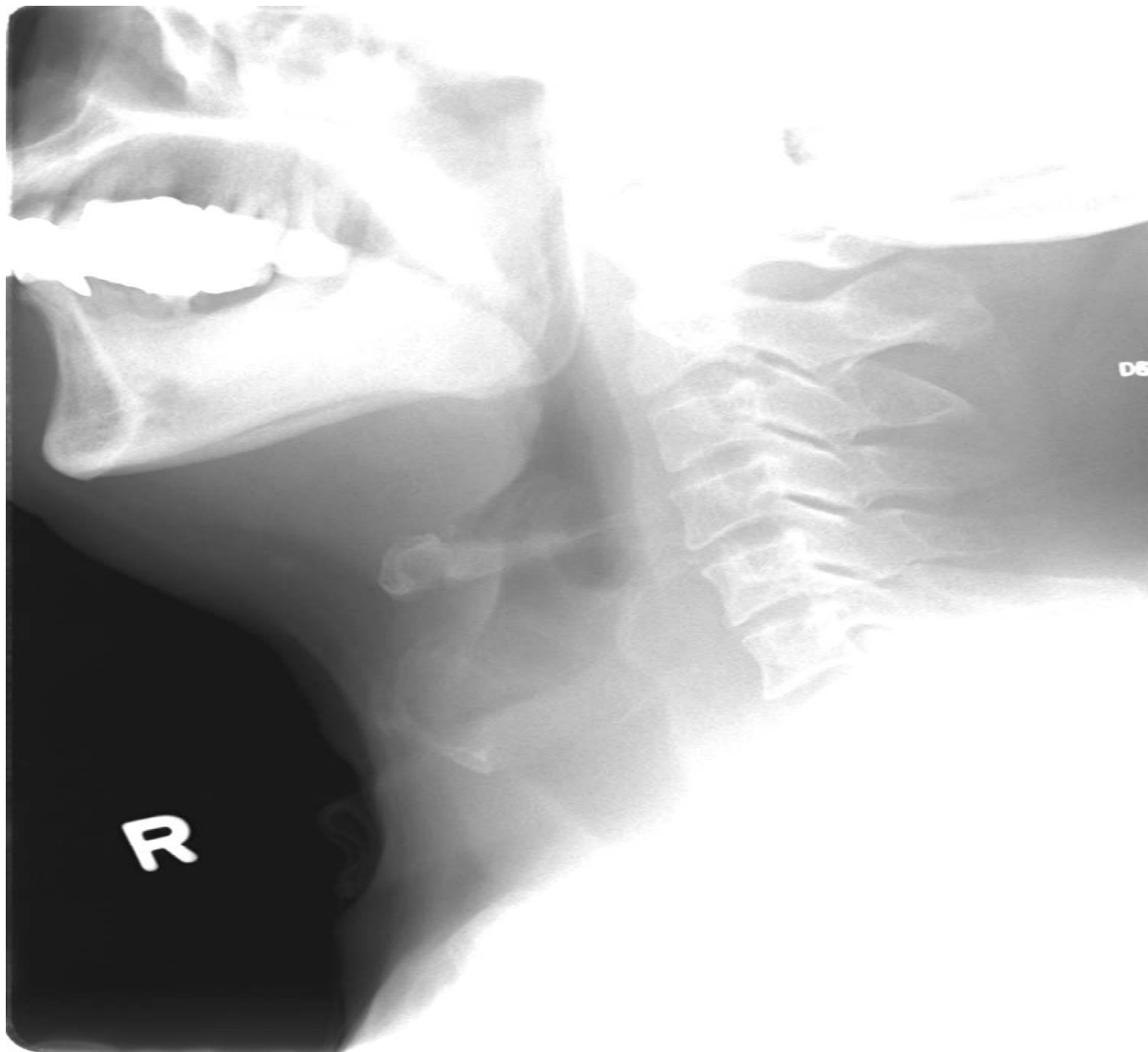
- a) What is your diagnosis?
- b) Can you propose the possible mechanism of injury?
- c) How are you going to treat this condition?

# Case 3

- M/66
- Hx of thyroid problem, no FU, no OT done
- Complained of difficulty in breath for yrs
- Increased SOB on level ground x 2 days
- No chest pain/fever/cough
- Vital stable, SpO2 RA 98%





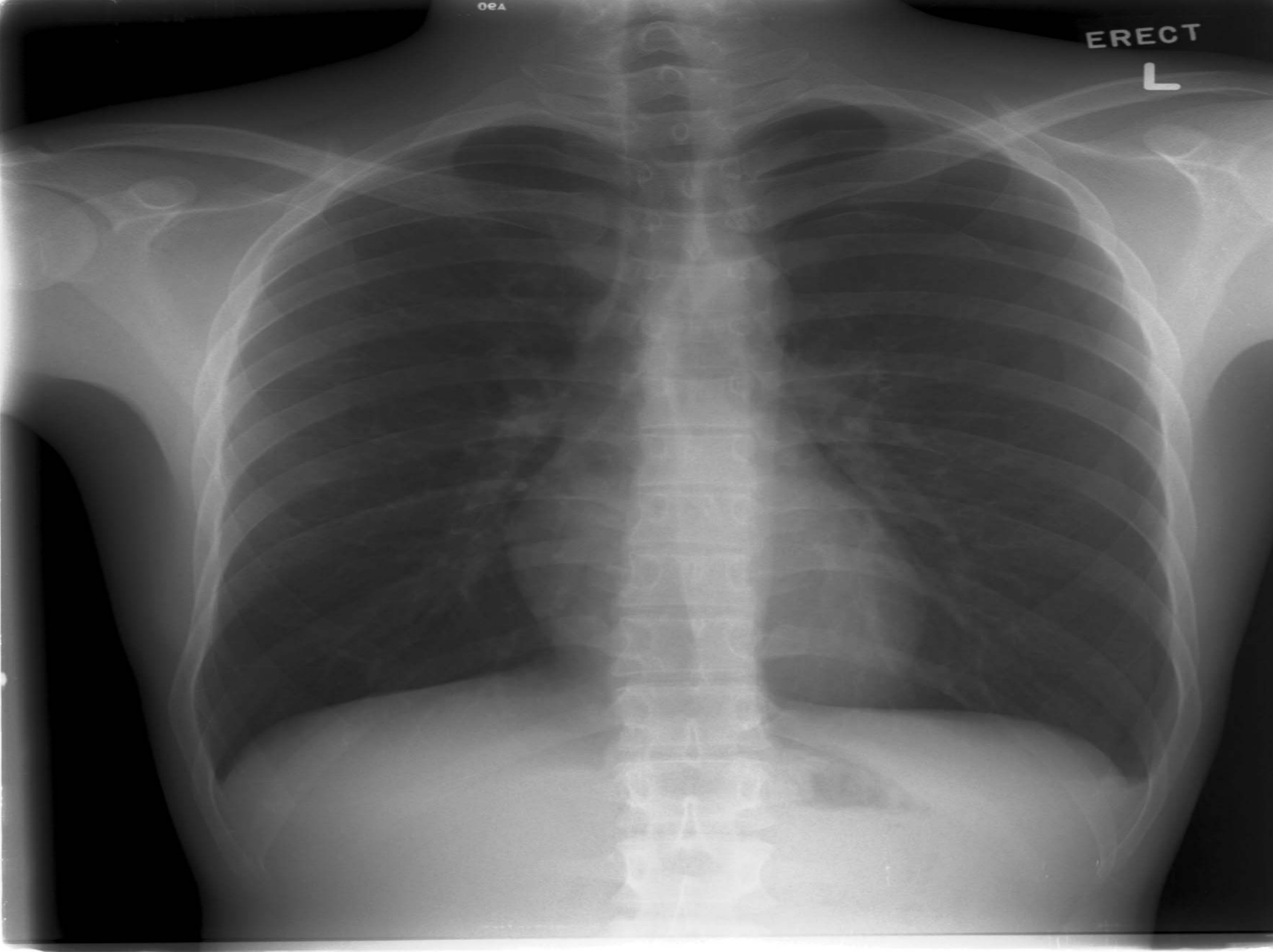

# Questions (3)

- a) What is your diagnose and differential diagnosis?
- b) What other clinical **sign** you want to elicit to show the complication of this enlarged structure?
- c) How will you manage this patient?

# Case 4

- This is the CXR of a patient with L Pneumothorax.
- How do you estimate the extent of the pneumothorax?



ERECT

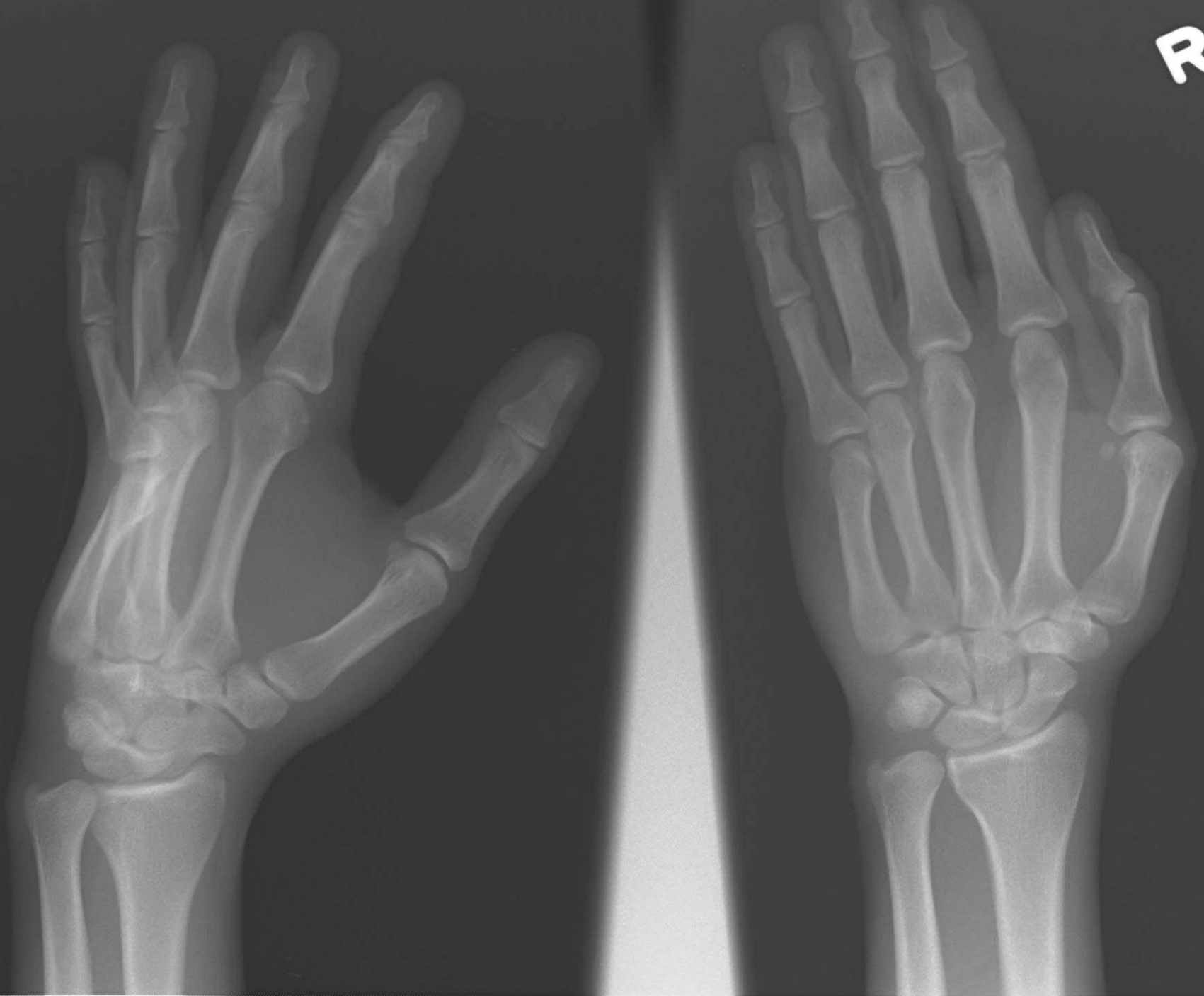
L

# Case 5

- M/21
- Claimed S/F accidentally
- Landed on dorsiflexed right hand

c1e

R



# Questions (5)

a) What is your diagnosis?

b) How are you going to manage this patient?