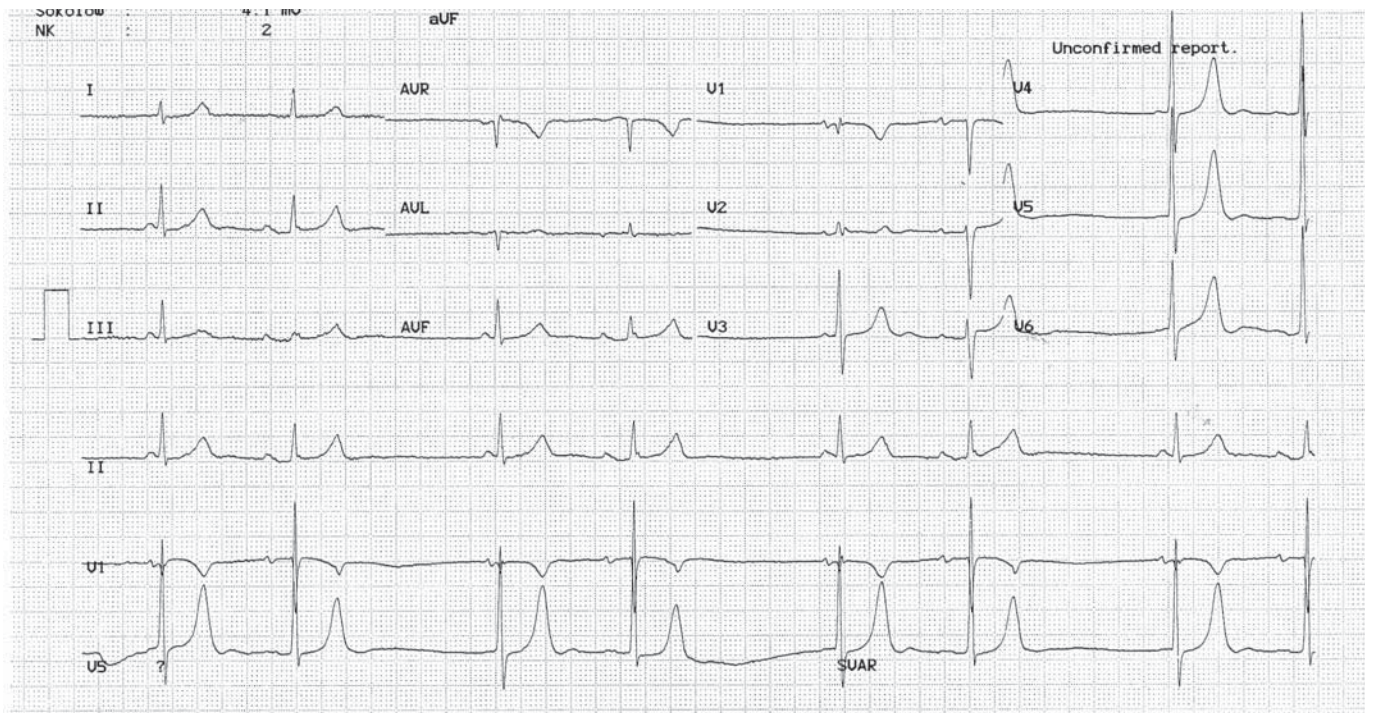


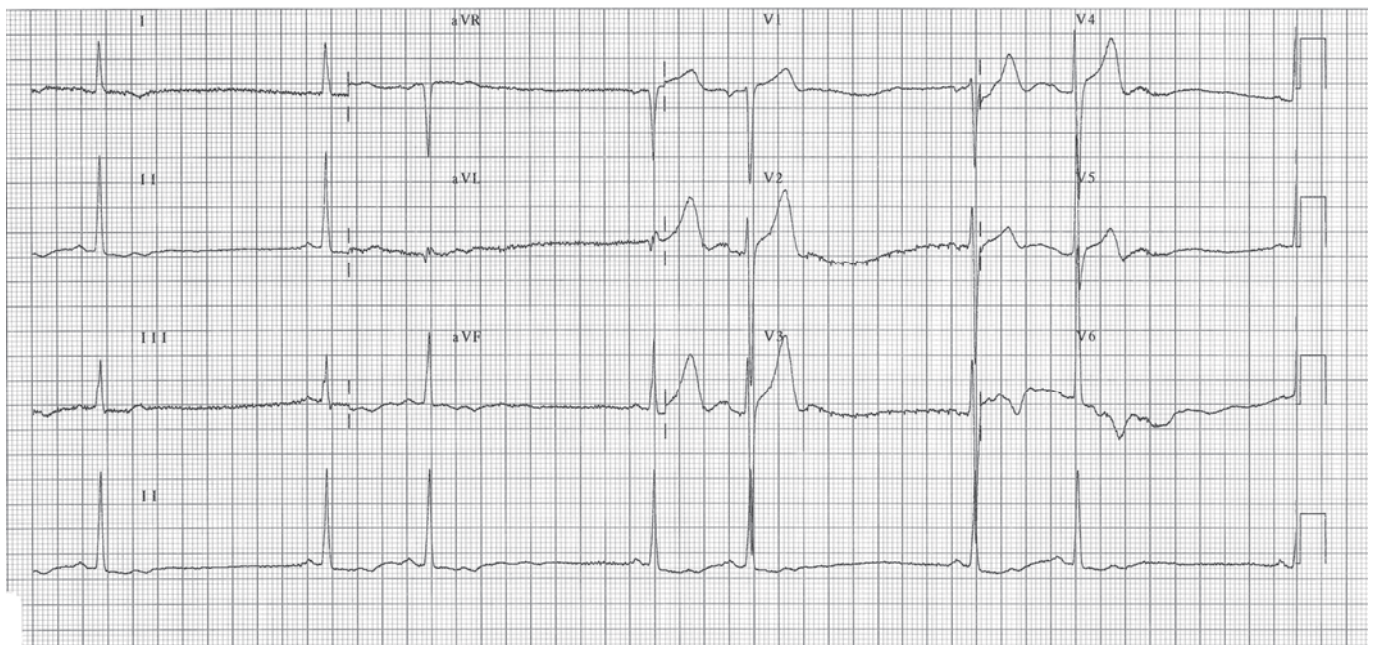
September 2007



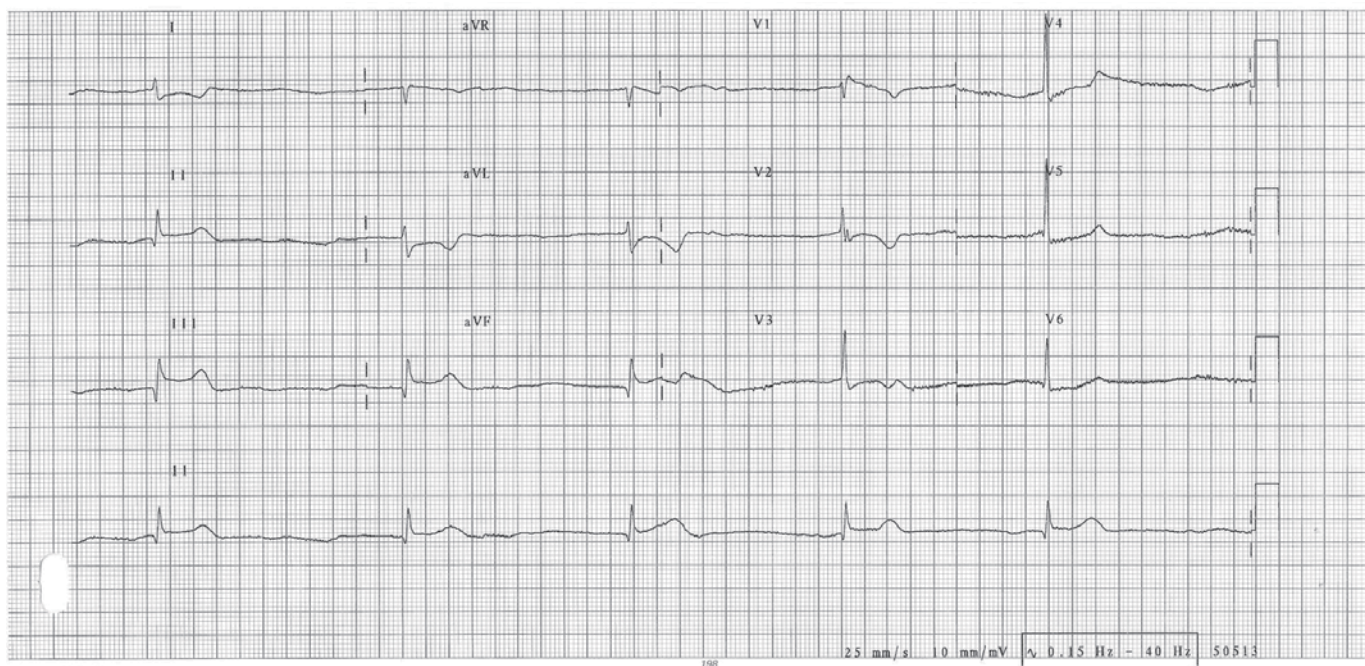
OSCE



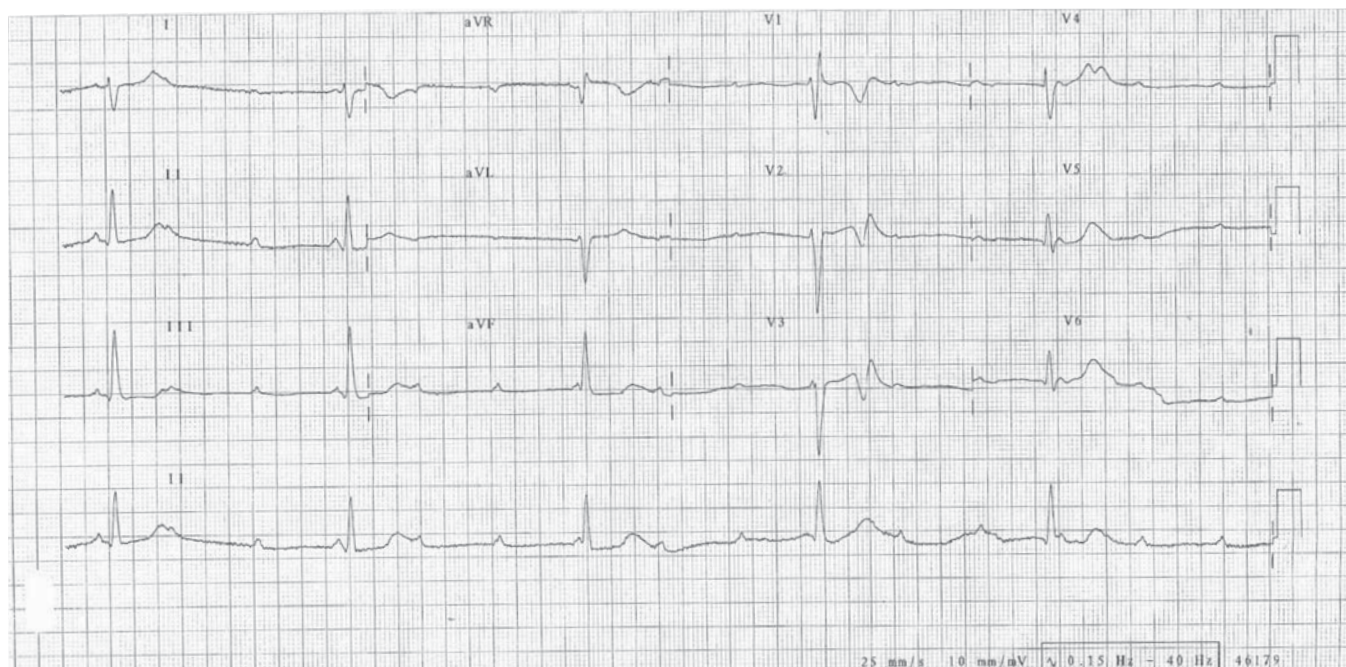
1a	ECG findings	
	Diagnosis	



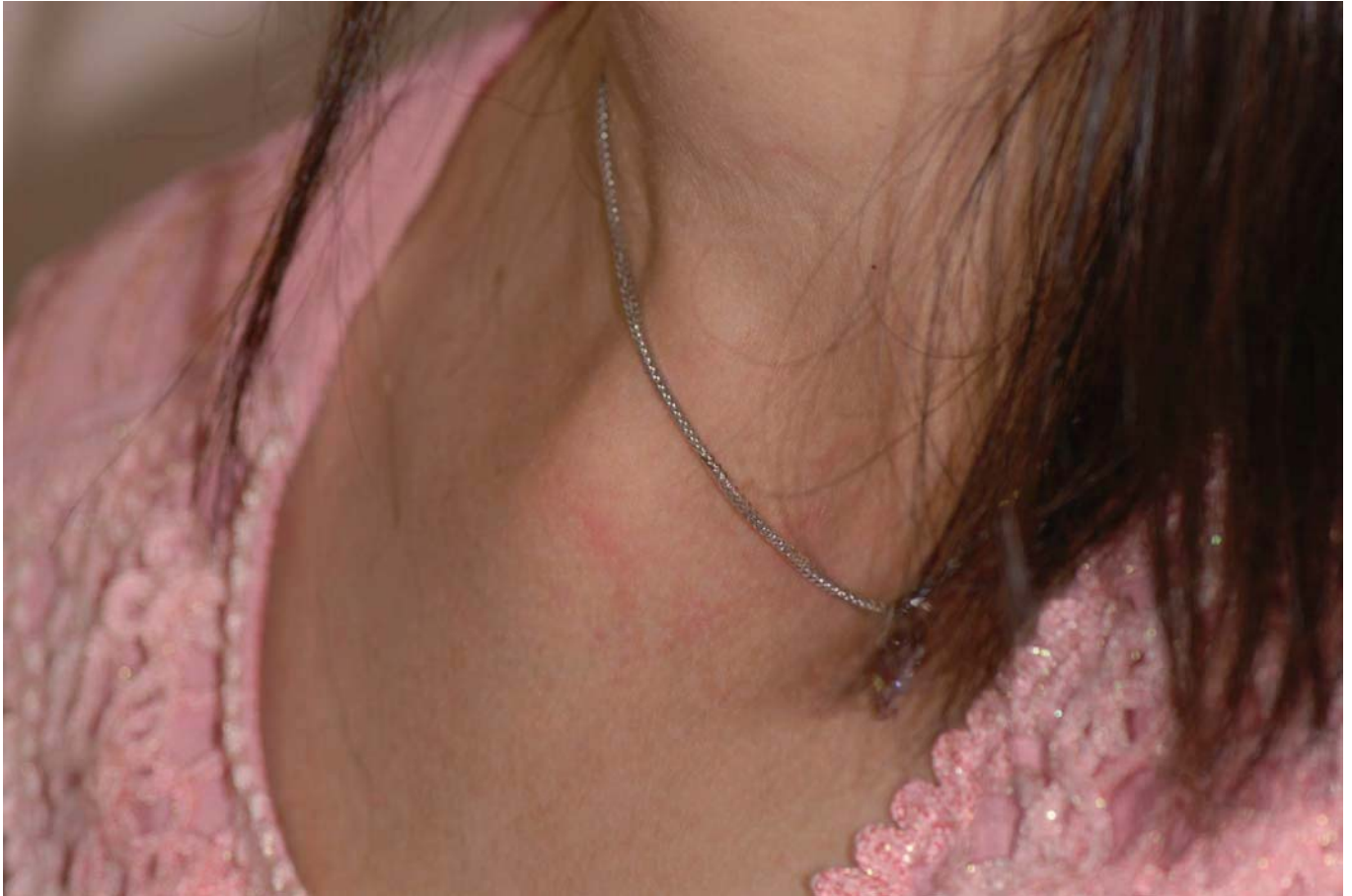1b	ECG findings	
	Diagnosis	



1c	ECG findings	
	Diagnosis	



1d	ECG findings	
	Diagnosis	



2

A 40-year-old lady presented as painful swelling over right sternoclavicular joint for 2 days. No history of trauma.

- a. What is the diagnosis?
- b. How to differentiate this condition from costochondritis?
- c. What is the underlying cause?
- d. Any other conditions can present like this?
- e. What is the treatment?

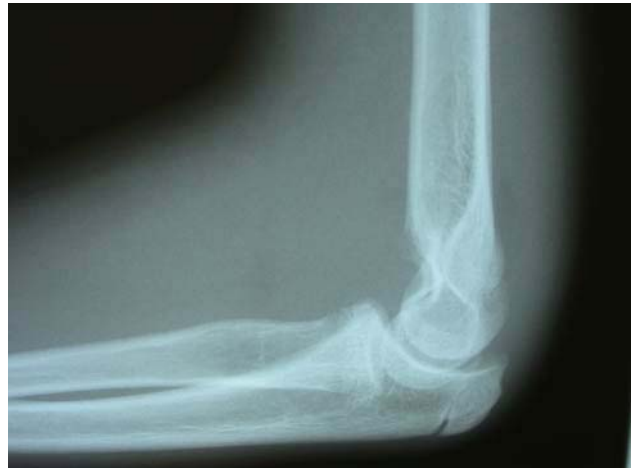
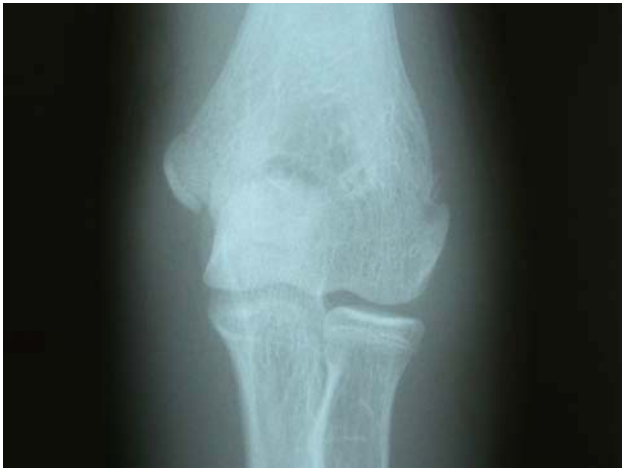
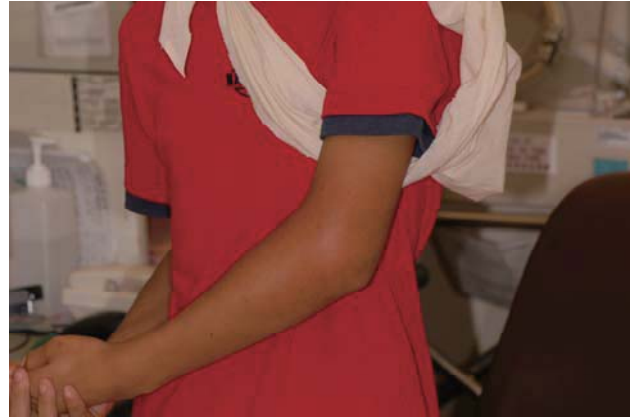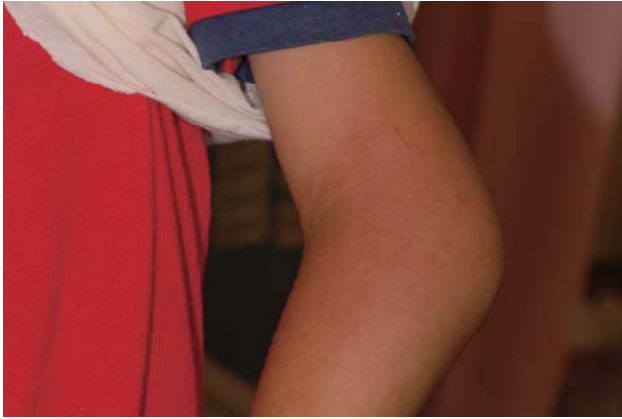3

A 35-year-old worker complained of generalized weakness & sweating after using insecticide spray to kill flea over body.

- a. What do you suspect?
- b. List other likely clinical features.
- c. Any precautions in approaching this patient?
- d. Any specific investigation to confirm the diagnosis?
- e. Name the specific antidotes.

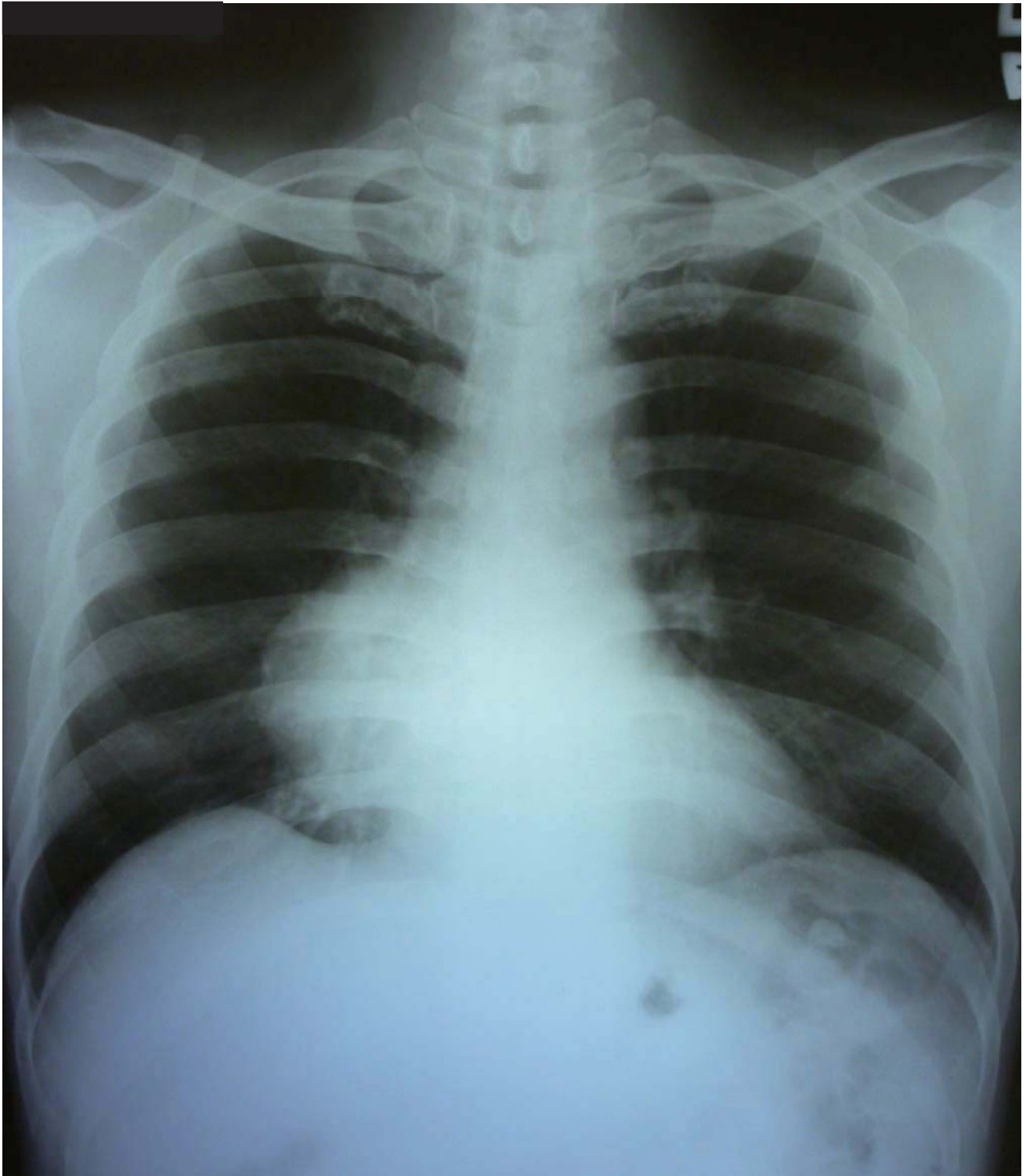




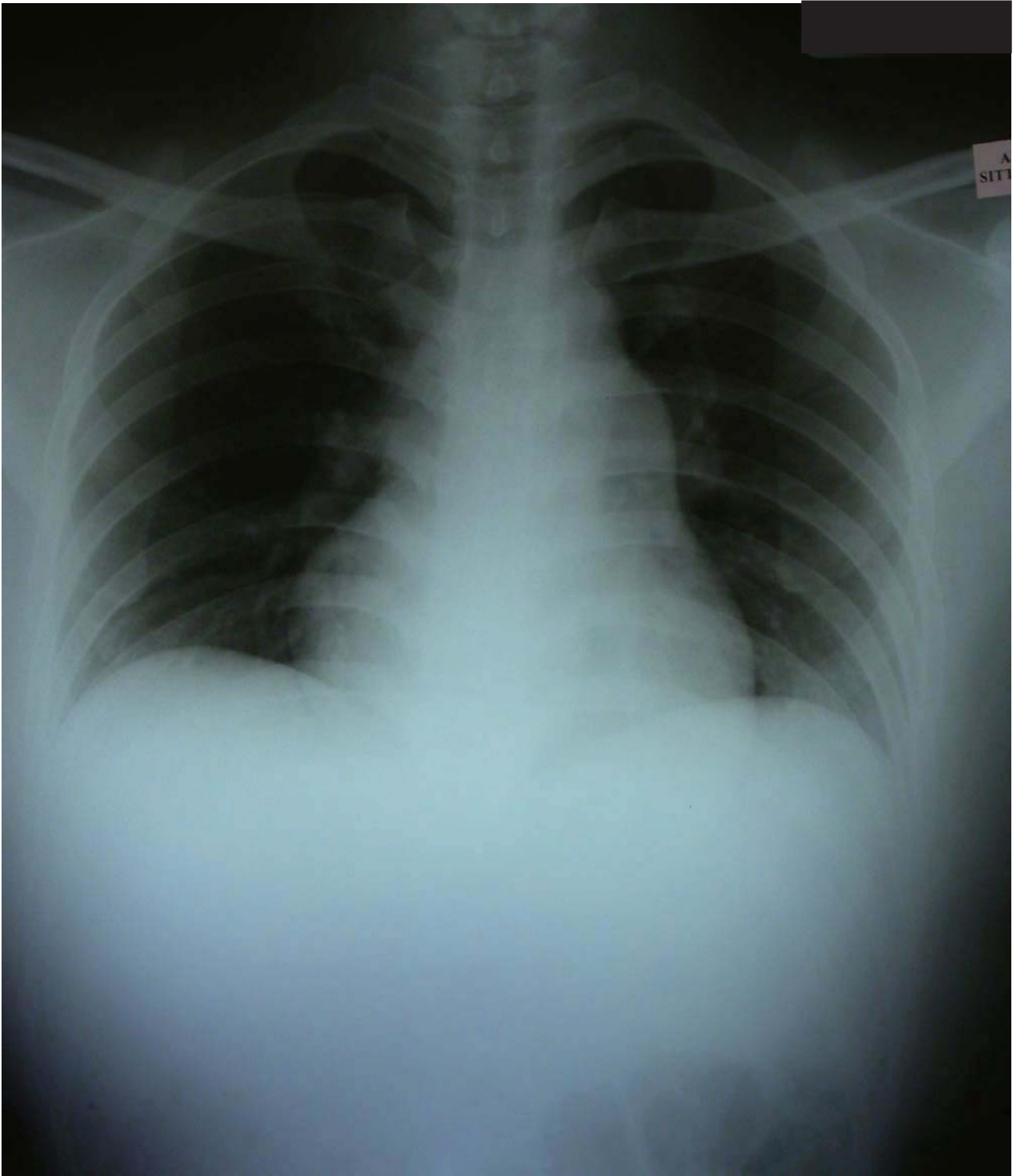
4

A 12-year-old boy injured his left elbow during football playing.

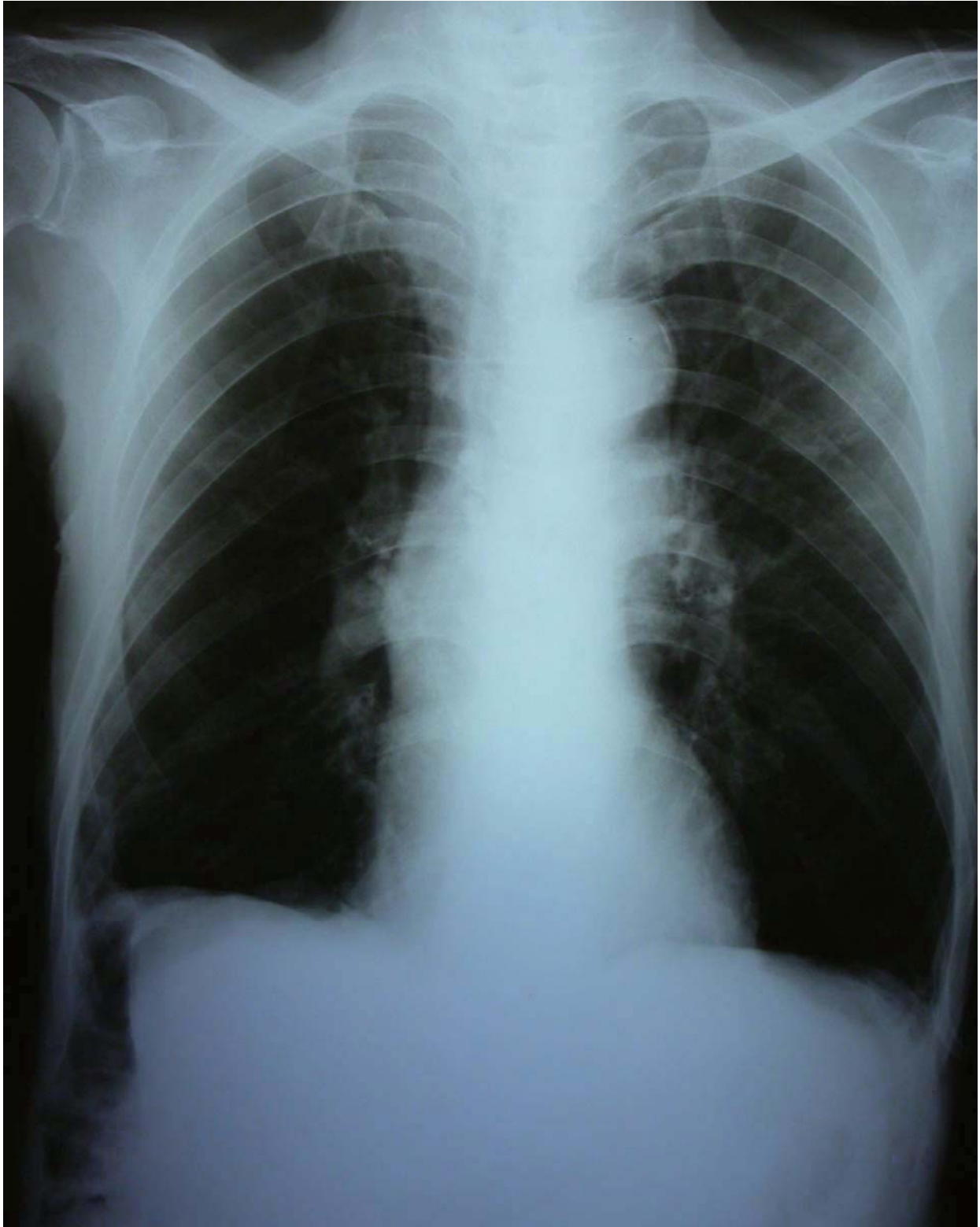
- Describe the X-ray findings.
- What is the diagnosis?
- What are the most common late complications?
- What is the best way of treatment?



5a	X-ray findings	
	Diagnosis	



5b	X-ray findings	
	Diagnosis	



5c	X-ray findings	
	Diagnosis	