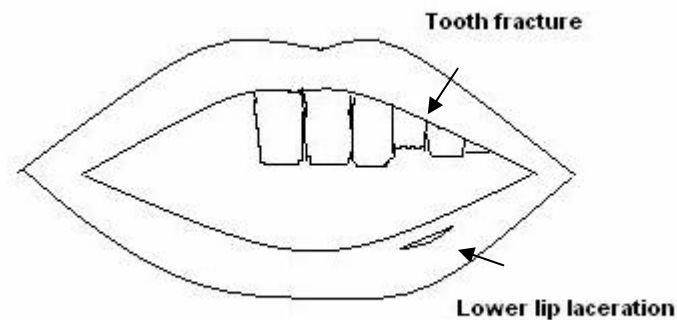


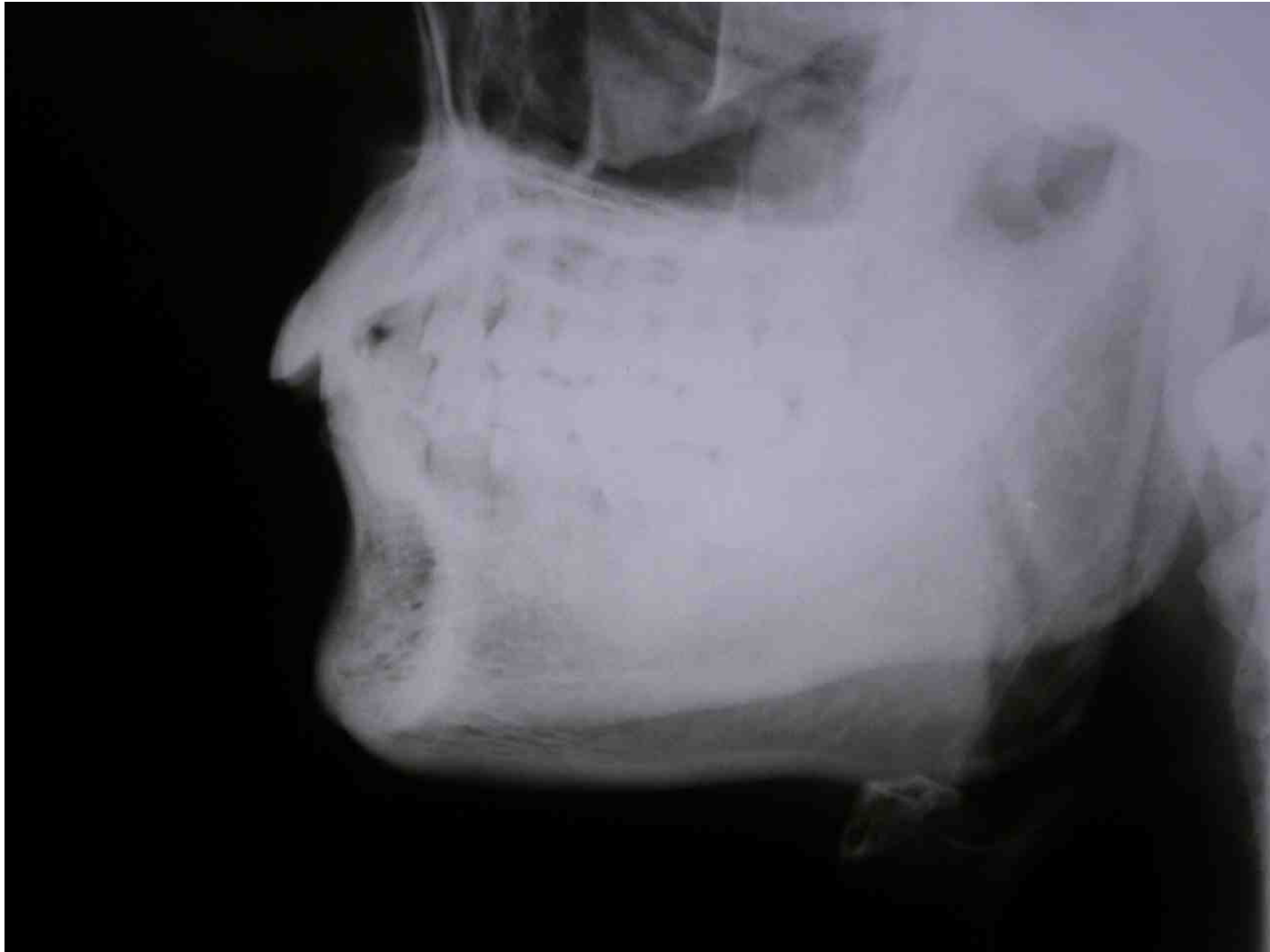Case 1

- M/31
- S/F, fell forward with chin injury
- P/E: fracture of left upper teeth and lower lip laceration
- Laceration wound sutured and D/C

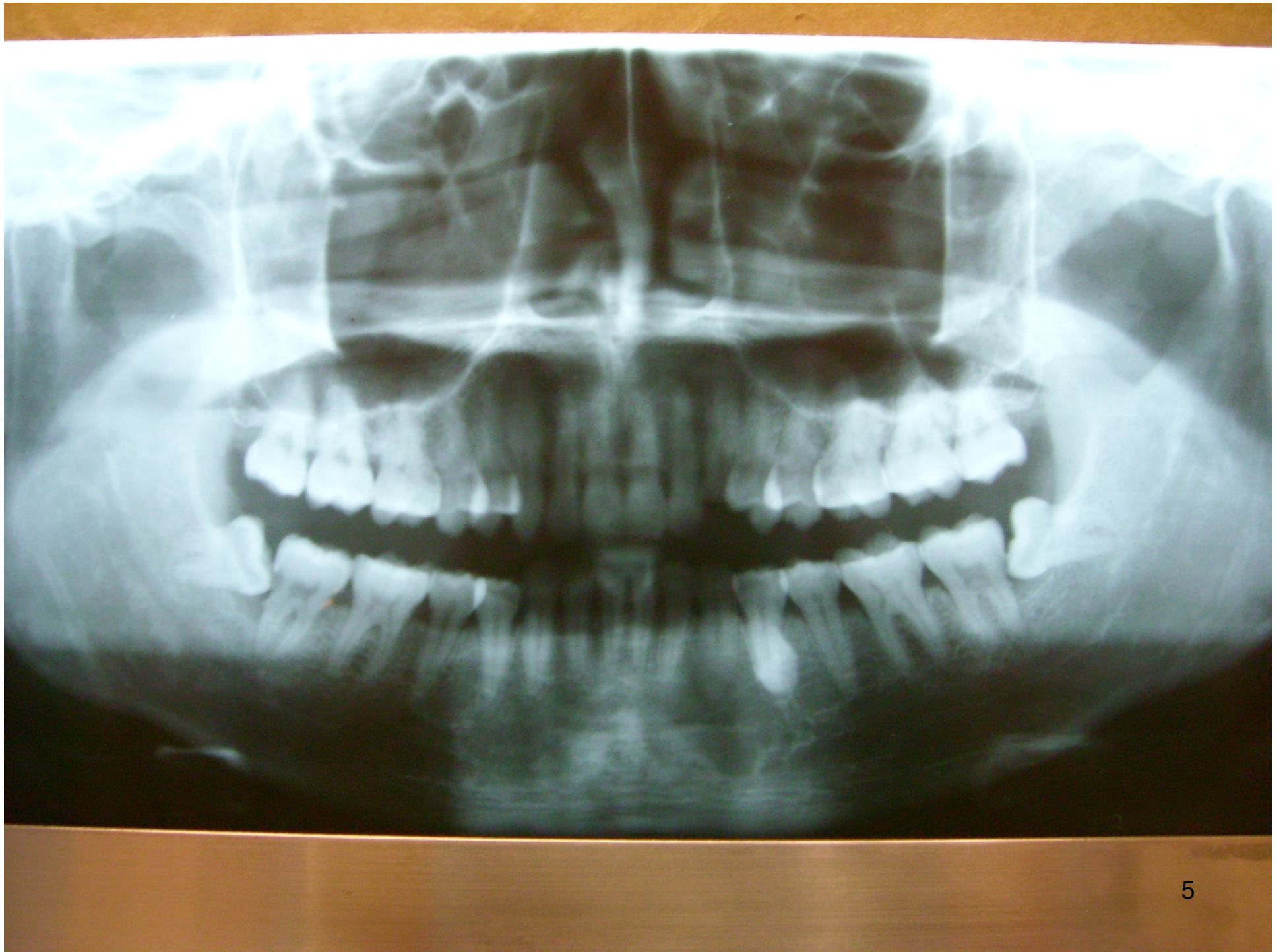


1 month later

- Reattended AED and complained of persistent lower lip wound swelling
- P/E: a submucosal nodule 0.5cm x 1cm over wound
- What is (are) the differential diagnosis?
- X-ray was taken in AED.
- You are not satisfy with this X-ray. What would you do if you want to confirm your preliminary diagnosis in AED?

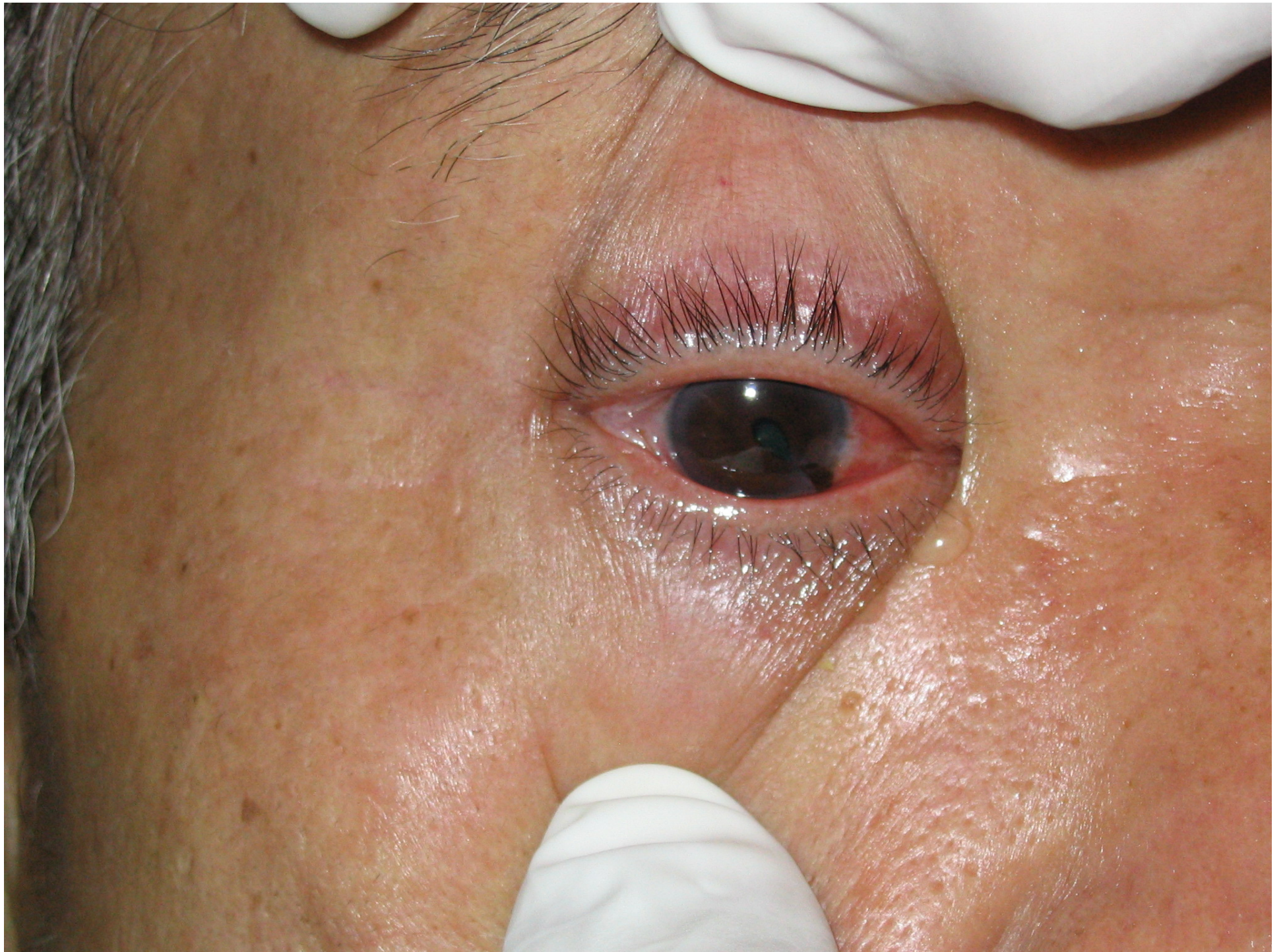


- dental surgeon was consulted.
- X-ray was taken
- What is the name of this radiological investigation?
- What is (are) your findings ?
- How do you number the fractured teeth ?



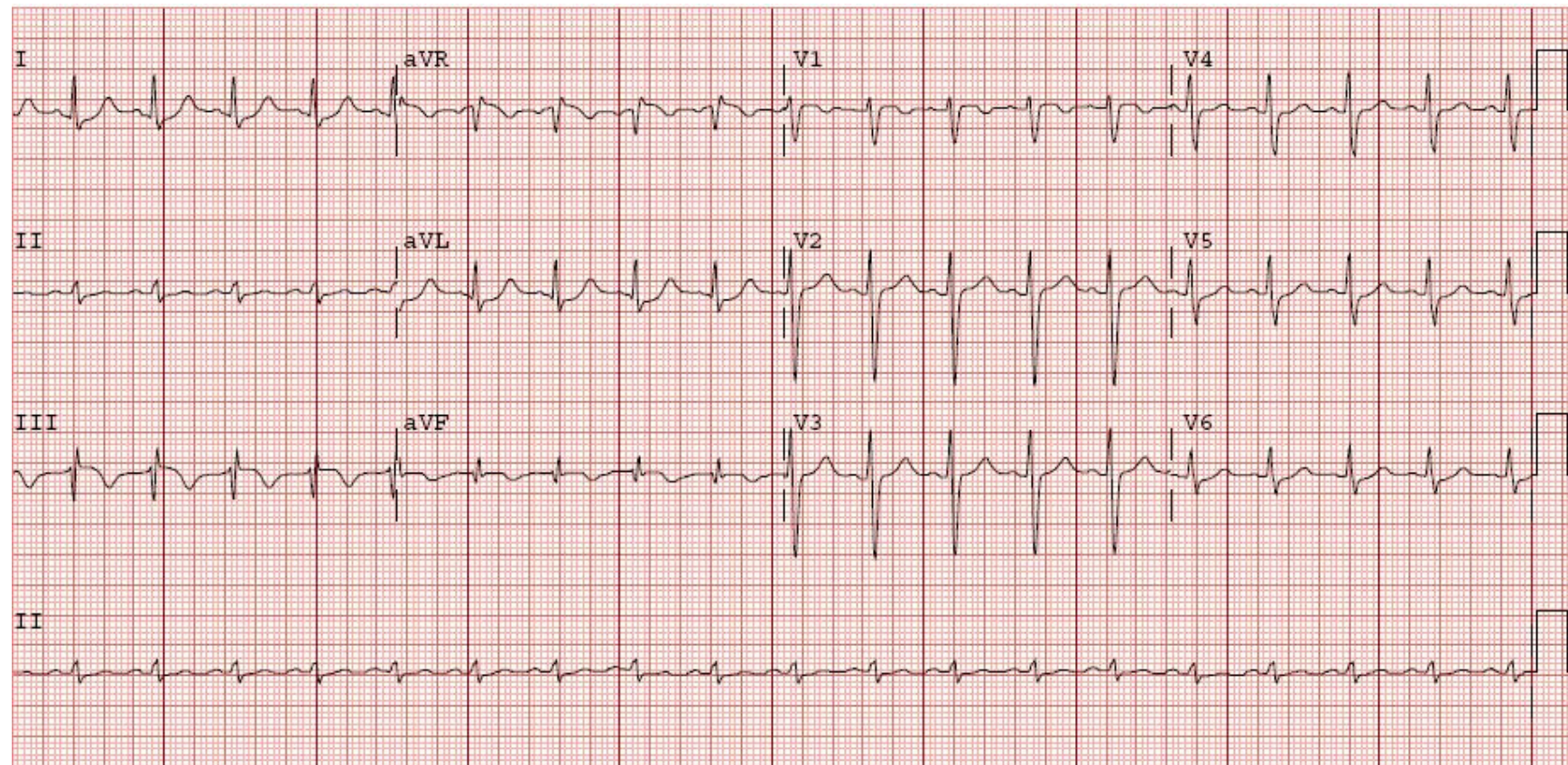
Case 2

- M/50
- Right eye blunt injury by object during working
- What is(are) your findings ?
- How do you manage the patient ?



Case 3

- M/41
- c/o: chest pain x 3 days , mild SOB for 1 day
- History of recent deep right leg laceration with surgical exploration done with short leg slab applied
- BP/94/69 p=127, RR 20/min
- P/E: heart, chest and abdomen unremarkable



- What is your preliminary diagnosis?
- What features can be present if echocardiography is to be performed?
- Suppose the diagnosis has been confirmed, what are the choices of treatment?

Case 4

- F/78
- PHx: DM, HT
- F/78
- Abdominal pain for two days and coffee-ground vomiting for 4 times today
- BP 93/61
- Abdomen: generalized tenderness
- AXR taken
- What is(are) the findings?

