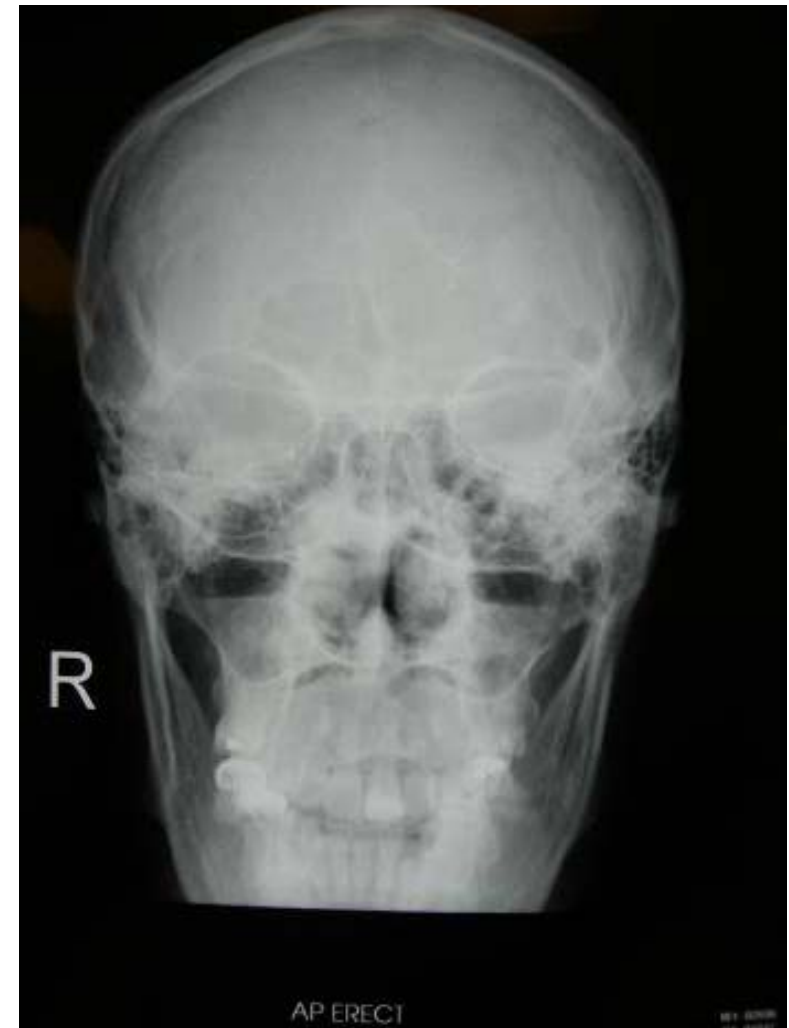
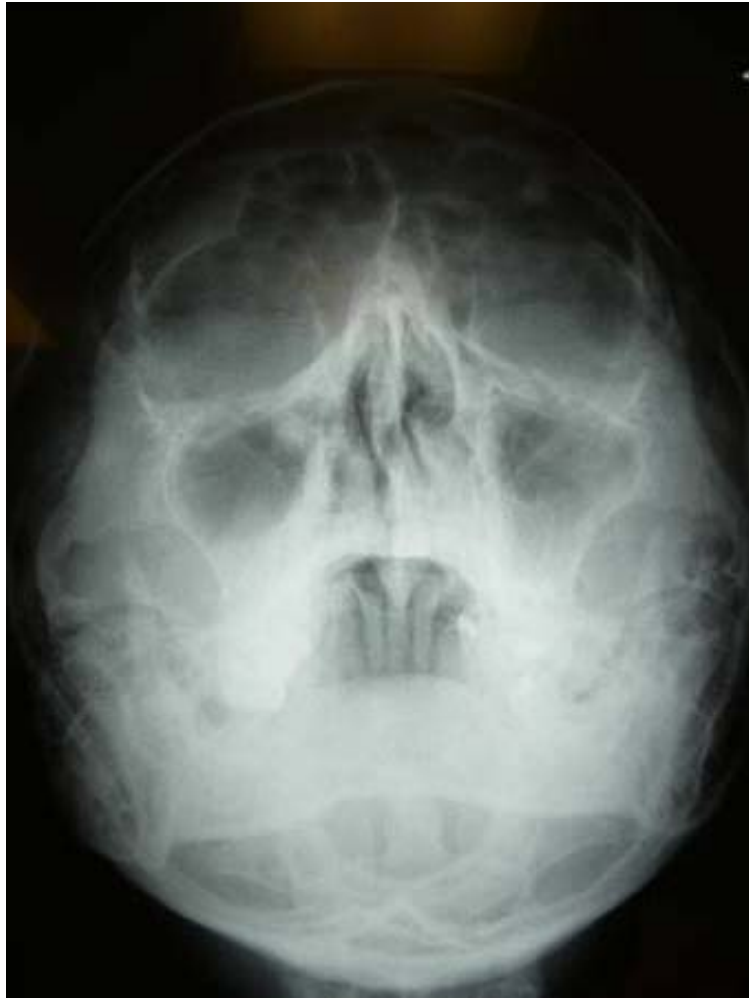OSCE

2 April 2008

QMH AED

Question 1

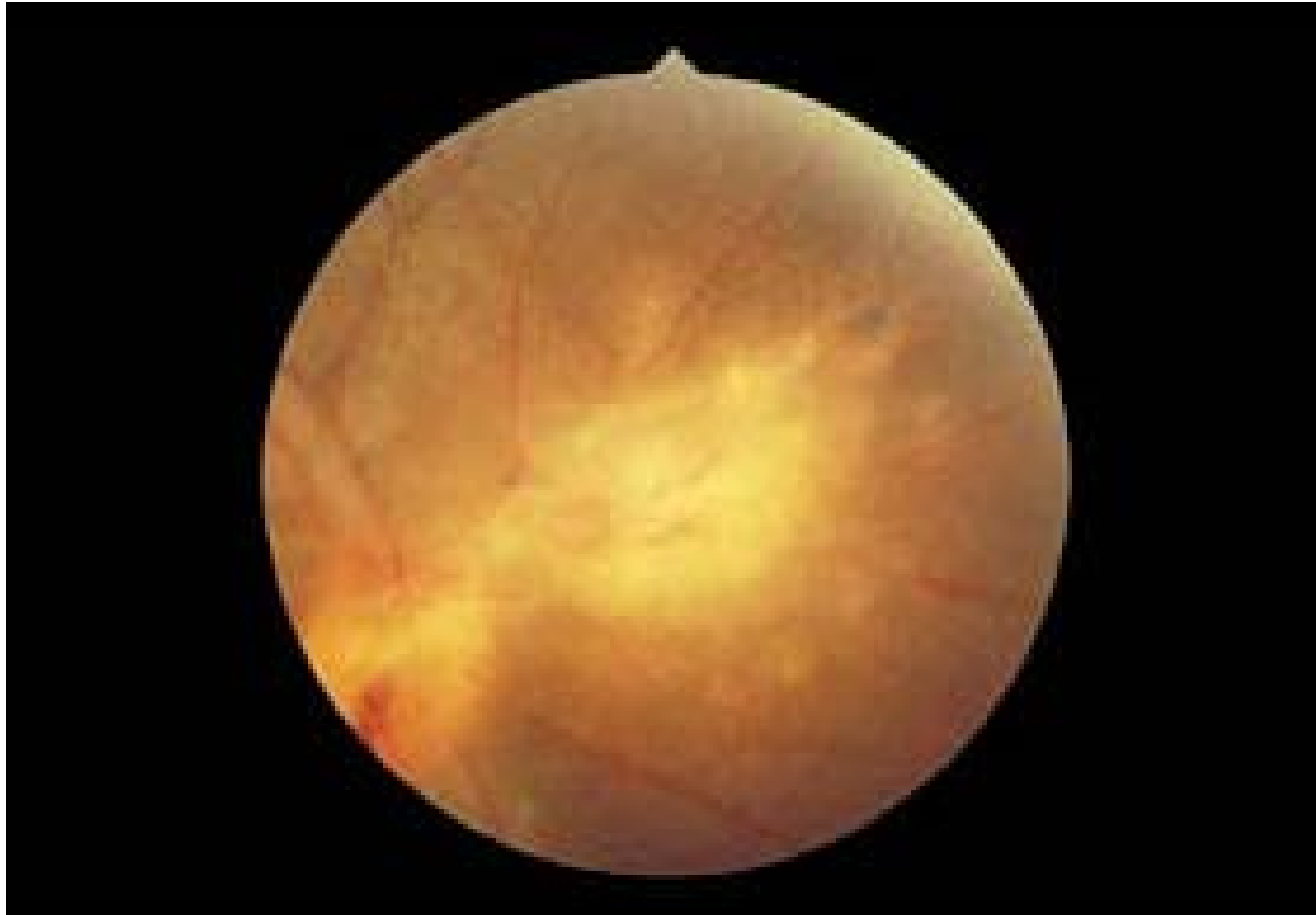
A young man attended A&E because of road traffic accident 3 days ago. He was seen in walking clinic. On examination, he was conscious and vital signs were stable.



-
1. Comment on the X rays.(1 pt)
 2. What is the name and type of such condition in (1)? (1 pt)
 3. Briefly describe your management. (2 pts)
 4. What particular manoeuvre you should warn him not to do? (1 pt)

Question 2

- F/25, Indonesian domestic helper, good past health
- Complained of blurred right eye vision for 1/52, floaters.
- No history of injury, no eye pain, no photophobia
- History of cats contact in Indonesia about 10 years ago
- P/E: VA RE 1/30, LE 20/20
- RE: no conjunctiva injection, cornea clear



-
1. What is the diagnosis? (1 pt)
 2. What features can you see from fundoscopy? (1 pt)
 3. What is the treatment? (2 pts)
 4. What other important investigation would you like to do? (1pt)
-

Question 3

- M/78, good past health
- Complained of acute retention of urine for 1 day, taken cough mixture for 2 days for URI symptoms
- Incidentally found tachycardia, BP stable

Indications:

For the control of dry cough and relief of symptoms associated with common cold, influenza, upper respiratory allergies, rhinitis, bronchial irritation and hay fever.

Helps loosen thick sputums and aids clear breathing. It should be taken with plenty of water.

Composition:

Camphorated Opium Tincture	1.00ml.
Ephedrine HCl	5.00mg.
Butetamate Citrate	5.00mg.
Ammonium Chloride	110.00mg.
Chlorpheniramine Maleate	2.50mg.
Flavoured Syrup to	5.00ml.

Dosage:**Adults:**

One to two 5ml spoonfuls, 3-4 times daily after meals and at bedtime.

Children 6-12 years:

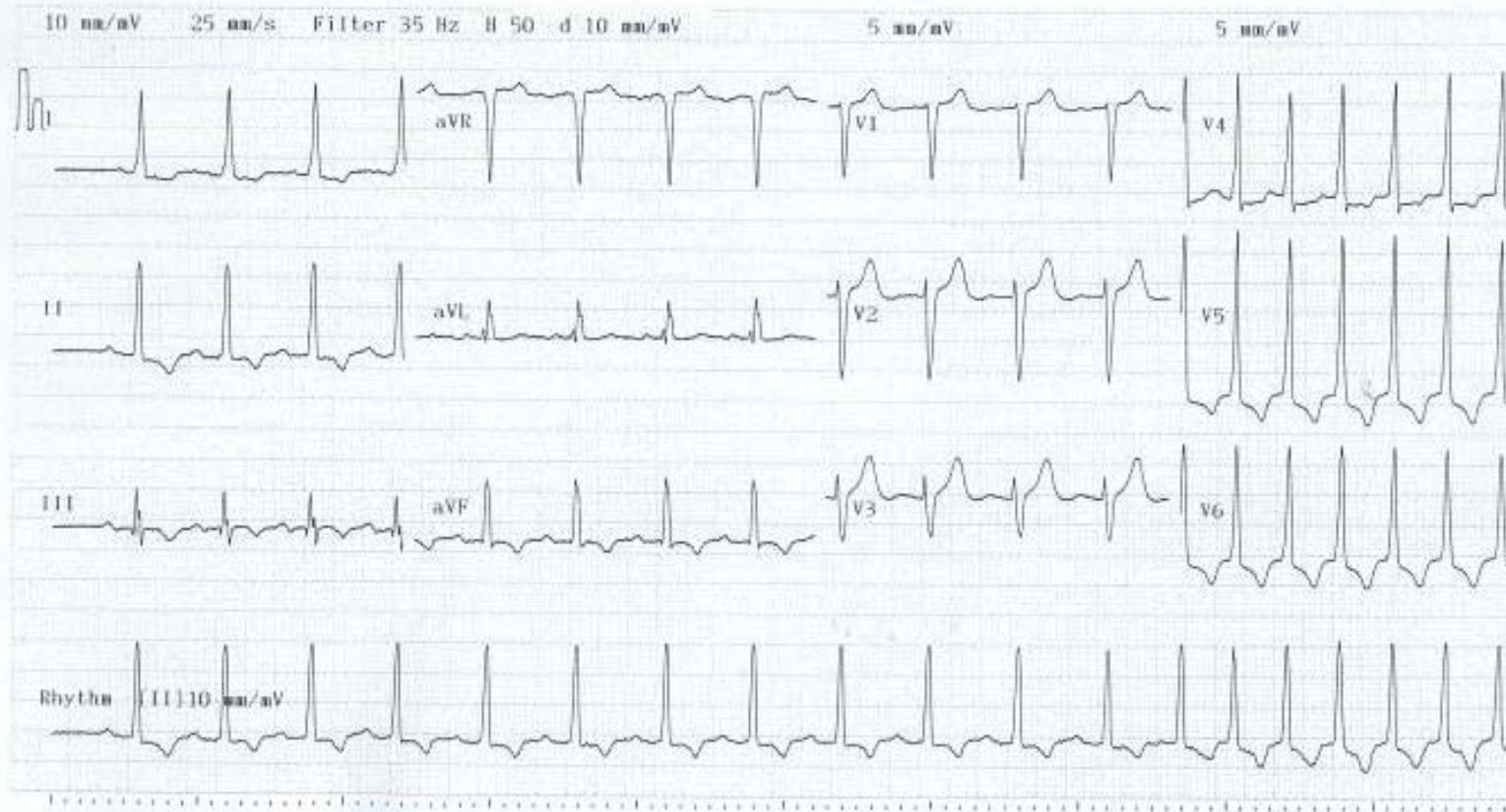
Half to one 5ml spoonful, 3-4 times daily after meals and at bedtime.

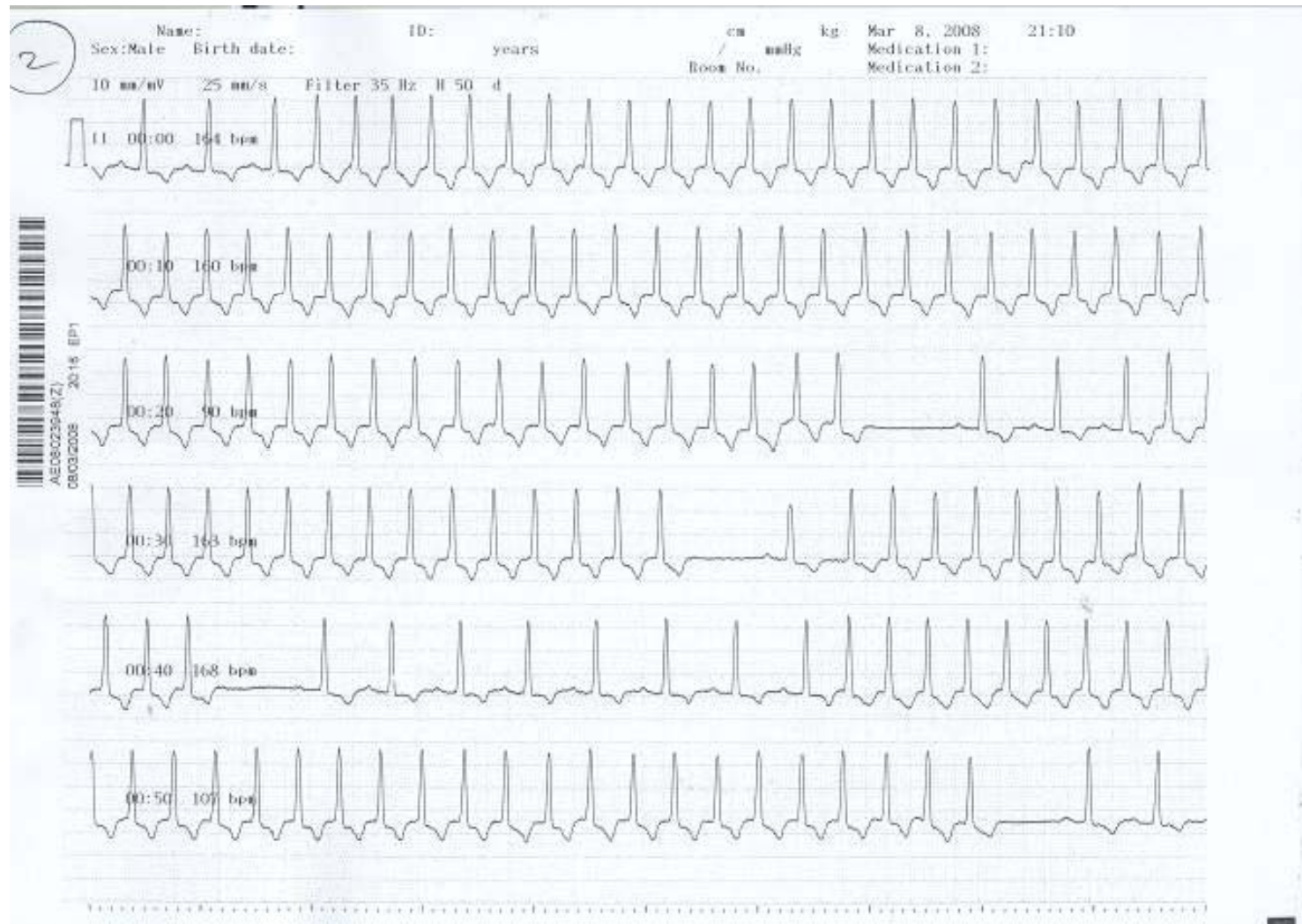
Jean-Marie Pharmacal Co., Ltd.
Hong Kong
Hong Kong Permit No.HK-41279

Name:
Sex: Male Birth date:
cm kg / mmHg
Medication 1:
Medication 2:
Room No.

Vent. rate 114 bpm
PR int. **** ms
QRS dur. 98 ms
QT/QTc int. 346/ 414 ms
P/QRS/T axis ****/ 30/ 251 °
RV5/SV1 amp. 5.290/ 2.445 mV
RV5+SV1 amp. 7.735 mV

Unconfirmed Report
Reviewed by:



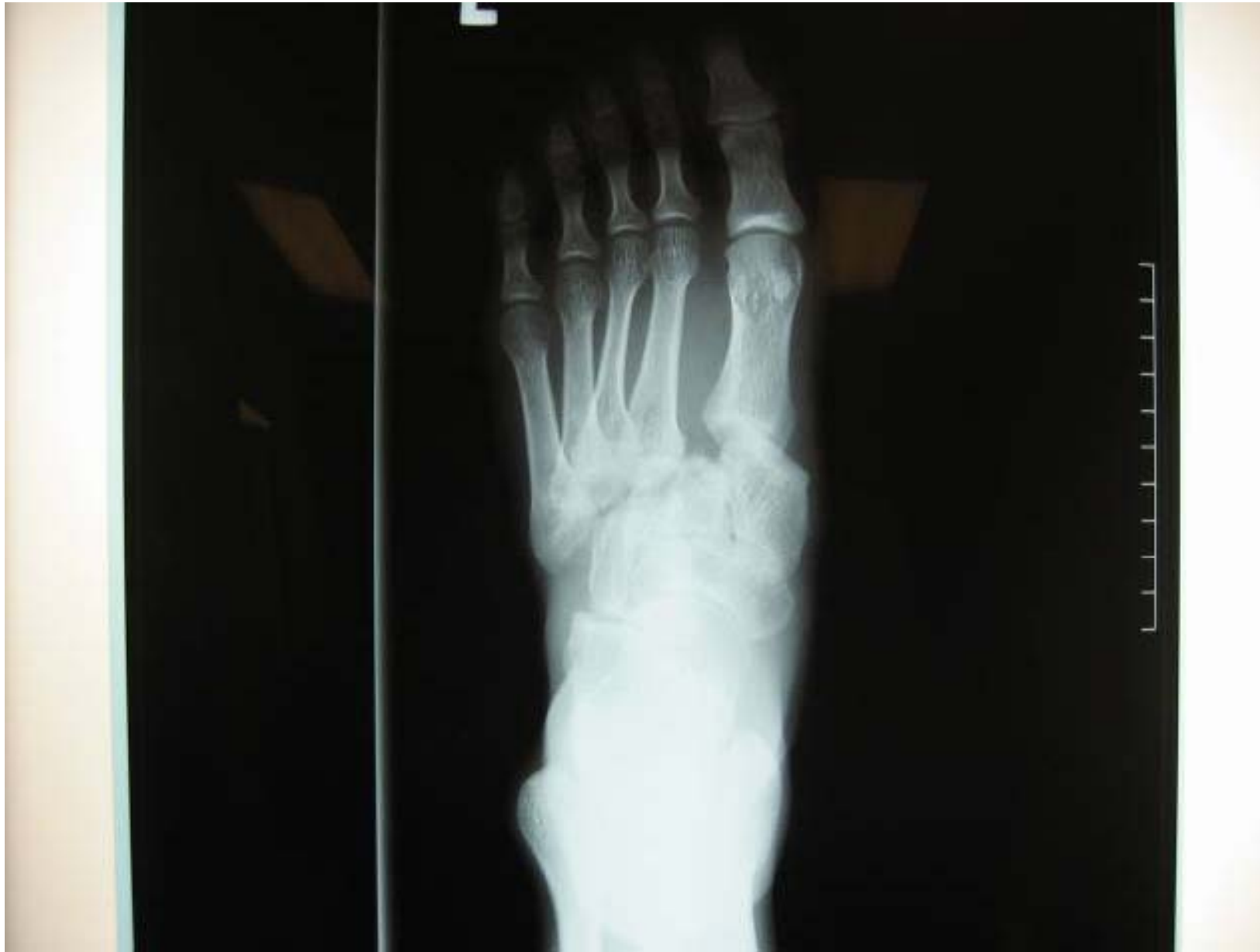

-
1. What is the rhythm showed in ECG? (1 pt)
 2. What is your initial treatment? (1pt)
 3. If the patient not respond to initial treatment, what are the choices of treatment? (1pt)
 4. What is the possible cause for the arrhythmia for the patient? (1pt)
-

Question 4

A 30-year-old man had fallen from 10 feet high complaining left foot pain. His vitals signs were stable.

1. What are the X ray abnormalities? (2 pts)



2. What is the name of such condition? (1 pt)

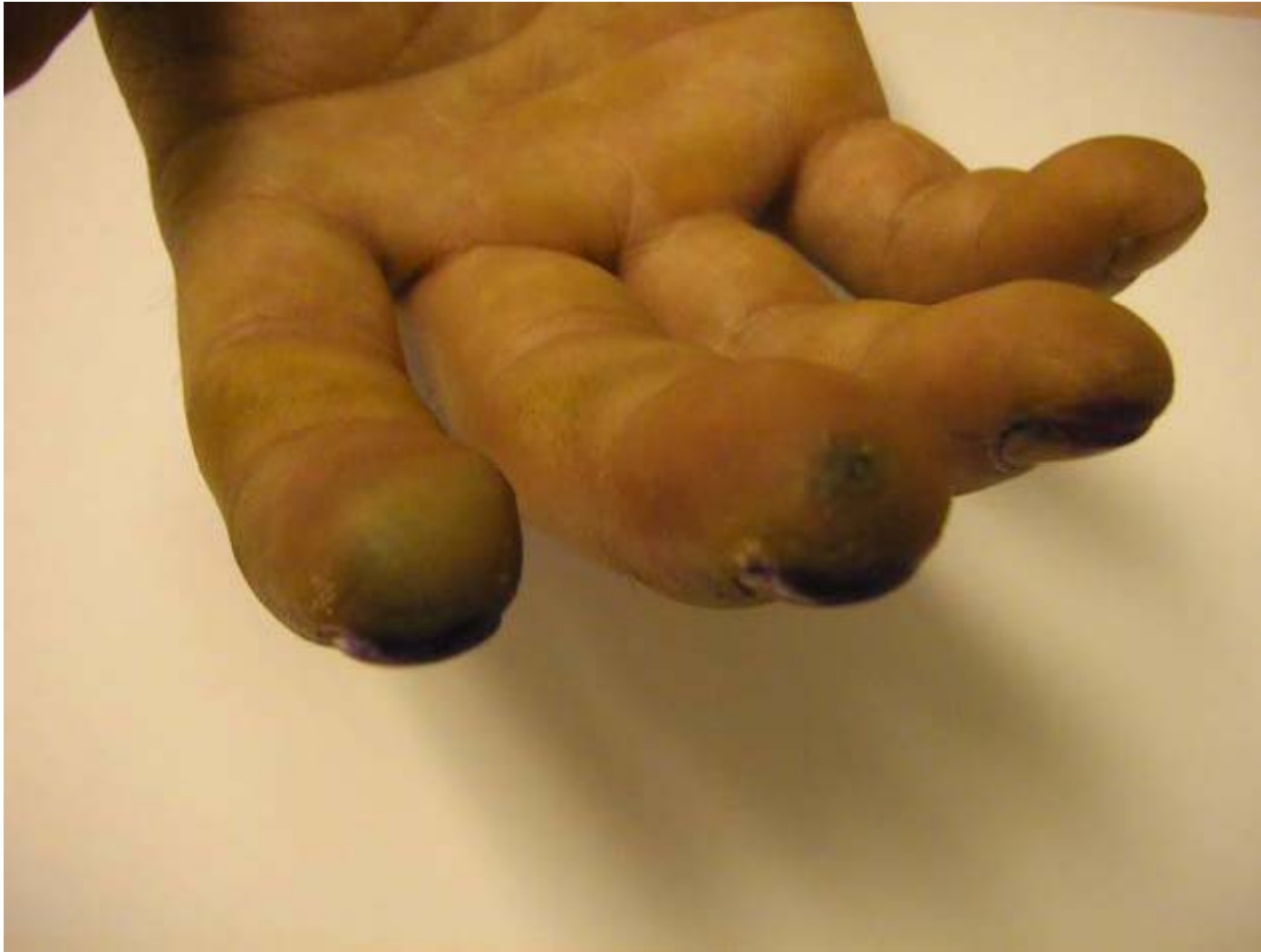3. What are the possible complications of (2)?
(2 pts)

4. What is your treatment? (1 pt)

Question 5

A 36-year-old man with good past health complained of intense pain over fingers of his right hands. He had used a type of chemical agent for rust-removal 3 to 4 hours before presenting to our department. Pulses of limbs were strong and equal. He had no systemic upset upon presentation. (Hint: That agent can also be used for glass etching)





-
1. What is the likely culprit? (1 pt)
 2. What are the potential complications? (2 pts)
 3. What is your treatment plan? (2 pts)

Question 6

A 34-year-old woman complained of right upper quadrant pain and fever for five day. Mild localized tenderness was elicited at the right upper quadrant. She was not pregnant. BP109/61 and pulse rate was 102/min.

-
1. Give 4 differential diagnoses. (2 pts)
 2. List 3 abnormalities of the CT films. (3 pts)
 3. What is the most likely diagnosis? (1 pt)
 4. Give 2 possible causative organisms of this disease in (i) developed and (ii) developing countries? (2 pts)
-

