Perineum Injury

WY Cheung
Case Presentation, Joint Clinical Meeting
AED QMH

Patient A M/42

- Good past health
- S/F with blunt trauma from his heel to the perineum 1 week ago (23/8/2008)
  - Subsequently developed red, swollen and painful buttocks
  - No response to NSAIDs & antibiotics given by GP

Patient A M/42

- Area of involvement continued to increase
- Rt. inner thigh egg-shaped swelling for 3 days
- ? Brownish-red discharge from perineum
- On presentation to AED, the redness and swelling had progressed to involve his scrotum

Patient A M/42

- No hematuria, dysuria, or other urinary symptoms
- No problems with defecation
- No fever, chills, or rigor

Physical Examination

- GC good
- BP 95/62mmHg (RC 87/48mmHg), P 133/min, Temp 36°C, RR 16/min
- Hot, tender, erythematous swelling involved bilateral buttocks
  - extension to scrotum, bilateral upper thighs
  - penis spared

Physical Examination

- Testis not palpable due to scrotal tenderness & edema
- No discharge from penile meatus, no tenderness along penile shaft
- 4x3cm bulla with dark brownish content at Rt. inner thigh near the perineum
  - surrounded by a thin rim of gangrenous skin

Physical Examination

- Abdomen: soft & non-tender
- PR exam: no mass / swelling, no obvious tenderness

- Differential Diagnoses?
- Predisposing factors and causes of infection?
- Common causative organisms?
- Management?
- Choice of antibiotics?
- Surgery?

Differential Diagnoses

- Perineal and scrotal abscess
- Extensive perineal and scrotal cellulitis
- Fournier's gangrene
- Strangulated hernia
- Vascular occlusion syndrome

Management

- Problems:
  - Tachycardia, hypotension
  - Extensive perineal infection
- Management:
  - Intravenous access and fluid resuscitaion
  - IV antibiotics
  - Blood tests and imaging studies
  - Urgent consult surgeon and ICU
  - Surgical exploration and debridment

Management in AED

- O2 2L/min, transferred to resuscitation room with close monitoring of vital signs
- IV access x 2, Blood x CBP, R/LFT, RG, clotting, T & S, culture
- Initial resuscitation with 2.5L of fluids over 1 hour
  - Subsequent BP 92/55mmHg, P 100/min

Management in AED

- Started on IV penicillin G 2 megaunit & clindamicin 600mg
- Urgently consulted surgeon on-call and urologist
- Urgent CT abdomen and pelvis
- Transferred to ICU

Investigation

- WBC 21.08
- Hb 11.7
- Hct (%) 33.2
- Plt 207

- PT 15.4
- aPTT 41.6

- pH 7.19
- pO_2 28.4
- pCO_2 6.3
- HCO_3 18

- Na 137
- K 4.0
- Urea 18.3
- Cr 410
- AST 36
- ALT 39
- Albumin 29

- Temp 36
- HR 133
- RR 16

CT Abdomen and Pelvis

CT Abdomen and Pelvis

- Fluid collection affecting corpora cavernosa of penis and scrotum
- Fluid and air extended into bilateral ischioanal fossa with fat stranding (Rt. > Lt.)

CT Abdomen and Pelvis

- Scrotum is swollen with thickened skin and multiple internal air densities
- Air densities extending to Rt. lower anterior chest wall

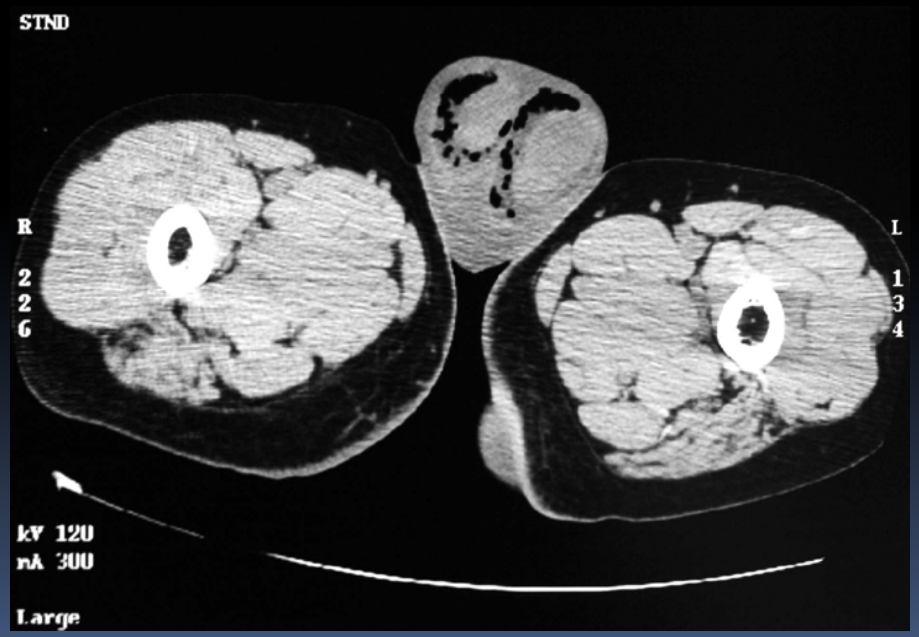

Operations on D0

- Emergency excisional debridement and laparotomy performed jointly by urologist, plastic and colorectal surgeons

Operative Findings

- Gangrenous patch over perianal region at 7 o'clock with surrounding erythema spreading to bilateral upper thighs
- Scrotal erythema, edematous with subcutnaeous pus
- Surgical emphysema over scrotal wall, anterior abdominal wall and up to chest wall (no erythema/ gangrene)

Operative Findings

- Bilateral testes healthy, urethra not involved
- 2cm rectal perforation (at 7 o'clock, 5 cm from anal verge) causing right ischiorectal abscess & Fournier's gangrene

Operative Procedure

- Scrotal, perianal and bilateral upper thigh skin, necrotic subcutaneous tissue debrided till healthy bleeding
- Ischio-rectal abscess drained
- Bilateral testes buried in subcutaneous thigh pouches

Operative Procedure

- Peritoneal lavage and diverting loop sigmoid colostomy done
- Abdominal skin incised for exploration
- Wound packing

Progress

- Septic shock controlled with double inotropes (dopamine and noradrenaline infusion)
- Acidemia, dehydration, renal impairment and anaemia corrected
- Extubated on D2

Progress

- Initially on IV empiric tazocin + levofloxacin
- Bacterial cultures revealed
  - Aerobes: E. coli, enterococcus, proteus
  - Anaerobes: Bacteroides
- Changed to IV augmentin (total: 44 days)

Progress

- Underwent multiple operations
- Stable under care of plastic surgeon (D96)

5 operations

- Excisional debridement of perinuem, scrotum and upper thighs + laparotomy + sigmoid colostomy (D0)
- Wound debridement and irrigation of bilateral lower trunk and groin (D1)
- Wound debridement and irrigation and EUA of anus/ ischiorectal abscess (D13)
- Wound debridement and closure with right pedicled anterolateral thigh flap (D35)
- Debridement of necrotic anterior perineum flap + split-thickness skin graft from right thigh (D49)

Fournier's Gangrene

- Fulminant gangrene of the penis & scrotum
- Gangrenous erysipelas of the scrotum
- Necrotizing fasciitis of the perineum
- Periurethral phelgmon
- Phagedena
- Synergistic necrotizing cellulitis
- Fournier's gangrene

Fournier's Gangrene

- In 1764 Baurienne originally described an idiopathic, rapidly progressive soft tissue necrotising gangrene of the male genitalia
- First coined by Prof. Jean Alfred Fournier (French venereologist) in 1883
  - Idiopathic condition affecting the penis & scrotum which rapidly progressed to gangrene in young males

(Fournier AJ. Gangrene foudroyante de la verge. Semaine Medicine.1883;3:345.)

Fournier's Gangrene

- Contemporary Definition:

  "a synergistic, polymicrobial necrotizing fasciitis of the perineal, genital or perianal regions"

  - Not limited to young or male patients
  - Causative etiology is usually identified

Pathophysiology

- *Synergistic & polymicrobial* infection causing *obliterative endarteritis* of the subcutaneous arteries
- Resulting in gangrene of the subcutaneous tissue and overlying skin

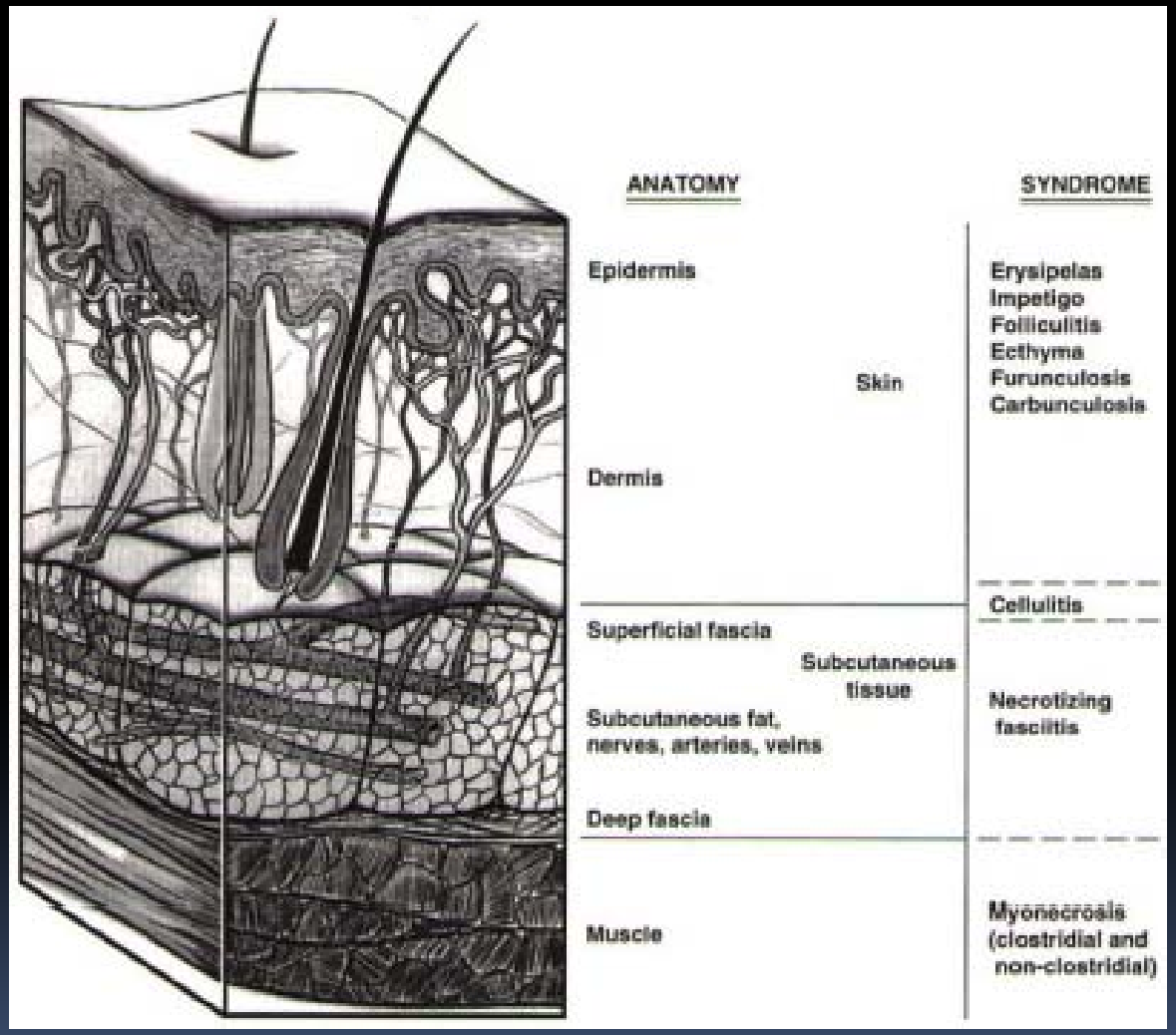

Pathophysiology

- Organisms probably pass through the Buck's fascia to spread along the planes of:
  - Dartos fascia of the scrotum and penis
  - Colles' fascia of the perineum
  - Scarpa's fascia of the abdominal wall
- Testicular involvement is rare, as testicular arteries originate directly from aorta

Epidemiology

- Frequency:
  - Relatively uncommon, true incidence unknown
  - Average of 97 cases per year (1989-1998)

(Eke N. Fournier's gangrene: a review of 1726 cases. British Journal of Surgery. Jun 2000;87(6):718-28)

- Male to female ratio = 10:1
- Age group: 30 – 60 years old
- Mortality: ~3 – 67%

Etiology

- More than 75% cases have identifiable cause
- Originate from an infection:
  - *Anorectal:*
    - Perianal, perirectal, and ischiorectal abscesses, anal fissures, diverticulitis, appendicitis, colonic perforation, colorectal malignancy
  - *Urological:*
    - Chronic UTI, infection of bulbourethral glands, epididymitis, orchitis, renal abscess, urethral stones, urethral stricture
  - *Dermatological:*
    - local cellulitis, furuncle, hidradenitis suppurativa, blunt perineal trauma

Etiology

- Other causes:
  - *Iatrogenic:*
    - Urethral instrumentation, prosthetic penile implants, genital piercing, complication of surgery (hemorrhoidectomy, herniorrhpahy)
  - *Women:*
    - Septic abortion, vulvar or Bartholin gland abscesses, episiotomy
  - *Children:*
    - Circumcision, strangulated ingunial hernia
  - *Less common causes:*
    - Bone marrow malignancy, SLE, Crohn's disease, HIV

Predisposing factors

- Diabetes mellitus (up to 60%)
- Alcoholism (up to 50%)
- Cirrhosis
- Morbid obesity
- Any condition resulting in immunosuppression (HIV, malignancies, leukaemia, malnutrition, chronic systemic steriod use)
- Urological instrumentations

Causative Micro-organisms

- Polymicrobial: average of 4 isolates per case
- Organisms involved are commonly commensals
  - *Aerobic:*
    - E. coli, streptococcus, staphylococcus, enterococcus, proteus, pseudomonas, klebsiella, clostridium
  - *Anaerobic:*
    - Bacteroides
  - Fungi

Clinical Presentation

- Sudden or insidious
- Signs of inflammation of in the perineum and or genitalia (~70%)
  - PAIN OUT OF PROPORTION TO SIGNS
- Purulent discharge (~60%)
- Fever & tachycardia (~40-60%)
- Crepitus (~50%)
- Septic shock (~10%)
- Gangrene

HIGH INDEX OF SUPICIOUS REQUIRED!

Ersay A et al. Factors affecting mortality of Fournier's gangrene: review of 70 patients. ANZ Journal of Surgery. 2007; 77:43-8

Investigations

- Diagnosis is primarily based on clinical findings
- Blood tests: to evaluate possible acid & base and electrolyte disturbances, deydration, glucose intolerance, coagulopathy
- Imaging studies: should only be used to determine extent of affected areas

X-Rays

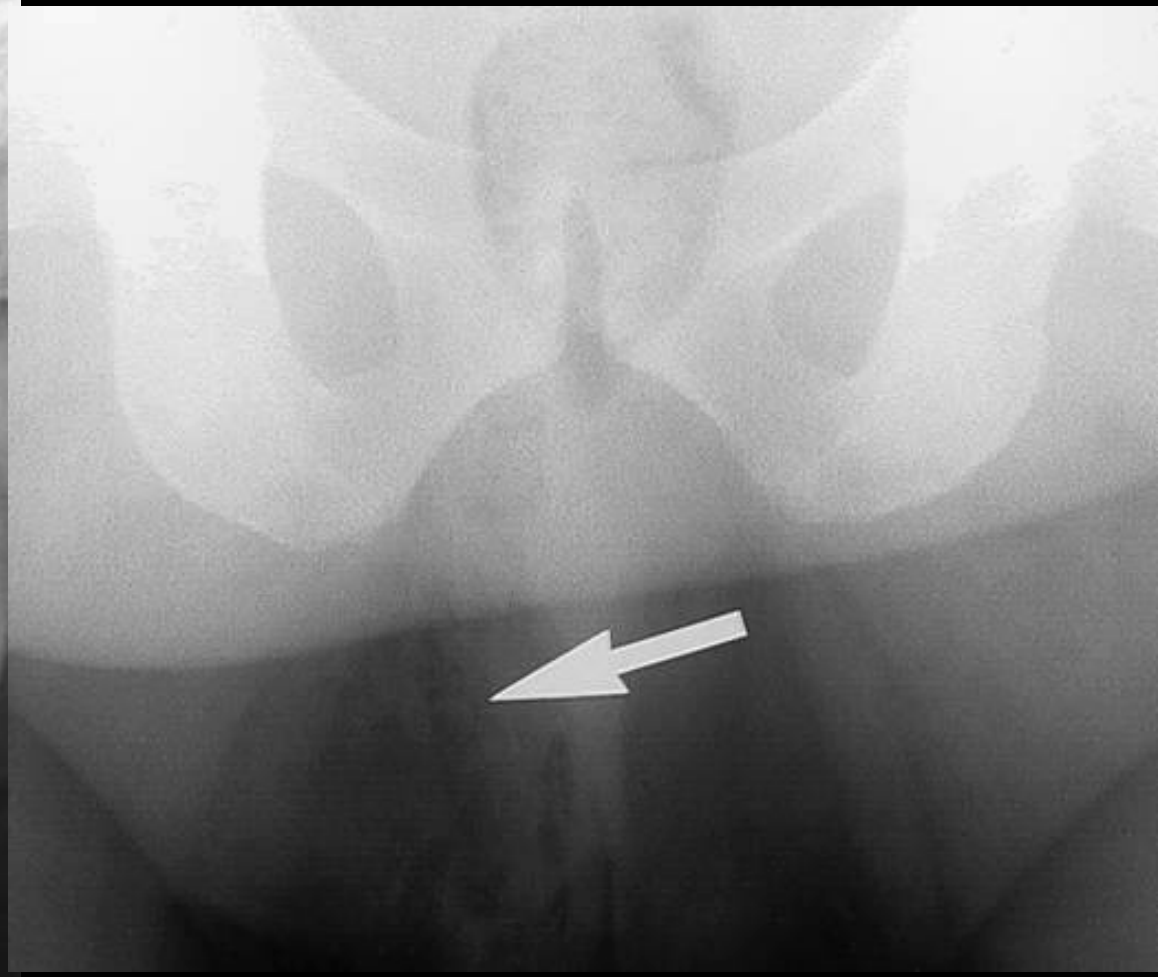

USG

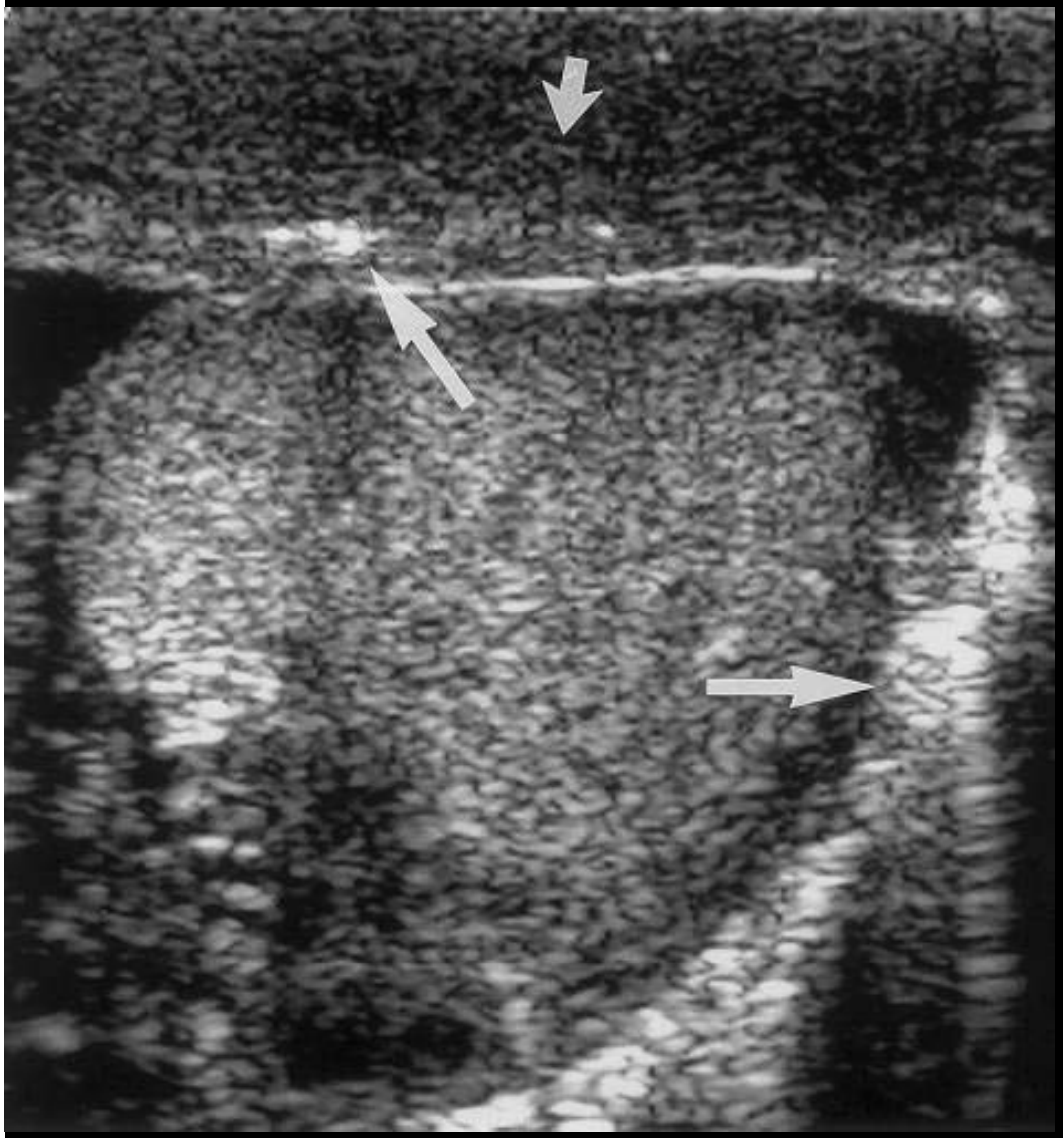

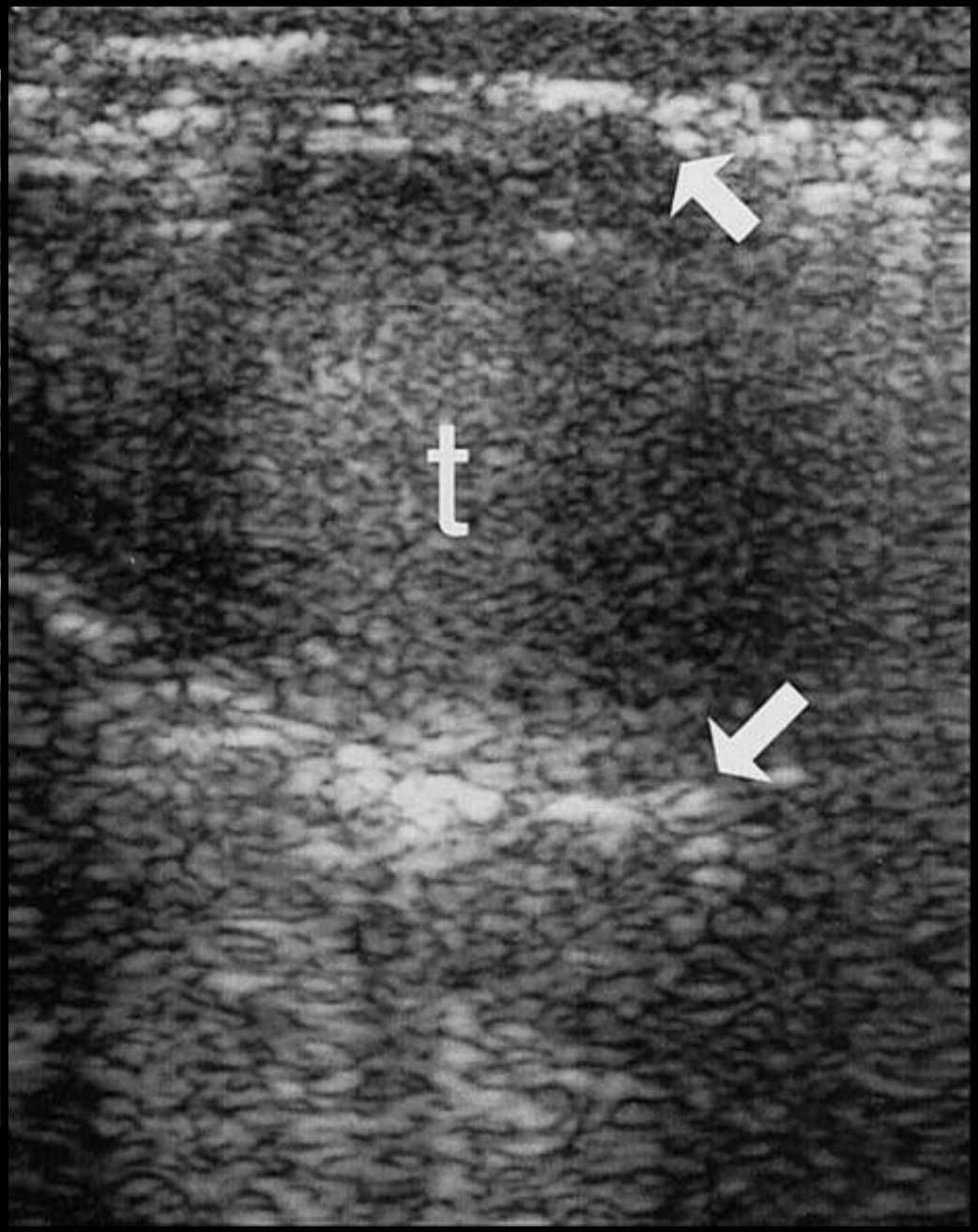

CT scan

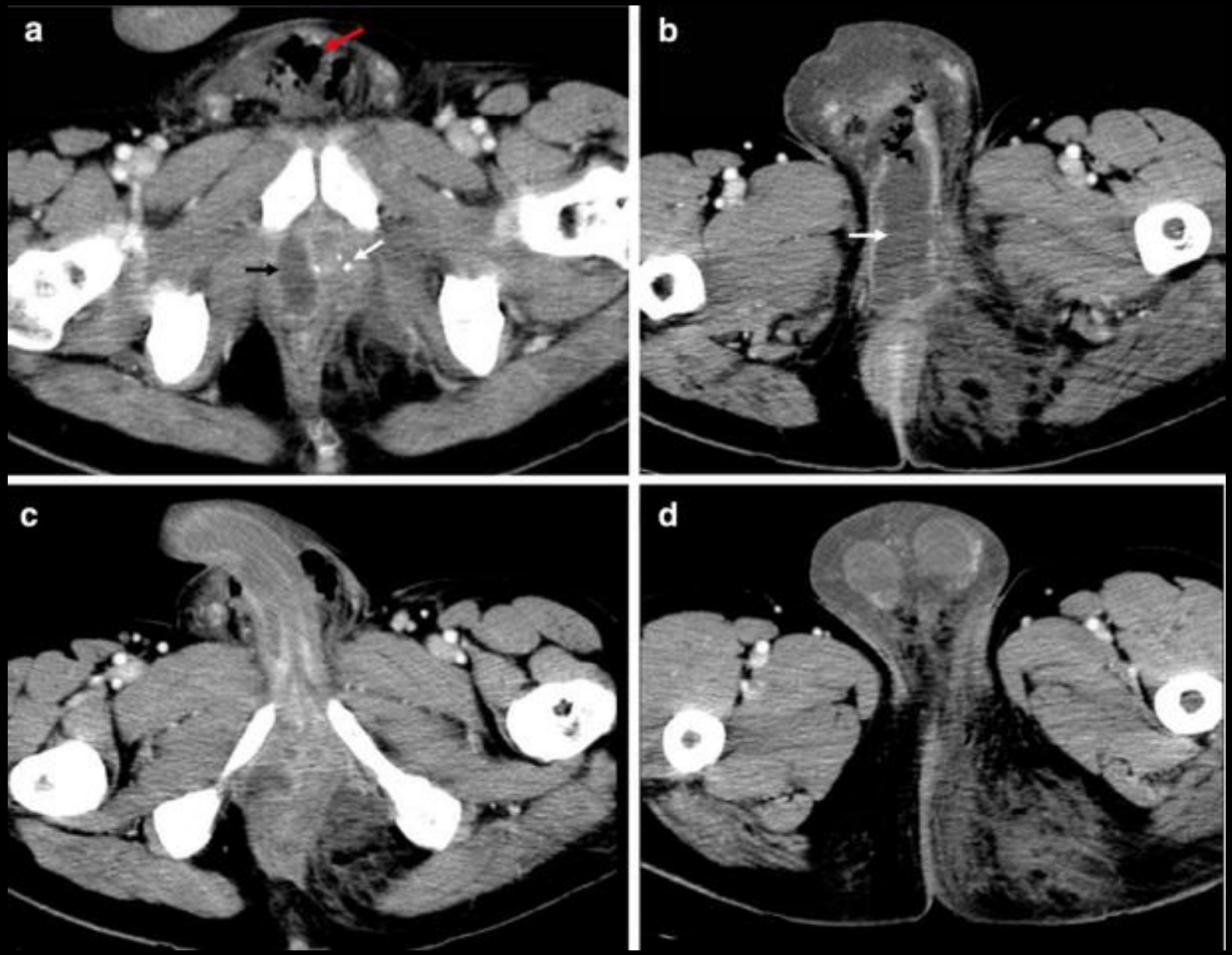

Treatment

- Aggressive resuscitation
- IV antibiotics
  - Penicillin: for streptococcus
  - Metronidazole: for anaerobic organisms
  - 3rd generation cephalosporin: for coliform organisms and staphylococcus

Benizri E. et al. Gangrene of the perineum. Urology 1996; 47:935-9.

- Tetanus prophylaxis
- **SURGICAL DEBRIDEMENT** is the mainstay of treatment

Surgery

- Repeated radical excisional debridement
- Fecal diversion (colostomy)
- Urinary diversion by urethral catheter
- Testis protection in subcutaneous pocket
- Reconstruction

Reconstruction

- 67% FG patients needed some type of reconstruction

Silva J et al. Fournier's gangrene: Ten year experience at a single institution. European Urology 2002 ;1 (suppl.):178

- Techniques:
  - Primary closure of skin
  - Free skin grafts
  - Split-thickness skin grafts
  - Fasciocutanoeus flap or musculocutaneous flap

Superomedial Thigh Flaps

Superomedial Thigh Flaps + Split-thickness Skin Grafts

Other Treatment Adjuncts

- *Hyperbaric oxygen:* using the same principle for treating 'gas gangrene' caused by C. perfringens
  - Increasing oxygen tensions → inhibiting & killing anaerobes
- *Unprocessed honey:* enzymatically debride, sterilize, and dehydrate wounds and to improve local tissue oxygenation and re-epithelialization

Advances in Wound Care

- Vacuum assisted closure (VAC) system dressing
  - Exposing a wound to subatmospheric pressure for an extended period
  - Increase in blood flow 4x with negative pressure values of 125 mmHg
  - Minimize skin defects, speed tissue healing
- Growth hormones, trophic agents applications

Post-operative Problems

- Pain with arousal
- Limited mobility of the genitalia due to scarring
- Impaired lymphatic drainage → edema and cellulitis
- Sexual dysfunction
- Emotional stress of a different body image

Fournier's Gangrene Severity Index

	High Abnormal Values					Low Abnormal Values			
	+4	+3	+2	+1	0	+1	+2	+3	+4
Temp	>41	39-40.9	-	38.5-38.9	36-38.4	34-35.9	32-33.9	30-31.9	<29.9
HR	>180	140-179	110-139	-	70-109	-	56-69	40-54	<39
RR	>50	35-49	-	25-34	12-24	10-11	6-9	-	<5
Na^+	>180	160-179	155-159	150-154	130-149	-	120-129	111-119	<110
K^+	>7	6-9	-	5.5-5.9	3.5-5.4	3-3.4	2.5-2.9	-	<2.5
Cr	>309	177-308	133-176	-	53-132	-	<53	-	-
Hct (%)	>60	-	50-59	46-49	30-45.9	-	20-29.9		<20
WBC	>40	-	20-39	15-19.9	3-14.9	-	1-2.9		<1
HCO_3	>52	41-51.9	-	32-40.9	22-31.9	-	18-21.9	15-17.9	<15

FGSI > 9 = 75% mortality rate

FGSI ≤ 8 = 78% survival rate

Laor E et al. Outcome prediction in patients with Fournier's gangrene. Journal of Urology. 1995; 154: 89-92

Patient A

- **WBC** **21.08** +2
- Hb 11.7
- **Hct (%)** **33.2** +0
- Plt 207

- PT 15.4
- aPTT 41.6

- pH 7.19
- pO_2 28.4
- pCO_2 6.3
- **HCO_3** **18** +2

- **Na** **137** +0
- **K** **4.0** +0
- Urea 18.3
- **Cr** **410** +4
- AST 36
- ALT 39
- Albumin 29

- **Temp** **36** +0
- **HR** **133** +2
- **RR** **16** +0

FGSI = 10

Fournier's Gangrene Severity Index

- Over the years, most studies have validated the FGSI as a valuable prognostic factors although some have suggested different cutoff values
- Useful in predicting survival but not length of hospital stay in a series of 19 patients

Chawla et al. Fournier's gangrene: an analysis of repeated surgical debridment. European urology 2003;43:572-5.

Fournier's Gangrene Severity Index

- In a retrospective study of 70 patients, FGSI was effective in predicting mortality (4.66 ± 2.31 in survivors VS 11.56 ± 2.68 in non-survivors)
- Predictive of length of hospitalization time and no. of debridements among survivors
- FGSI was lower in primary GU infection than primary anorectal infection

Ersay A et al. Factors affecting mortality of Fournier's gangrene: review of 70 patients. ANZ Journal of Surgery. 2007; 77:43-8

Other Prognostic Indicators?

- Colostomy
- Delay in presentation: >7 days
- Age >60
- Presence of systemic toxicity
- Extensive tissue involvement
- DM / Alcoholism

Conclusion

- Fournier's gangrene is a rapidly progressive, fulminant infection
- Prompt diagnosis
- Immediate surgical, urological and ICU consultation
- Radiological studies may be helpful
- Aggressive resuscitation, broad-spectrum antibiotics coverage and radical debridement
- Reconstructive surgery makes return to normal social life possible

References

- Eke, N. Fournier's gangrene: a review of 1726 cases. British Journal of Surgery. 2000; 87: 718-728
- Ersay, A et al. Factors affecting mortality of Fournier's gangrene: review of 70 patients. ANZ Journal of Surgery. 2007; 77:43-48
- Benizri E. et al. Gangrene of the perineum. Urology 1996; 47:935-9.
- Silva J et al. Fournier's gangrene: Ten year experience at a single institution. European Urology 2002 ;1 (suppl.):178
- Laor, E et al. Outcome prediction in patients with Fournier's gangrene. The Journal of Urology. 1995; 154: 89-92
- Chawla et al. Fournier's gangrene: an analysis of repeated surgical debridment. European urology 2003;43:572-5.
- Korkut, M et al. Outcome analysis in patients with Fournier's gangrene. Dis Colon Rectum. 2003; 46: 649-652
- Norton, K et al. Management of Fournier's gangrene: an eleven year retrospective analysis of early recognition, diagnosis, and treatment. The American Surgeon. 2002; 68: 709-713
- Yanar, H et al. Fournier's gangrene: risk factors and strategies for management. World Journal of Surgery. 2006; 30: 1750-1754
- Verit, A et al. Fournier's gangrene: the development of a classical pathology. BJU International. 2007; 1218-1220
- Basoglu, M et al. Management of Fournier's gangrene: review of 45 cases. Surgery Today. 2007; 37: 558-563
- Ferreira et al. Fournier's gangrene: a review of 43 reconstructive cases. Plastic and Reconstructive Surgery January 2007;119(1):175-84.
- Hefny, A et al. Necrotizing fasciitis: a challenging diagnosis. European Journal of Emergency Medicine. 2007; 14: 50-52
- Morrison, D et al Emergency diagnosis of Fournier's gangrene with bedside ultrasound. The American Journal of Emergency Medicine. 2005; 23: 544-547
- Kane, C et al Ultrasonographic appearance of necrotizing gangrene: aid in early diagnosis. Urology. 1996; 48: 142-144
- Piedra et al. Fournier's gangrene: a radiologic emergency. Abdominal imaging 2006;31:500-2.