Acute Ophthalmology for A&E Practice

Dr. LEUNG Yu-lung, Dexter

MBChB, BMedSci(Hons),FRCS (Glas),MRCS(Edin), DRCOphth(London),FCOphthHK, FHKAM(Ophth)

Associate Consultant
Clinical Assistant Professor (Honorary)
Deputy Chief, Glaucoma Service
Department of Ophthalmology & Visual Sciences
The Chinese University of Hong Kong
Hong Kong Eye Hospital

3 Dec 2008

Acknowledgment

HK College of Emergency Medicine

Dr. HO Hui-fai

Dr. Tommy Chan

One of the key to make it easy is to… …

Recognise the *NORMAL…*

Vs. ABNORMAL

With these in mind, Outline of Talk as follows:

1. Normality & Special Points in Ophthalmic P/E and Imaging
2. ***Pattern Recognition– Clinical Slide Show***
3. Question and Answer Session


What is **Normal**?

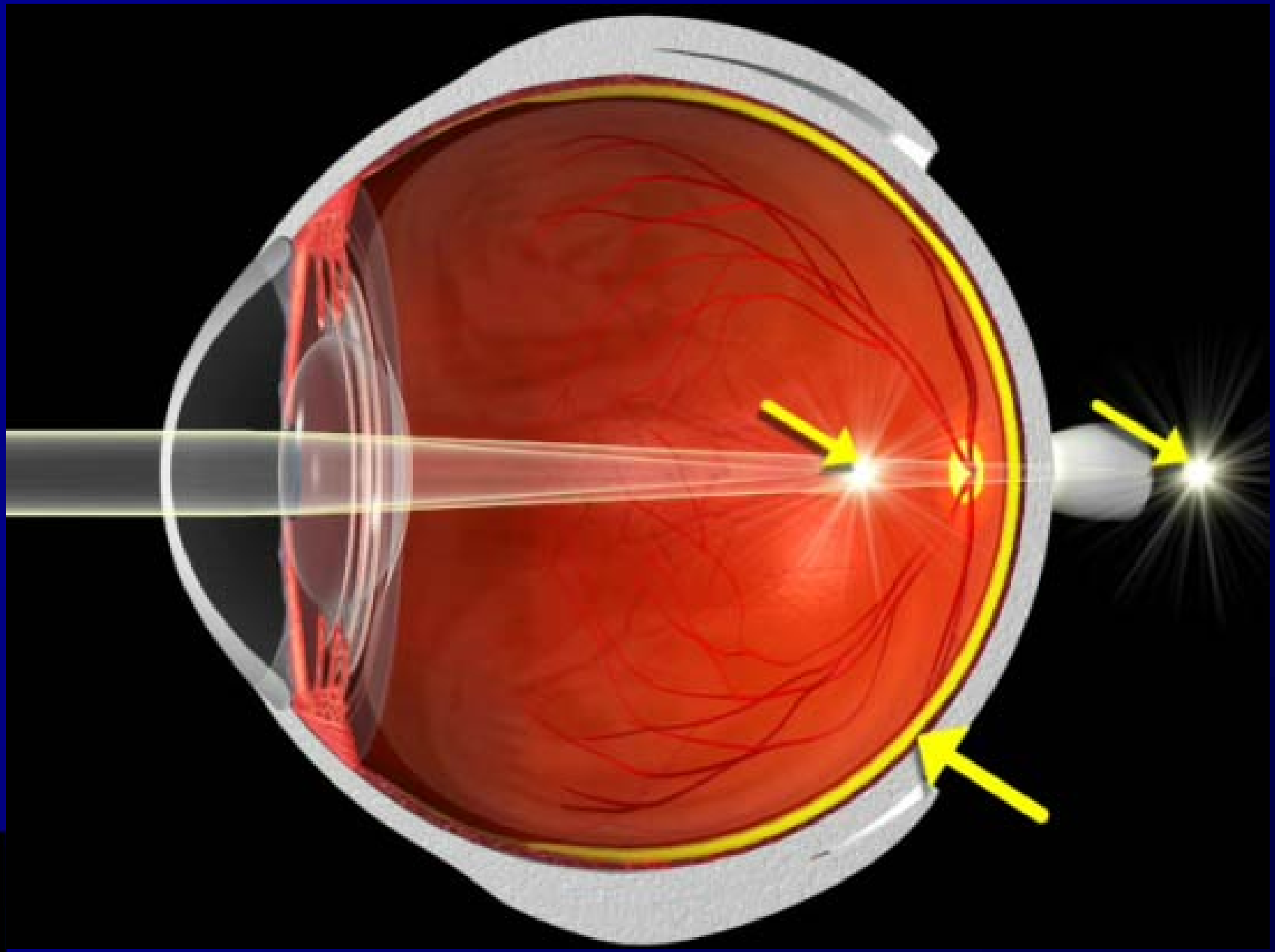

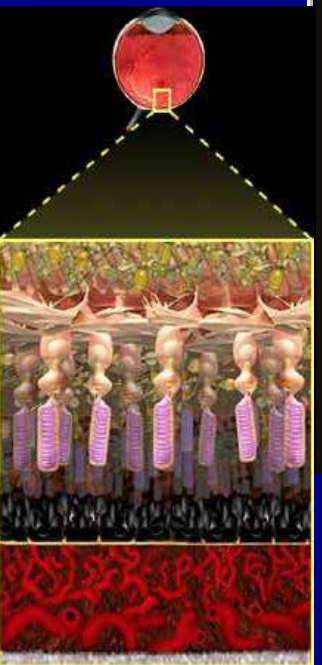

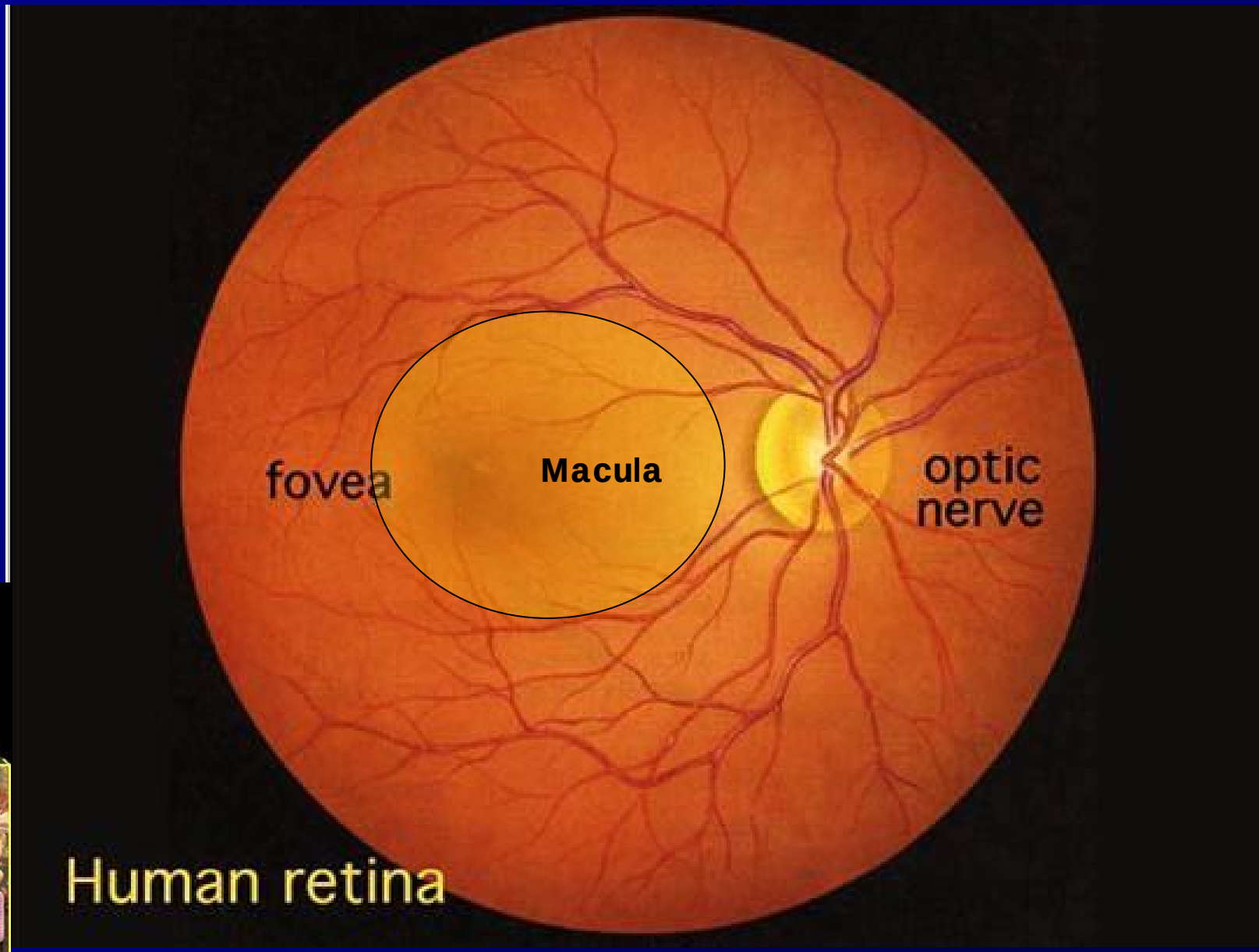
fovea
Macula
optic
nerve
Human retina

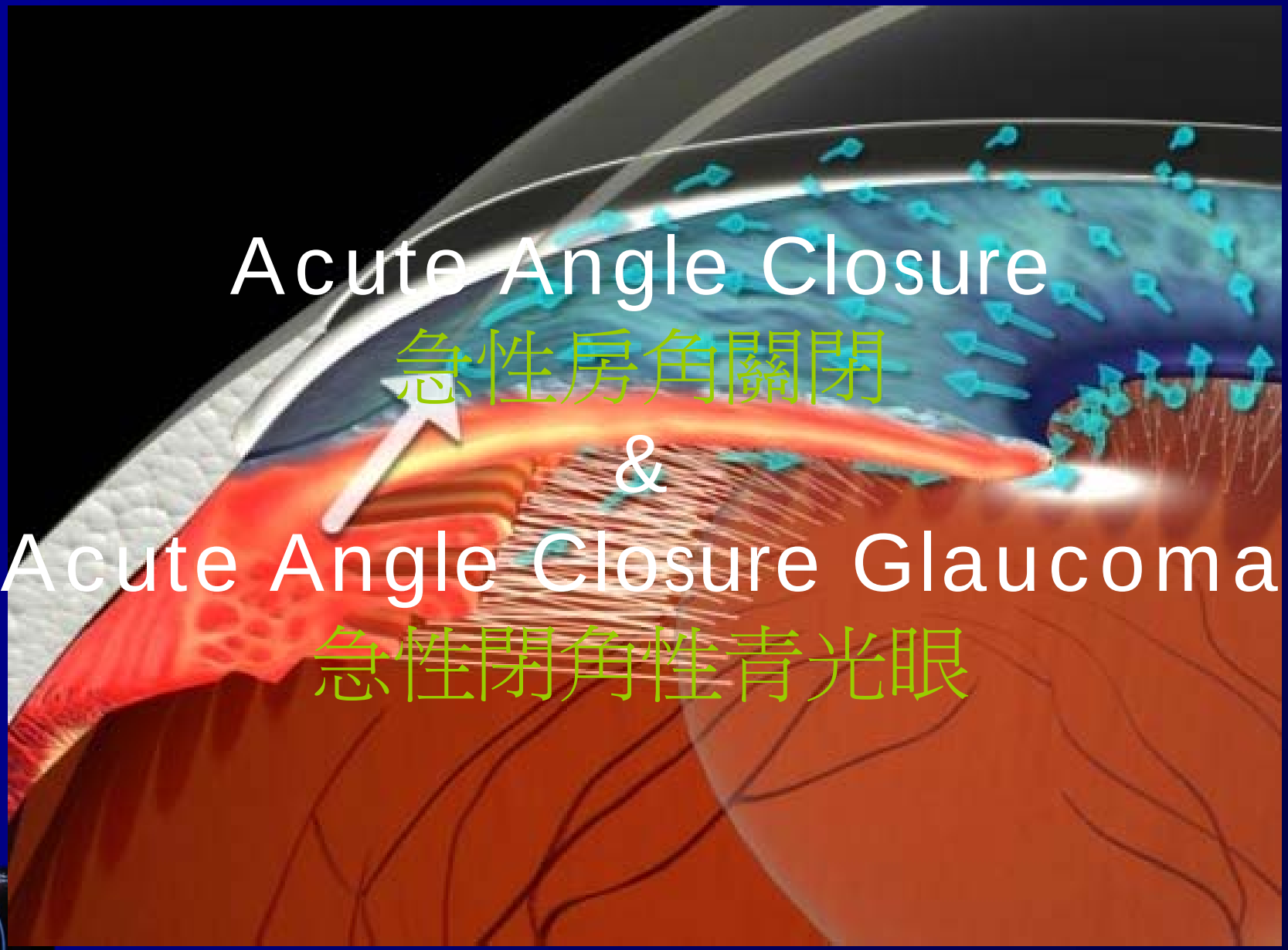

Acute Angle Closure
急性房角關閉
&
Acute Angle Closure Glaucoma
急性閉角性青光眼

Important: **Examine as many normal** eyes as you can, with Slit lamp and direct ophthalmoscopy with dilated pupils!

No slit lamp? **Magnifying glass + bright torch** will do!

Approach to Ocular Abnormality

- Time honored:
  - Careful History
  - Thorough Physical Examination
  - Logical appropriate investigation

- Importance of **Pattern Recognition** in Ophthalmology (esp. signs)

Physical Examination

- The **5 pillars** for most if not all of cases:
  - **1. Snellen VA at correct distance with refractive correction + Pinhole**
  - **2. Pupils and Ocular movements**
  - **3. IOP (Applanation, TonoPen, Airpuff, Digital!)**
  - **4. Slit lamp/ Magnifying glass exam**
  - **5. Dilated fundus exam**

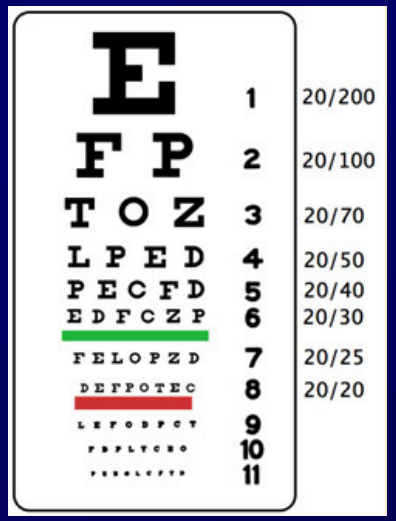

Paediatric Physical Examination

- Make a game of the exam.
- CSM Method
  - Central: Alignment, Light torch exam
  - Steady: No nystagmus
  - Maintain: at an object/ face
- By 6 weeks– fixate with some smooth pursuit
- By 10-12 weeks– fixate with accurate smooth pursuit (fix & follow)

Issues in XRays

- 5 views:
  - Caldwell: sup and lat orbtial rims, medial orbital wall, ethmoid and frontal sinuses
  - Waters: Best for blow-out orbital fractures of floor and roof
  - Submental Vertex: Sphenoid and ethmoid sinuses, NP, zygomatic arch
  - R & L oblique views: optic foramina. Diameter > 6.5 mm in > 6 years of age and asymmetry > 1 mm may be abnormal

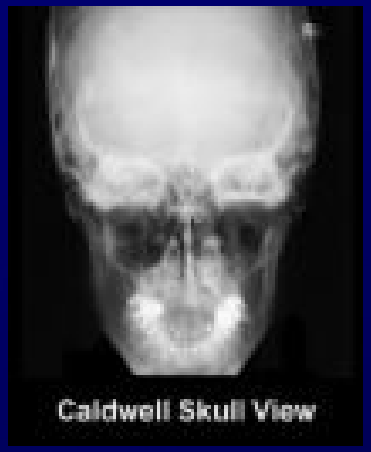

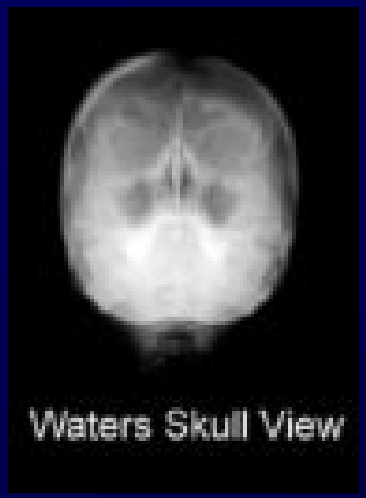

Issues in CT Orbit

Important to obtain both **coronal and axial** scans—

1. Essential to localize Intraocular FBs
2. Essential in assessment for orbital fractures (muscle entrapment, basal surface areas, etc)

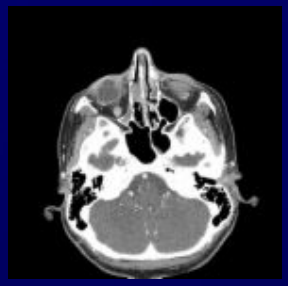

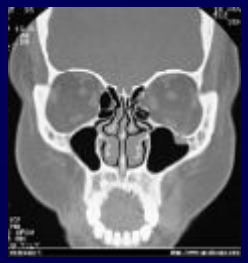

Clinical Slide Show…

1. Full thickness, involve lid margin, upper lid levator

2. Involve punctum or canaliculus

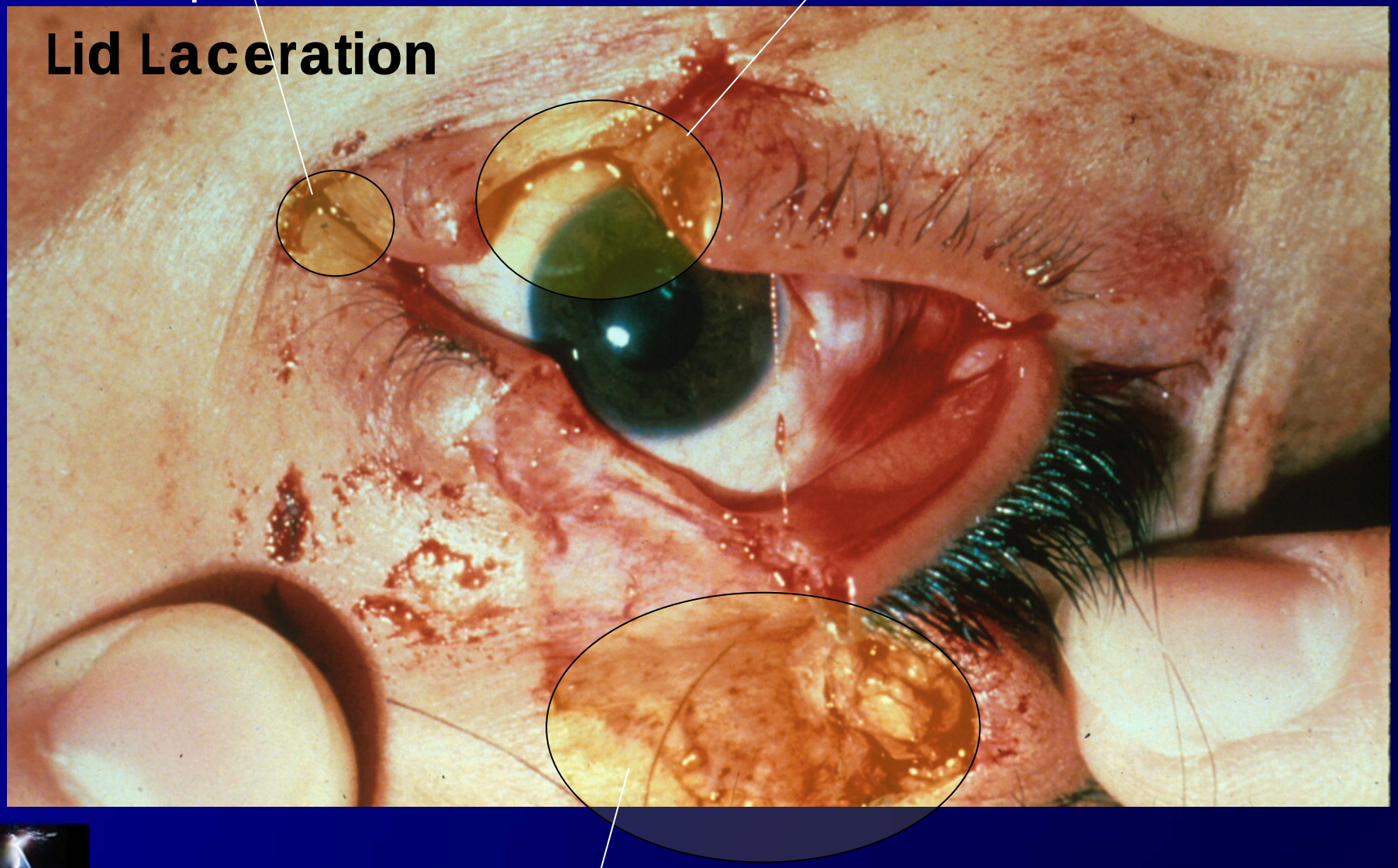

3. Significant tissue loss

Management

ALWAYS rule out

(1)a ruptured globe

(2)retrobulbar hemorrhage with compartmental Sx

(3)FB

in these cases -- perform a complete ophthalmic exams!!

Management

1. Assessment –NATURE of trauma, extent, associated injuries
2. Antibiotic prophylaxis: topical +/- systemic--if wound is not clean/ complicated laceration
3. Tetanus prophylaxis
4. Rabies prophylaxis if indicated
5. Adequate wound irrigation & cleansing with FB removal
6. LA– beware of globe penetration
7. Tarsus– 6-O Vicryl; Skin- 8-O Silk
8. +/- Ice pack first 24-48 hrs

Orbital Blow-out fracture

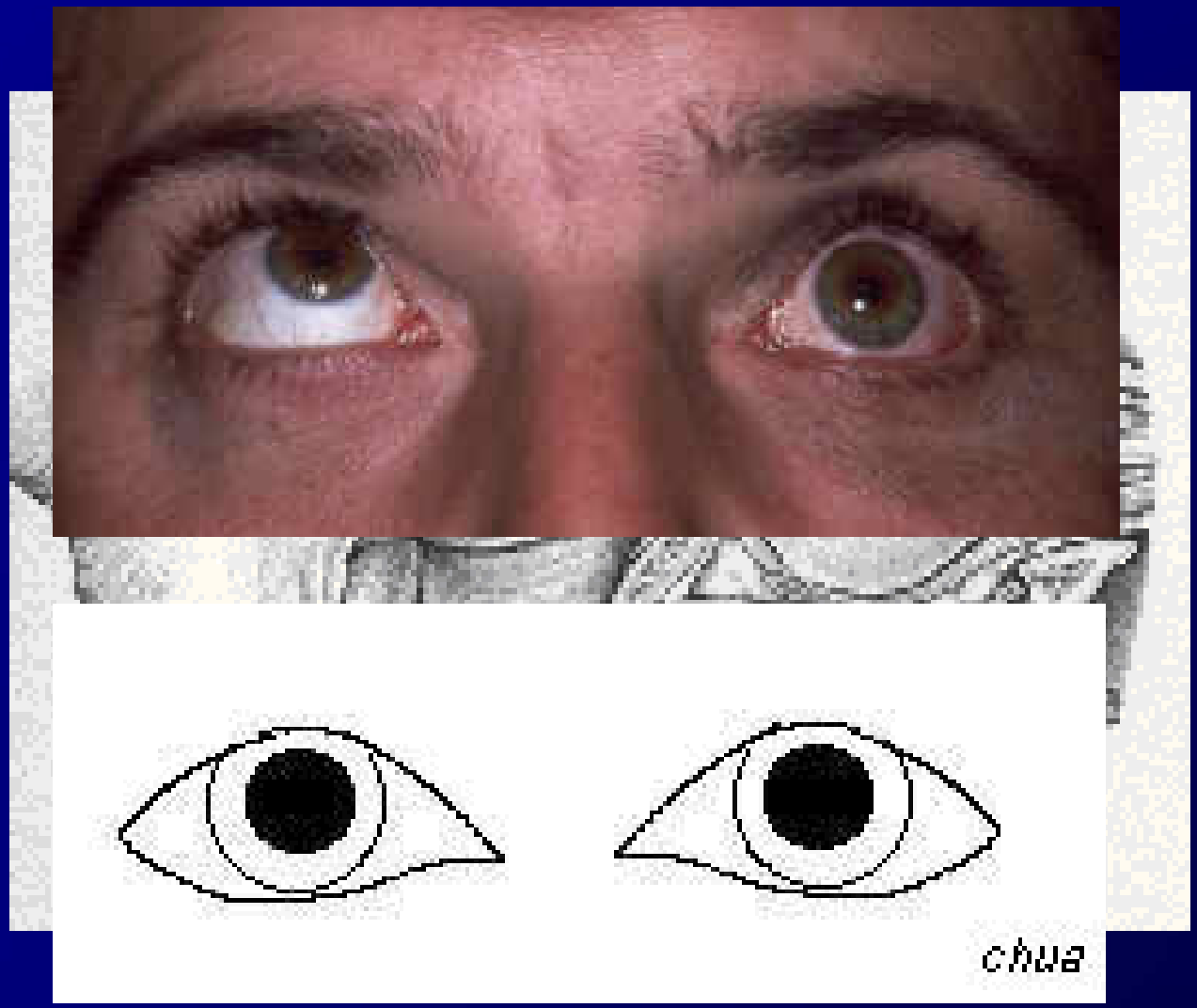

Orbital Blow-out fracture: Waters View

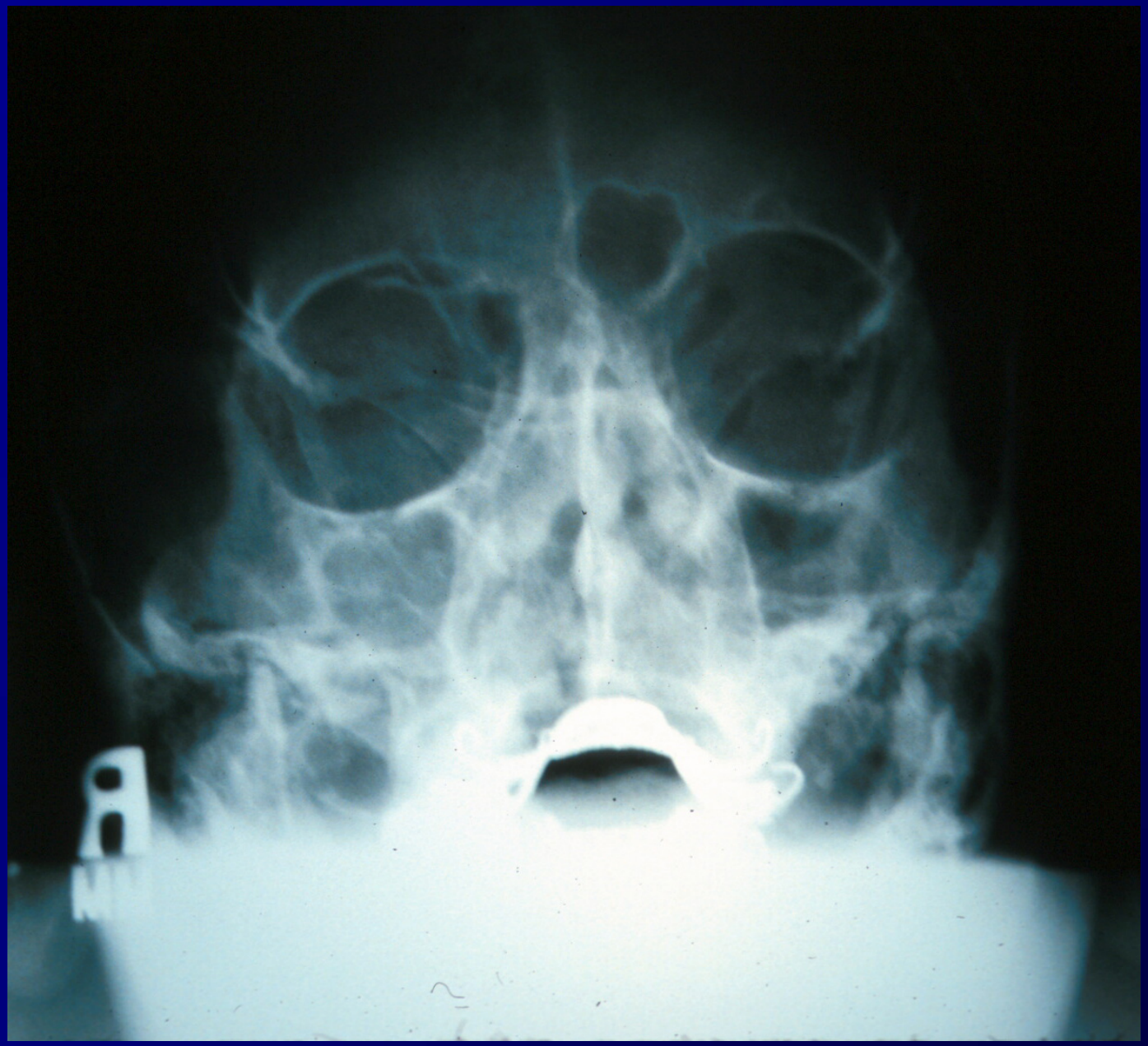

Orbital Blow-out fracture

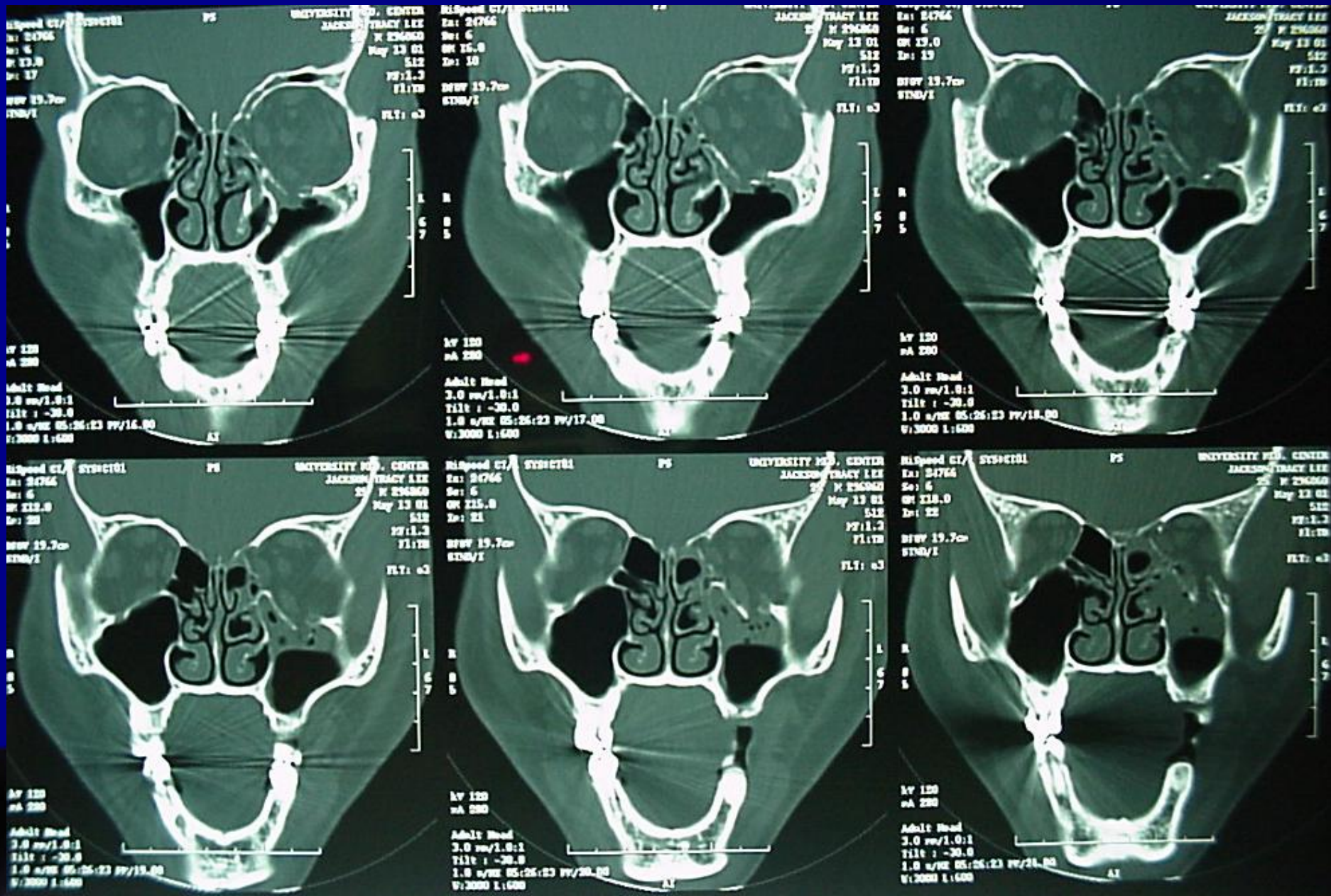

Management

1. Assessment –NATURE of trauma, extent, associated injuries
2. No blow nose
3. +/- Nasal decongestant spray bd for first 10 days
4. Ice pack first 24-48 hrs
5. Immediate surgery → if trapdoor injury of muscle, large fracture surface area– vs. delayed repair → if persistent diplopia in primary and down gaze, significant enophthalmos > 2mm. For young esp. children→ EARLY repair

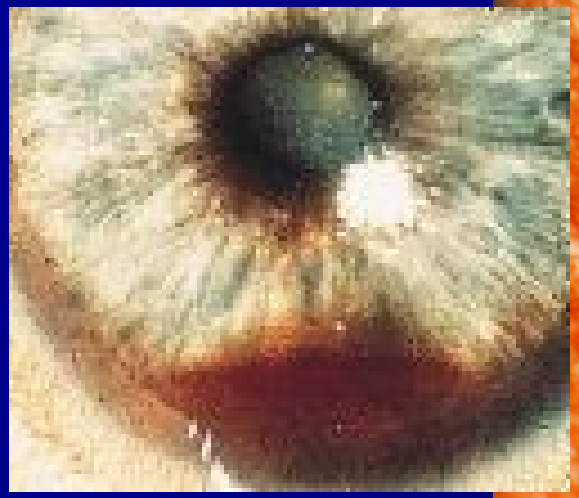

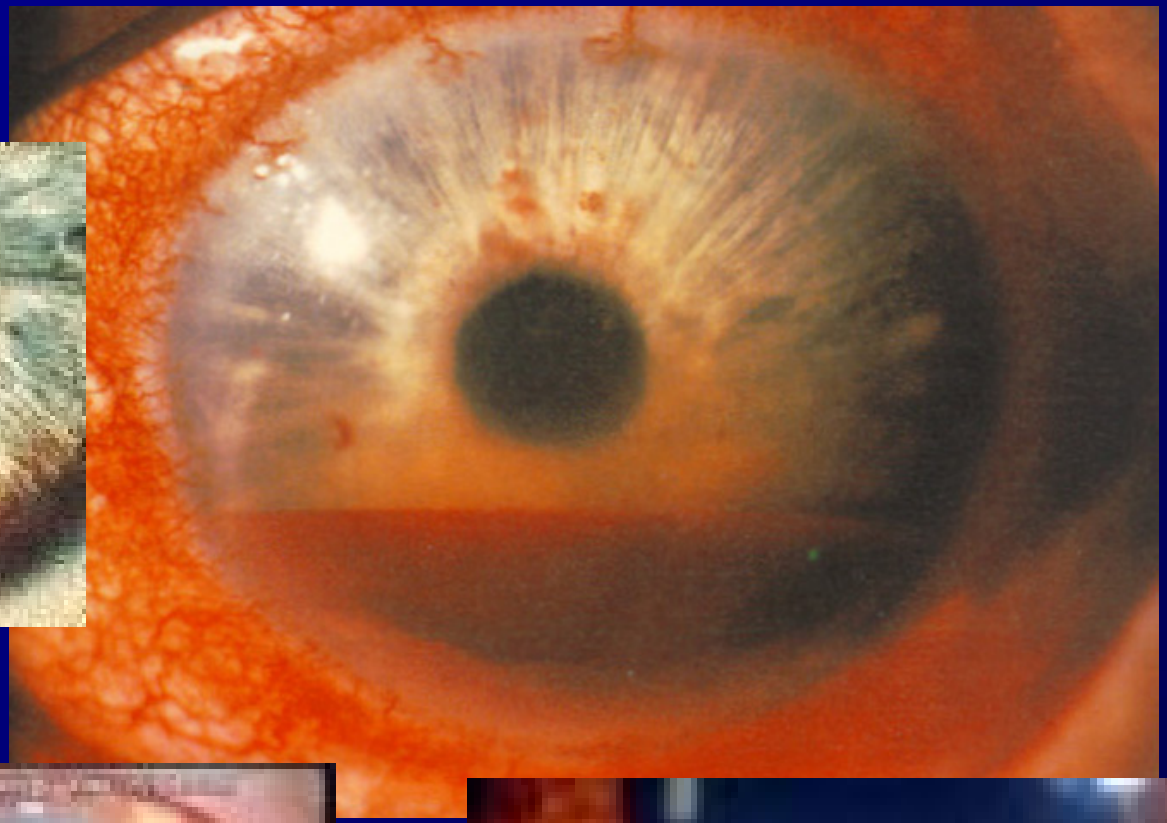

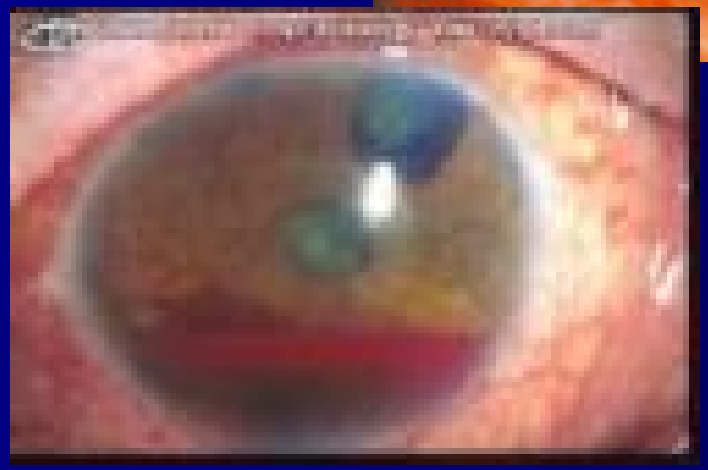

Traumatic Hyphema

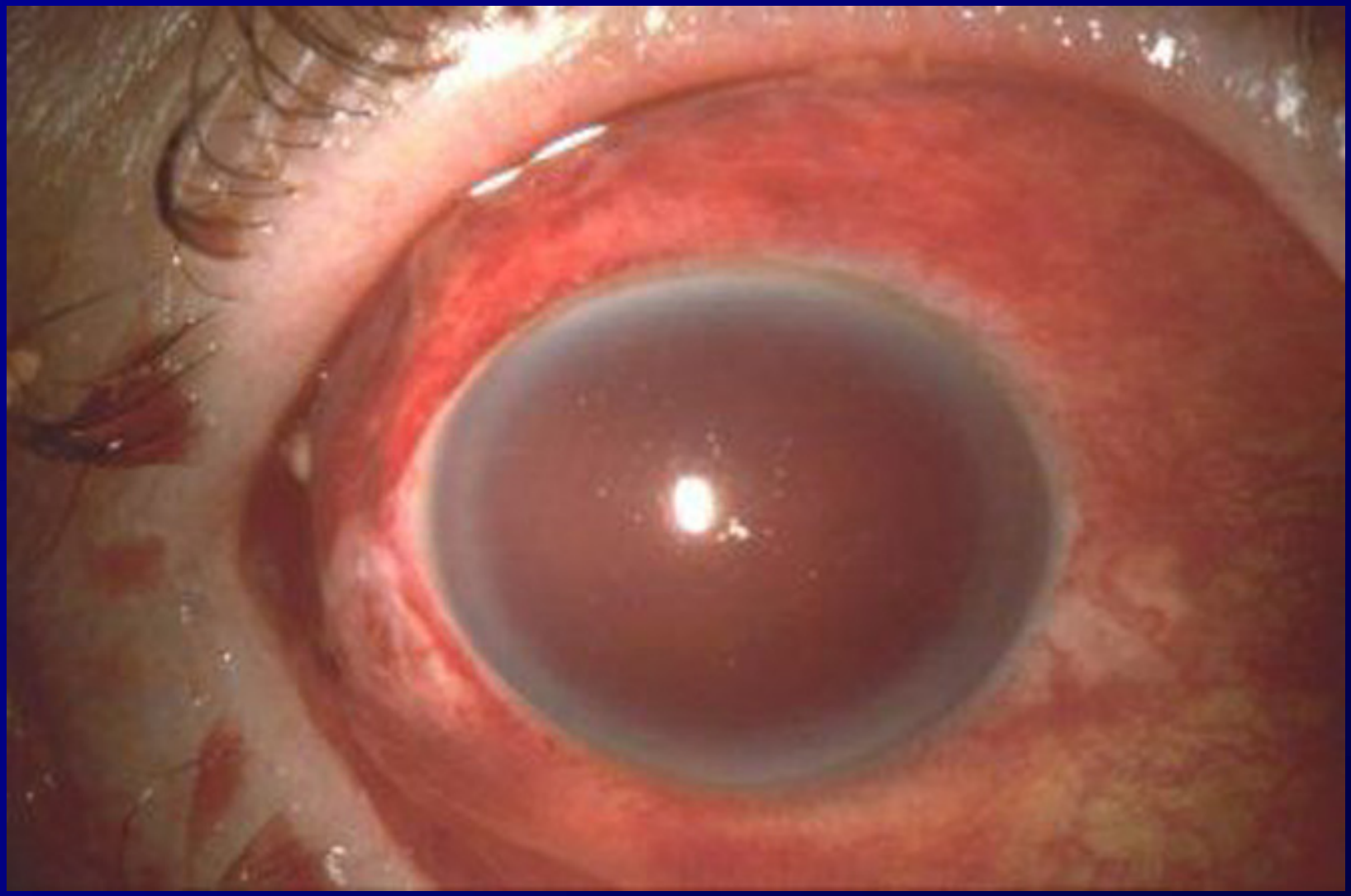

Traumatic Hyphema – 8-ball Hyphema

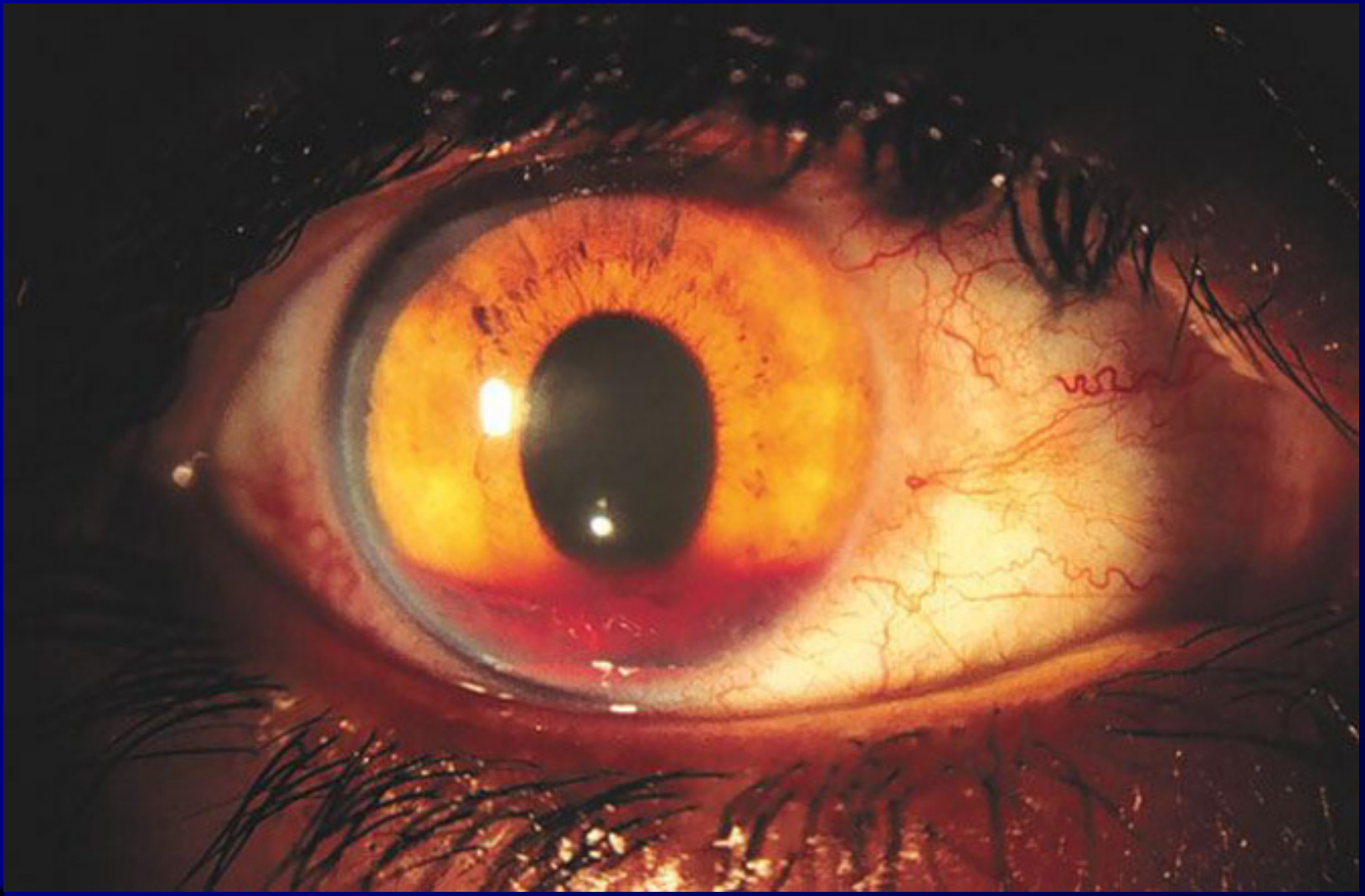

Always look for occult rupture as pupil is not round!

Management-Minimize rebleed & Cx such as IOP rise

1. Assessment –NATURE of trauma, extent, associated injuries
2. Bed Rest with Head up
3. Eye shield
4. Consider stopping Aspirin
5. Topical steroid (gutt. Pred forte qid to q2h +/- topical antibiotics +/- cycloplegics (pros & cons– gutt. 4% homatropine bd)
6. +/- topical glaucoma meds
7. +/- Aminocaproic acid (antifibrinolytic) 50mg/kg q4h for 5 days, reduces incidence of rebleeds in prospective clinical trials.
8. Beware of sickling Cx in African American
9. Surgical: Paracentesis, AC Washout if indicated according to guidelines.

OPEN GLOBE!

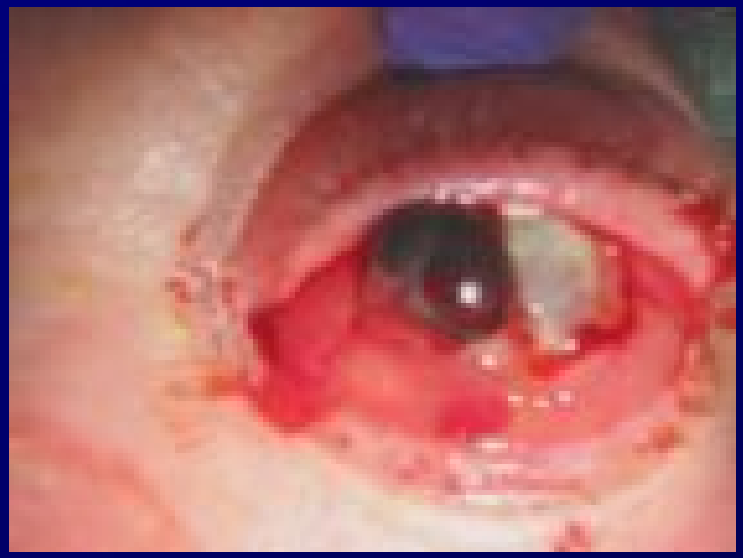

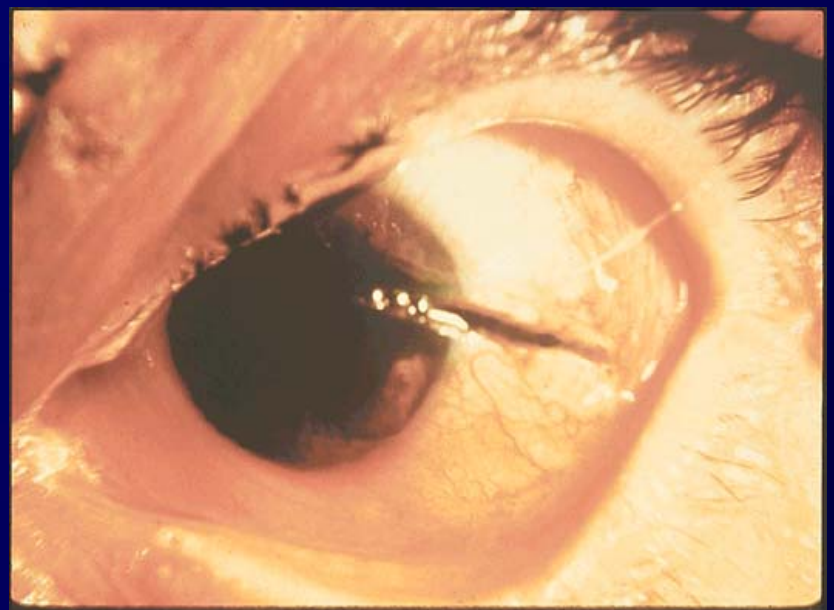

Management-Minimize further derangement of Anatomy

1. Assessment –NATURE of trauma, extent, associated injuries
2. Consider use bent paper clip instead of fingers for exam
3. Once Diagnosis certain, no further exam till by Ophthalmologist
4. Eye shield & Bed Rest
5. NPO
6. Pain management
7. Vomit management
8. Tetanus
9. Prophylactic IV broad-spectrum antibiotics
10. Await Ophthalmologist assessment

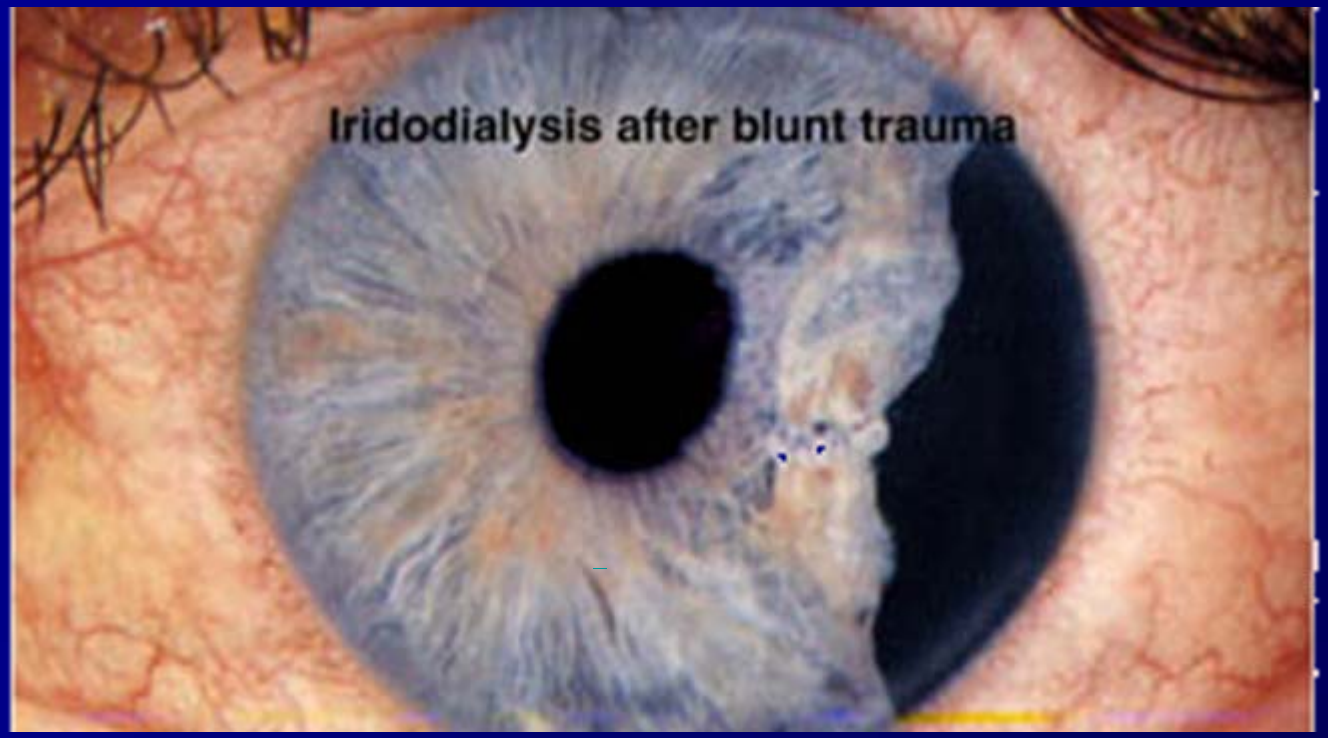
Iridodialysis after blunt trauma

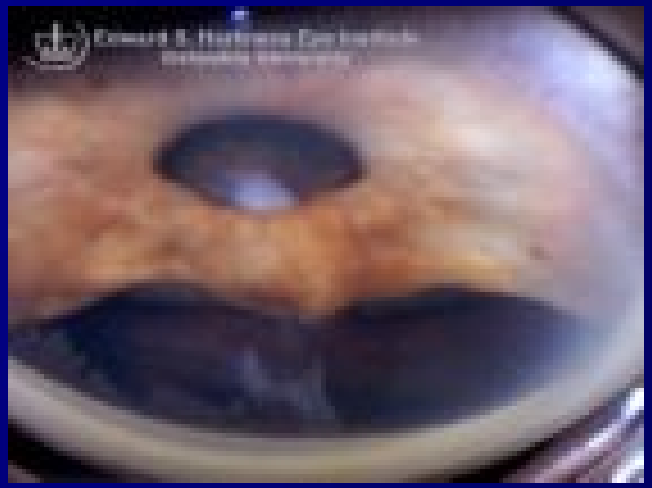

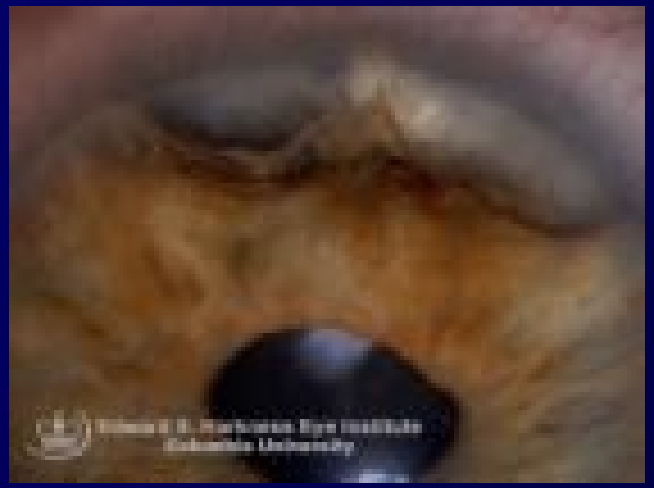

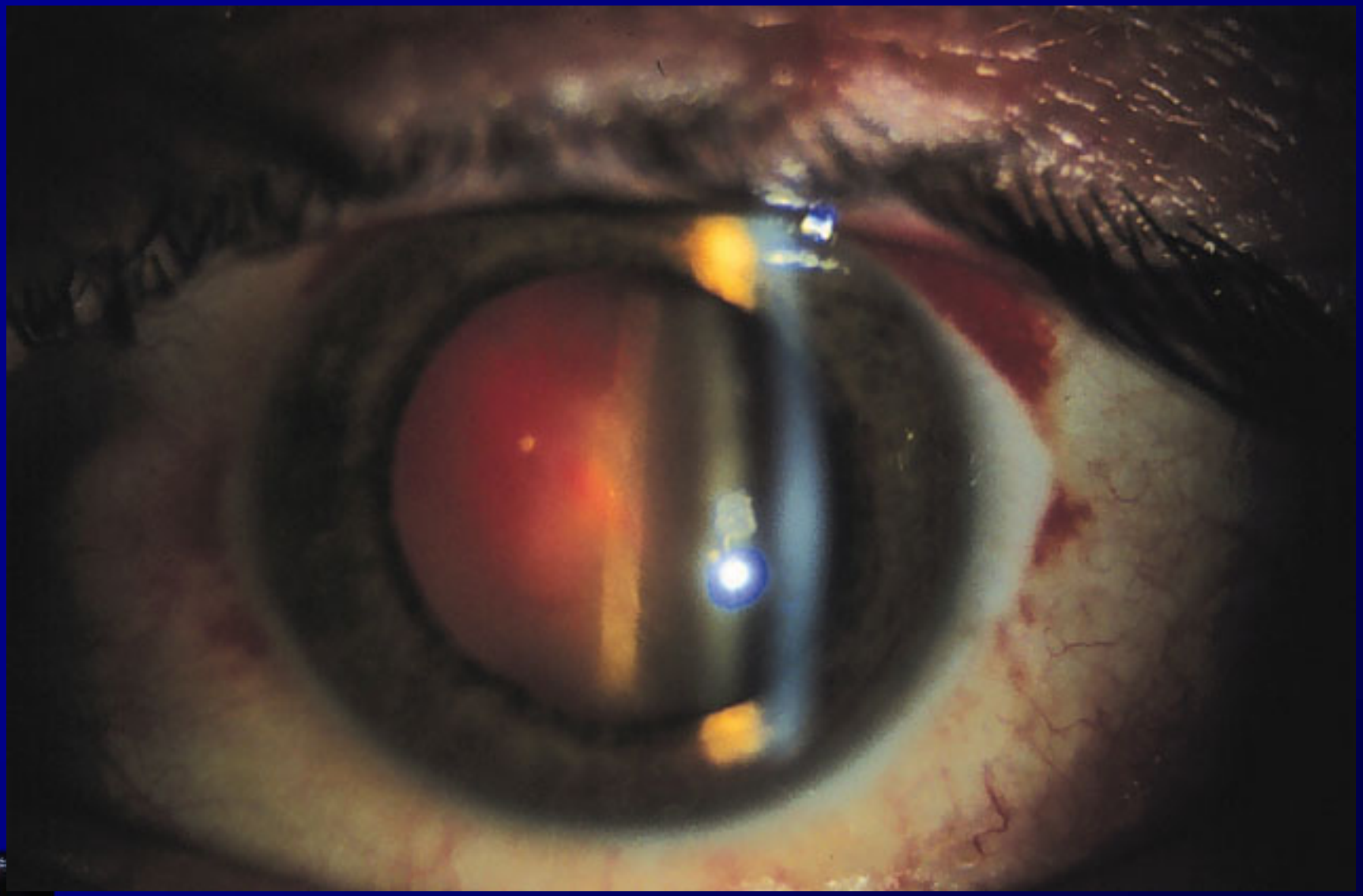

Post-trauma ---Vitreous Hemorrhage

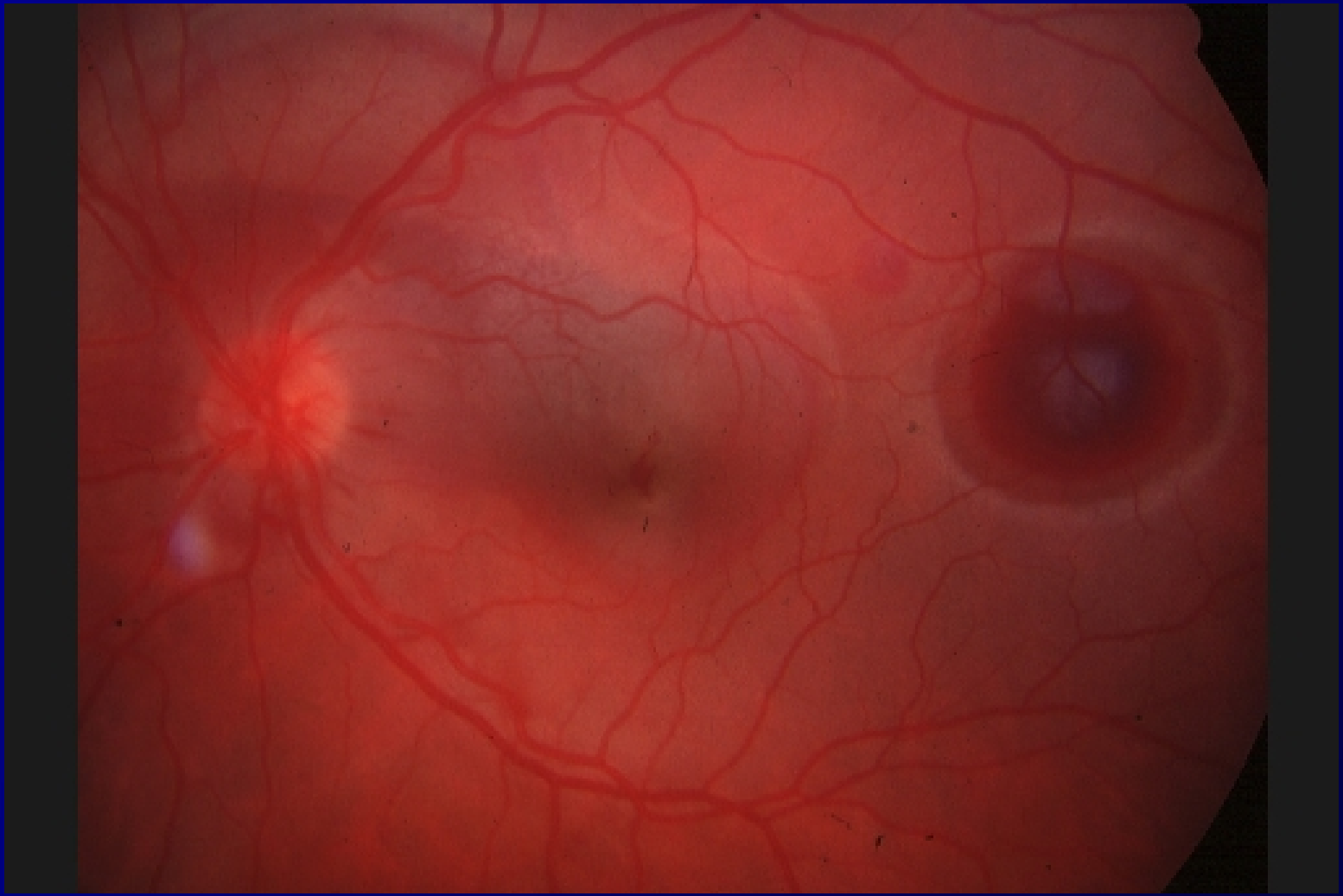

Post-trauma– Retinal hemorrhage and Pigment epithelial detachment

Simple Subconjunctival Hemorrhage

VA= 3/60 VA w gls = 6/6 IOP = 12 mmHg BP = normal

Rx: Nil after BP +/- coagulation assessment; OR +/- topical lubricants

RED EYE

Red Eye– 4 big causes!

- Acute Glaucoma!
- Conjunctivitis/ Keratitis
- Uveitis → may also cause glaucoma
- Allergies

Simple Viral Conjuncivitis

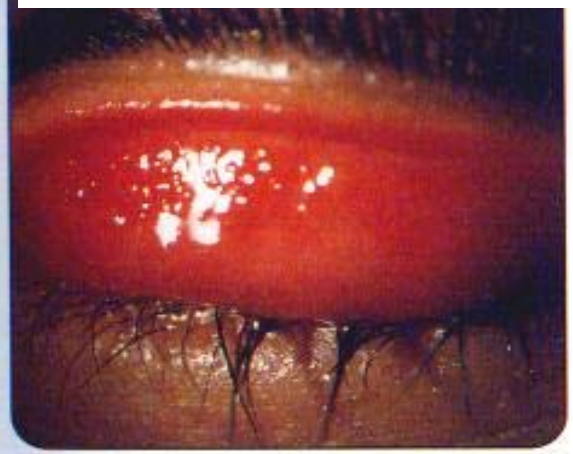

Fig. 3.5

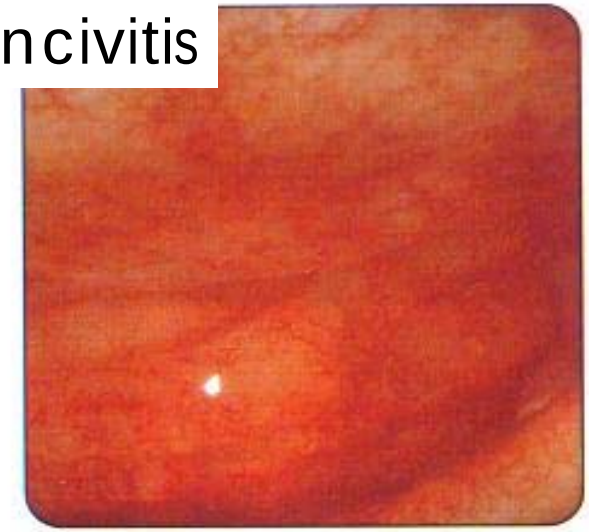

Fig. 3.6

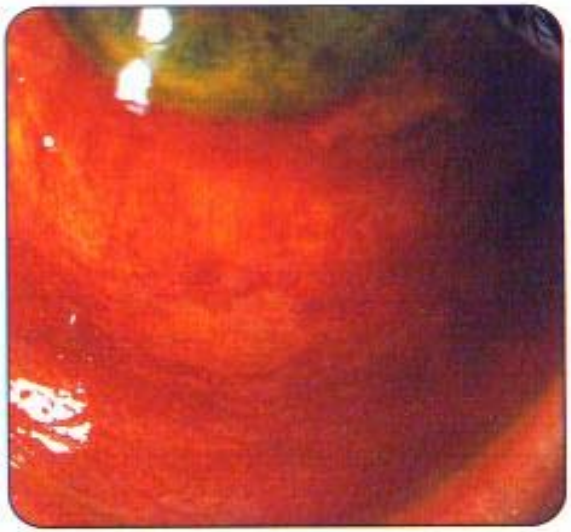

Fig. 3.7

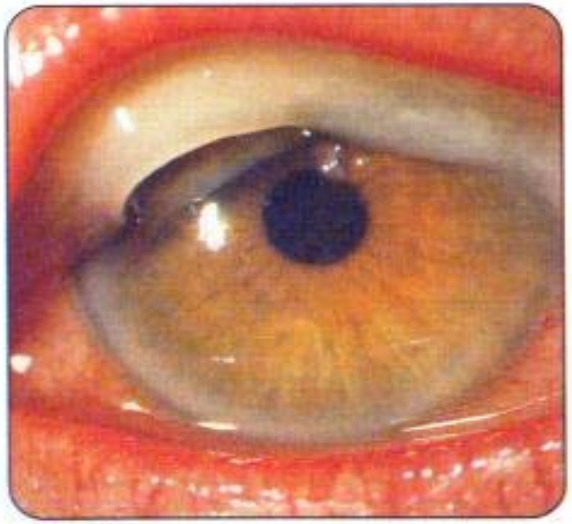

Fig. 3.8

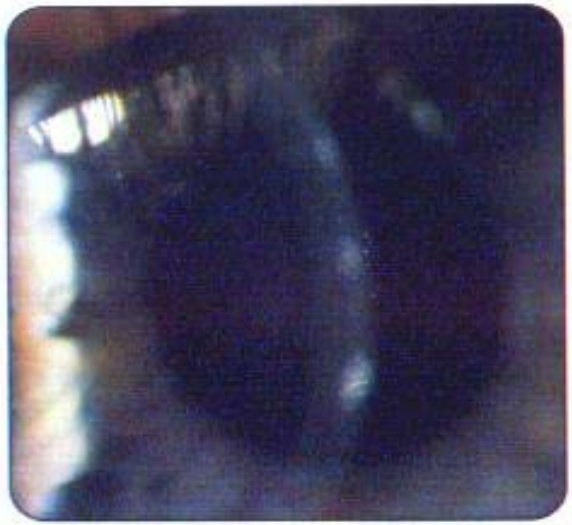

Fig. 3.9

VA = 6/12 pH 6/9 IOP = 14 mmHg

Simple Viral Conjuncivitis

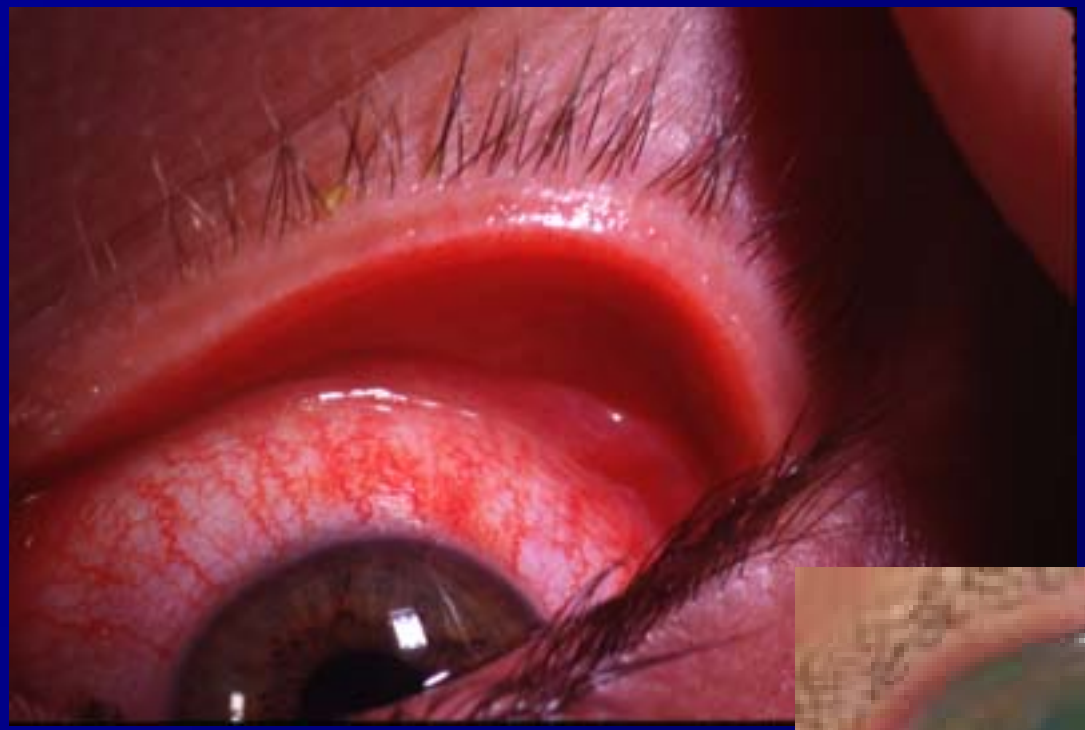

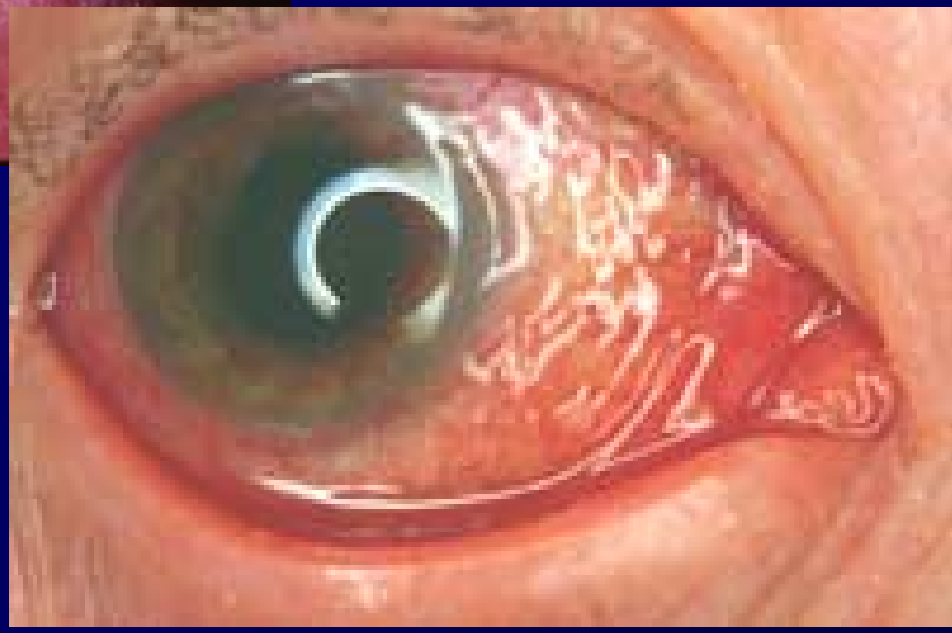

Always examine the upper fornix!

Management

1. Wash your hands and instruments afterwards!!
2. Consider C/ST if looks atypical
3. Supportive Rx: Cool compression, topical lubricants, Pain management
4. Red Eye education & Hygiene
5. ?Use of topical antibiotics and astringents
6. Treat corneal subepithelial infiltrate with mild topical steroid (by ophthalmologist)
7. **What do you tell your patient?**

Episcleritis!

Rx: NSAID +/- Topical steroid

Episcleritis-- nodular