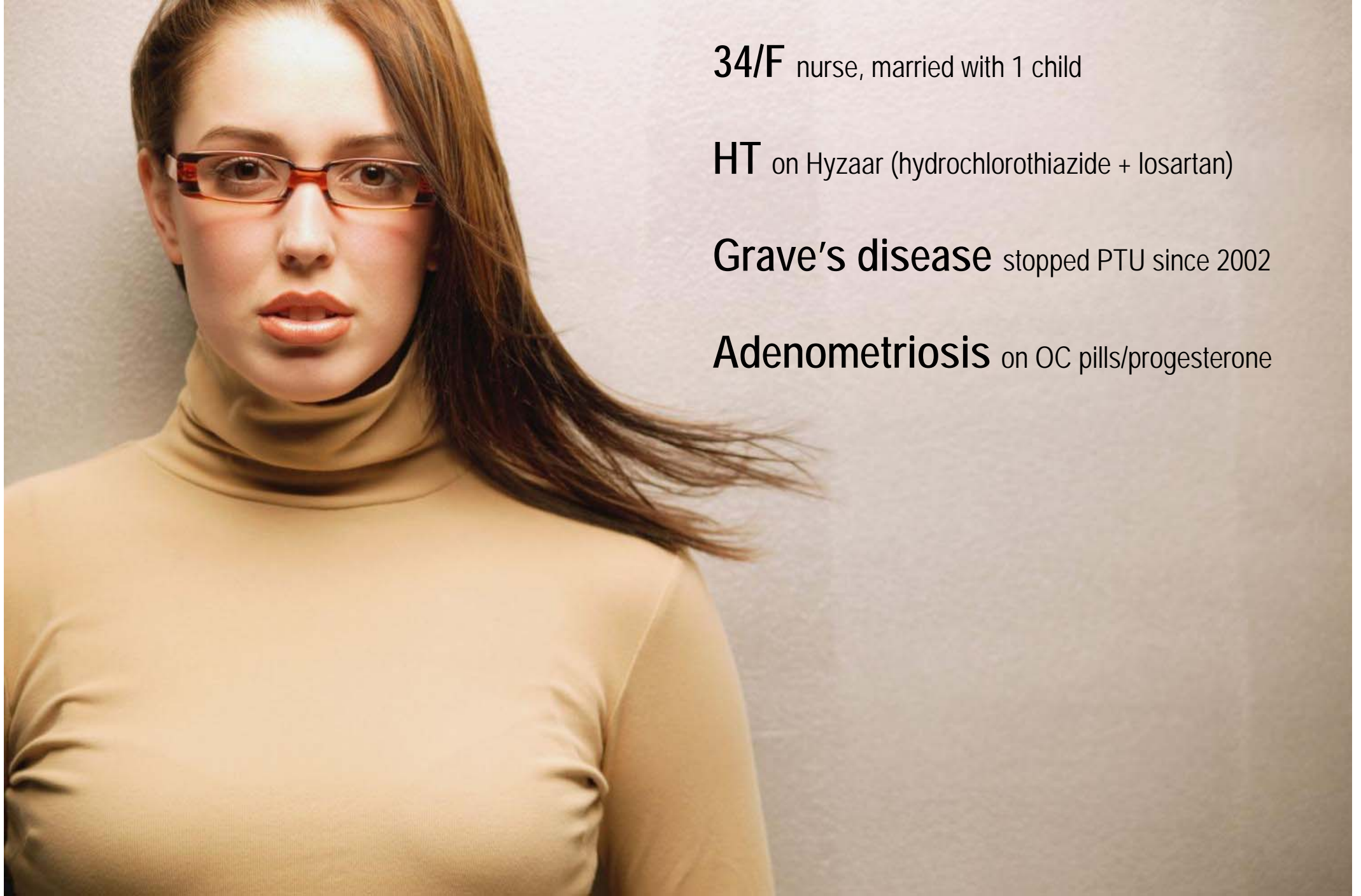



# **CASE PRESENTATION** JULY 2010

Dr. LAM, Shu-Chun YCH



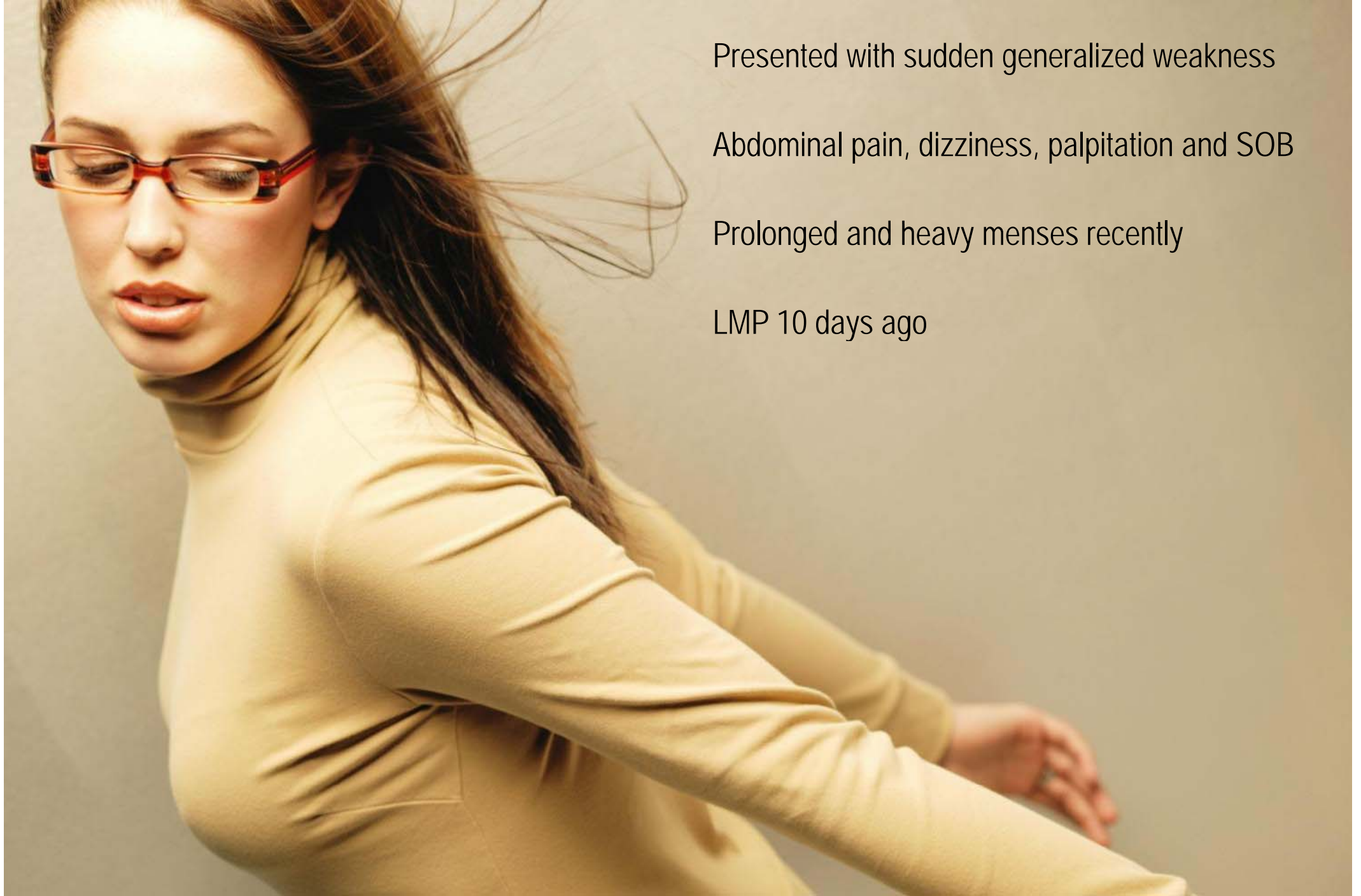**34/F** nurse, married with 1 child

**HT** on Hyzaar (hydrochlorothiazide + losartan)

**Grave's disease** stopped PTU since 2002

**Adenometriosis** on OC pills/progesterone

# HISTORY



Presented with sudden generalized weakness

Abdominal pain, dizziness, palpitation and SOB

Prolonged and heavy menses recently

LMP 10 days ago

# HISTORY



E3V5M6, drowsy

BP not measurable

Very weak pulses, 120 bpm

SpO<sub>2</sub> 95% on 100% O<sub>2</sub>

Temperature 36.7C

Spot h'stix 9.7 mmol/L

Lower abdominal tenderness,  
PR yellowish stool

# EXAMINATION





NEXT

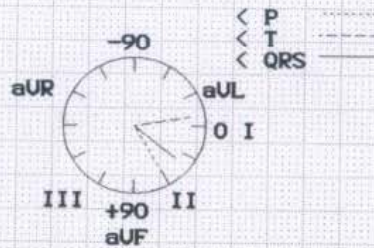
DISCUSSION



HR 115bpm

Measurement Results:

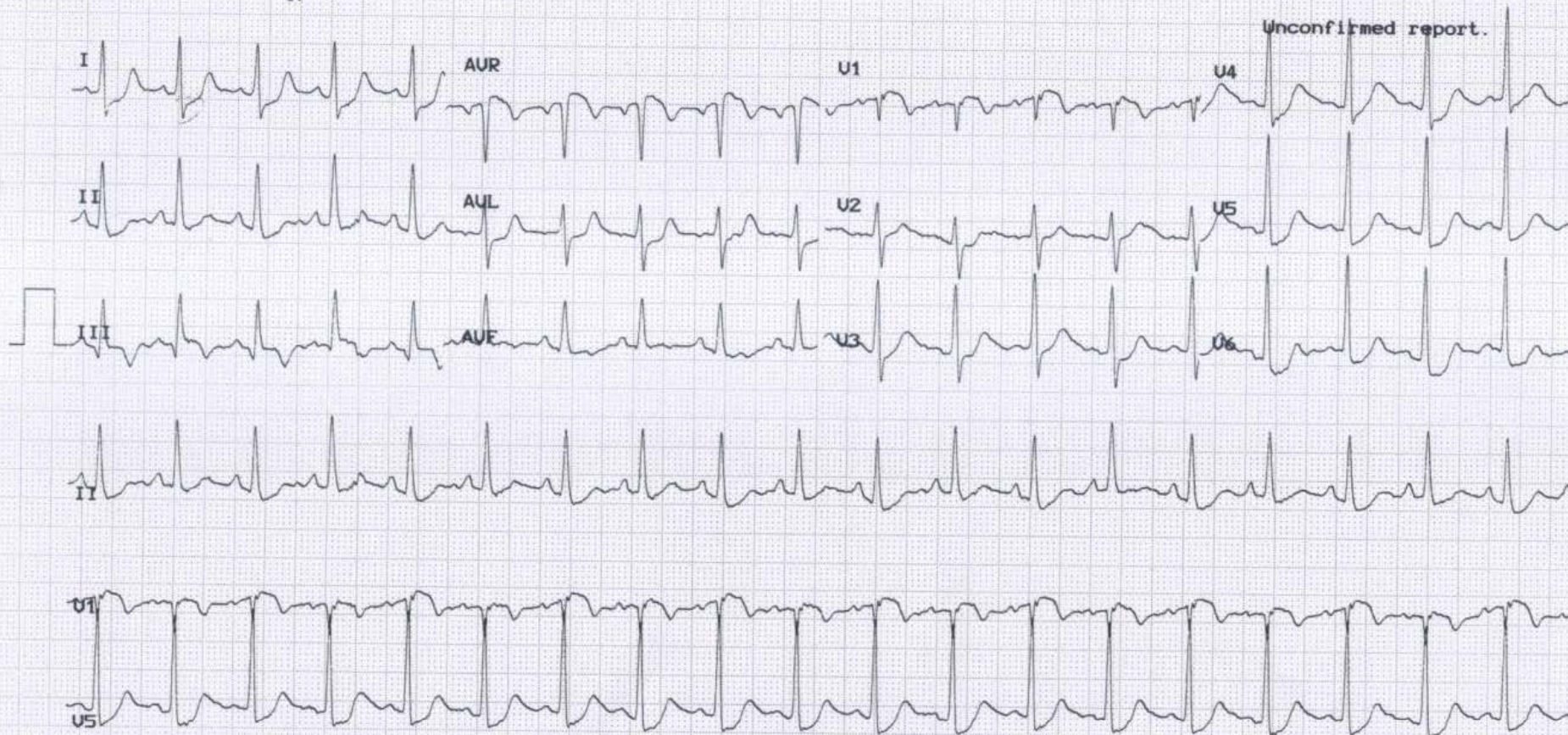
QRS : 88 ms  
 QT/QTcB : 324 / 451 ms  
 PR : 122 ms  
 P : 90 ms  
 RR/PP : 516 / 510 ms  
 P/QRS/T : 60/ 40/ -10 degrees  
 QTD/QTcBD : 90 / 125 ms  
 Sokolow : mV  
 NK : 17



Interpretation:

probably MI (inferior)  
 sinus tachycardia  
 negative T-wave (inferior)  
 probably abnormal ECG

Unconfirmed report.



24. Feb. 2010 07:38:55

25mm/s

10mm/mV

ADS

50Hz

0.08 - 40Hz

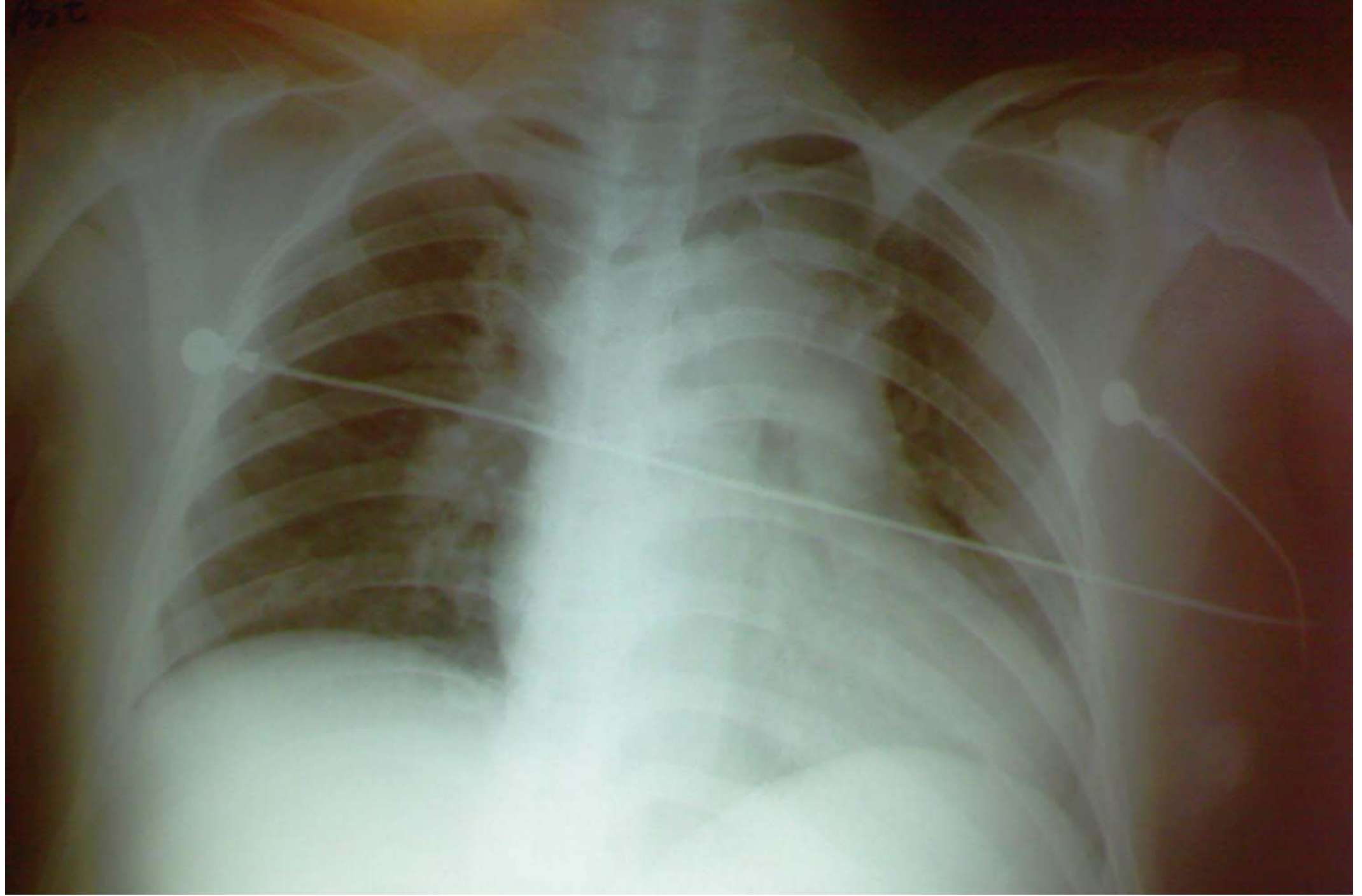
4x2.5R3

Automatic

U5.21 121 (1)

ECG





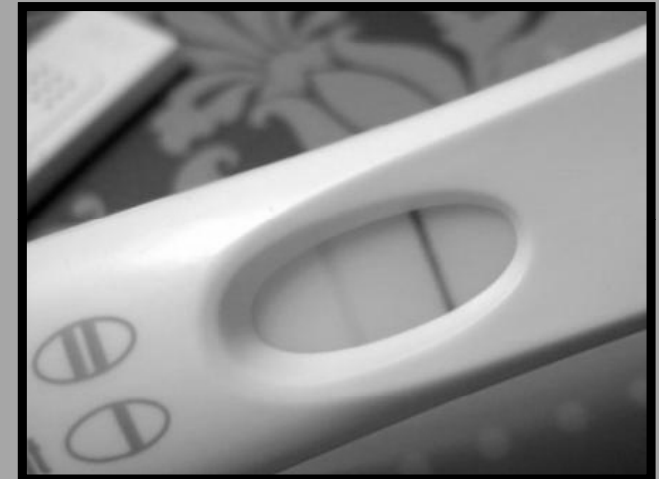CXR

### COMPLETE BLOOD COUNT

WBC	11.1 H	$\times 10^9/L$	4.0 - 10.0
RBC	3.29 L	$\times 10^{12}/L$	3.8 - 4.8
HGB	10.5 L	g/dL	12.0 - 15.0
HCT	0.298 L	L/L	0.360-0.460
MCV	90.5	fL	81.0 - 98.0
MCH	31.9	pg	27.0 - 34.0
MCHC	35.2	g/dL	31.5 - 36.5
RDW	11.6	%	11.0 - 15.0
PLT	127 L	$\times 10^9/L$	150 - 400
MPV	7.4	fL	7.0 - 10.0

Troponin & Pregnancy test

Sodium	142	# mmol/L	136 - 144
Potassium	3.2 L	# mmol/L	3.3 - 4.6
Urea	7.2 H	# mmol/L	2.4 - 6.5
Creatinine	124 H	# umol/L	39 - 76
Total Protein	47 L	# g/L	64 - 81
Albumin	18 L	# g/L	37 - 47
Globulin	29	# g/L	25 - 39
Total Bilirubin	10	# umol/L	6 - 26
ALP	41 L	# U/L	42 - 98
ALT	83 H	* U/L	< 35
Creatine Kinase	44	# U/L	39 - 206
Amylase	34 L	* U/L	38 - 135



**NEGATIVE!**

pH	7.24 L	*	7.35 - 7.45
pCO2	4.83	* Kpa	4.7 - 6.0
pO2	26.84 H	* Kpa	10.0 - 13.3
* The reference ranges are for adults only.			
Bicarbonate	15.0 L	* mmol/L	22.0 - 26.0
Base Excess	-12.5 L	* mmol/L	+/- 2.0
* The reference ranges are for adults only.			
O2 Saturation	99.5	%	

# BLOOD TEST



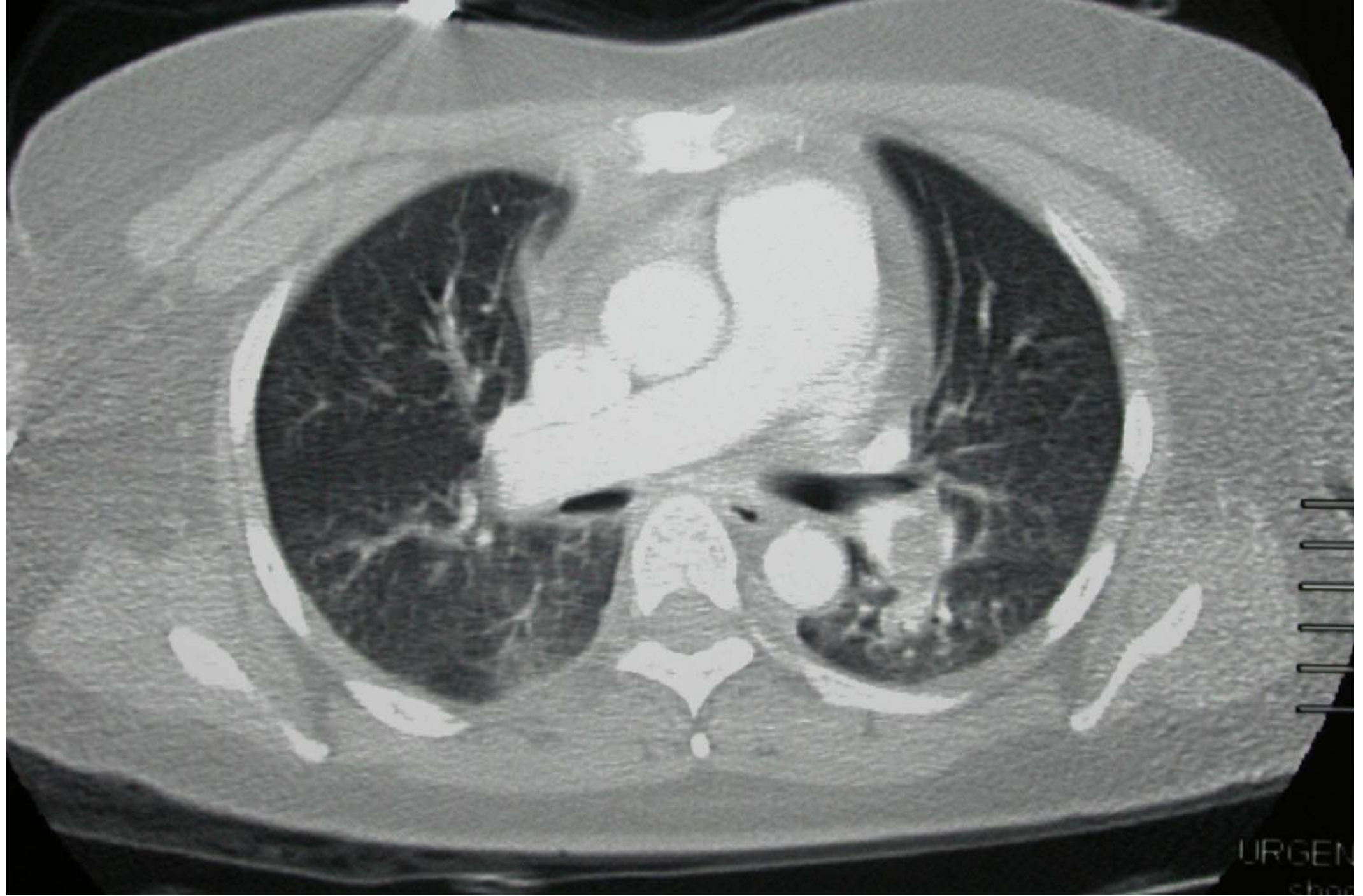
A close-up, high-angle shot of a woman's face. She is wearing dark, wrap-around sunglasses. Her eyes are closed, and her expression is serene. Her lips are slightly parted, showing a soft pink lipstick. The lighting is soft and directional, coming from the upper right, casting gentle shadows on her face. Her dark, curly hair is visible on the left side of the frame.

Bedside US abdomen: small amount of free fluid

Consulted ICU: CT thorax & abdomen before admission

SBP 70mmHg after 4L fluid and 2u unmatched blood

# PROGRESS



CT THORAX