

Hong Kong College of Emergency Medicine
Joint Clinical Meeting
OSCE by North District Hospital

Question 1:

A 35 year old man attended to A&E Department because of road traffic accident.

CT scan was taken. (Fig. 1a and 1b)

(a) Identify the abnormality in the CT scan (3 marks)

(b) What do you expect in the physical examination (2 marks)

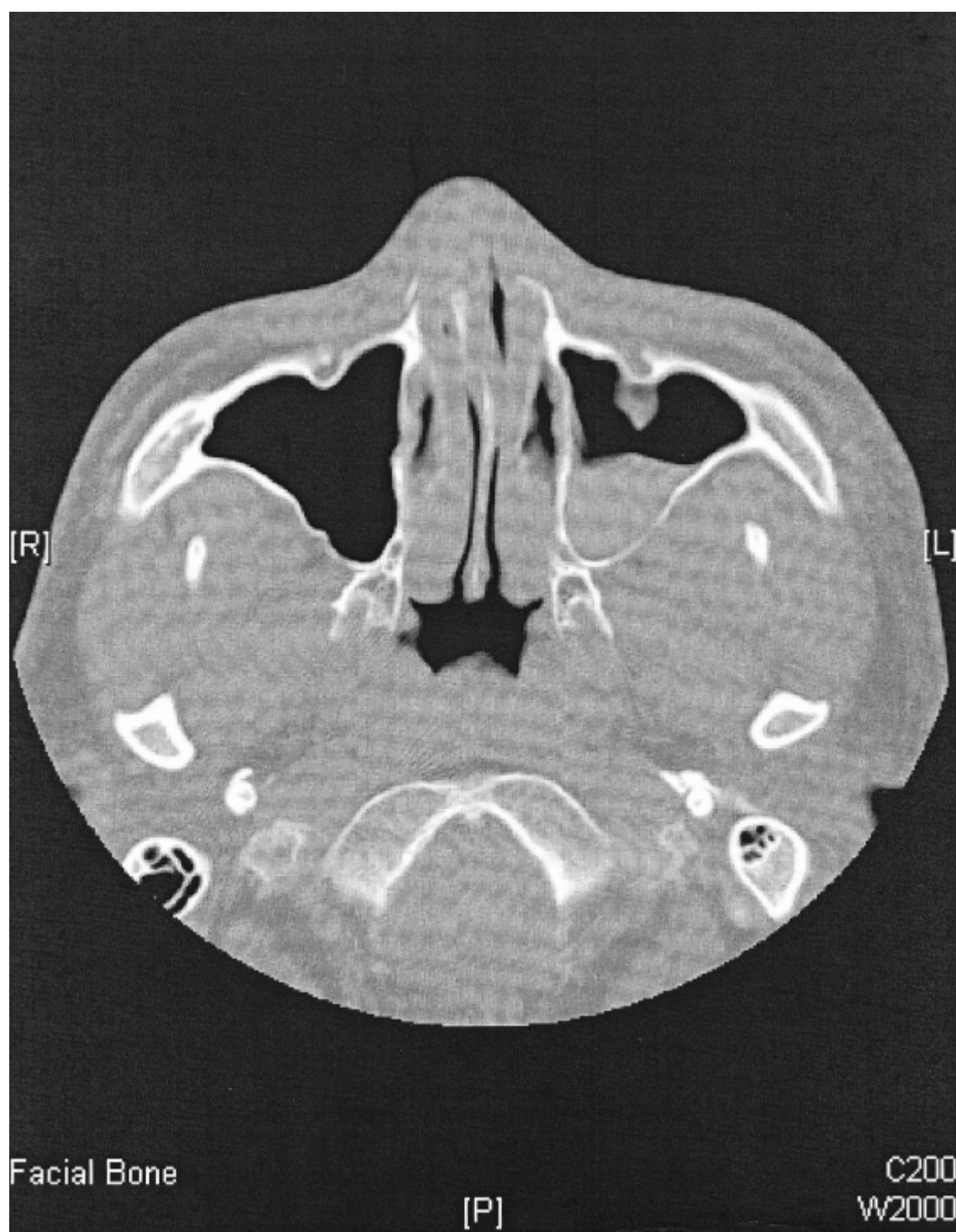


Fig. 1a

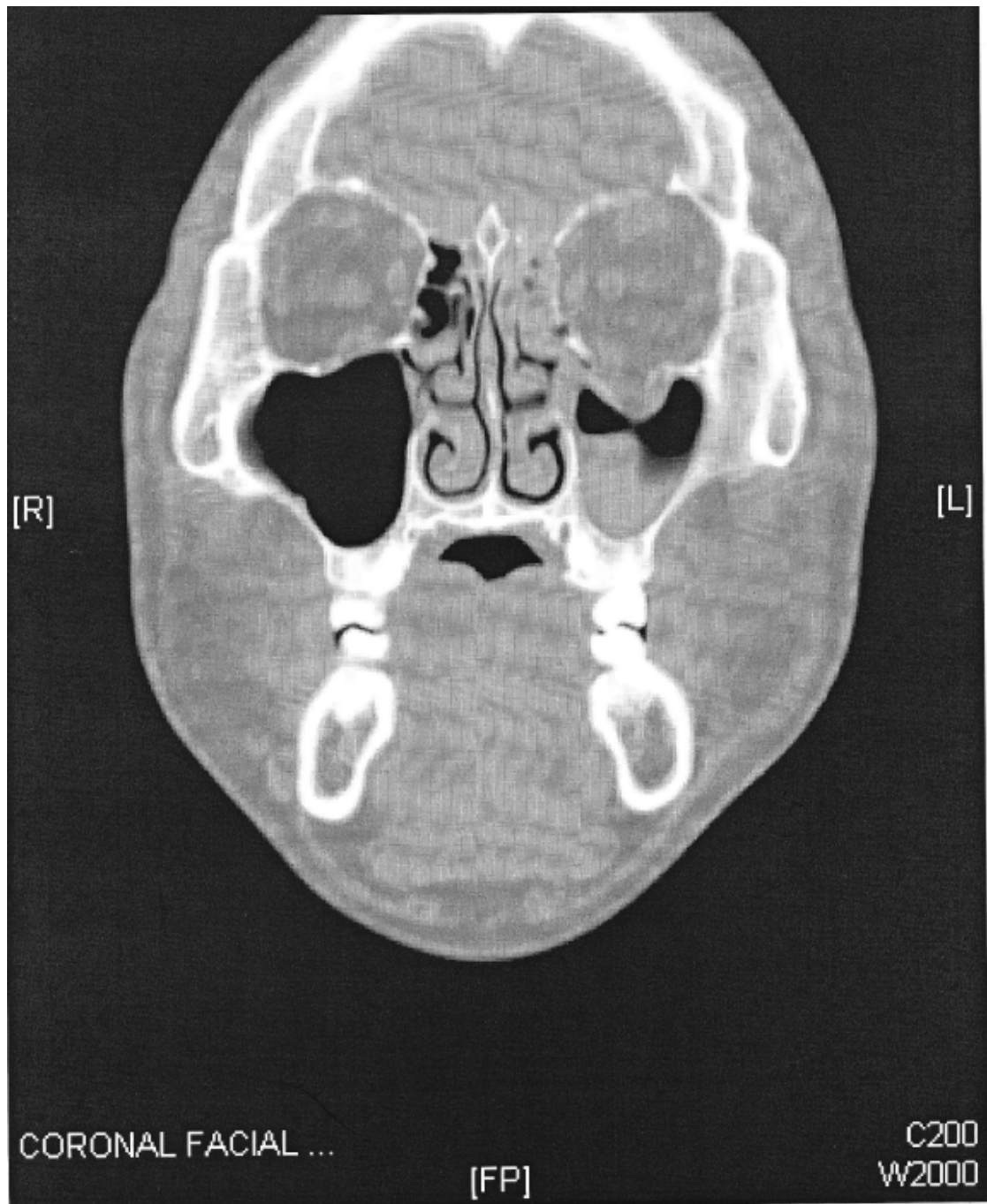


Fig. 1b

Question 2:

A 28 year old man complained of headache after he was punched by others in boxing game. No history of LOC or vomiting reported. Physical examination did not show any abnormality.

Plain CT brain was taken. (See the hard film posted up)

(a) What are the high risk factors for head injury (3 marks)

(b) Comment on the CT scan (2 marks)

Question 3:

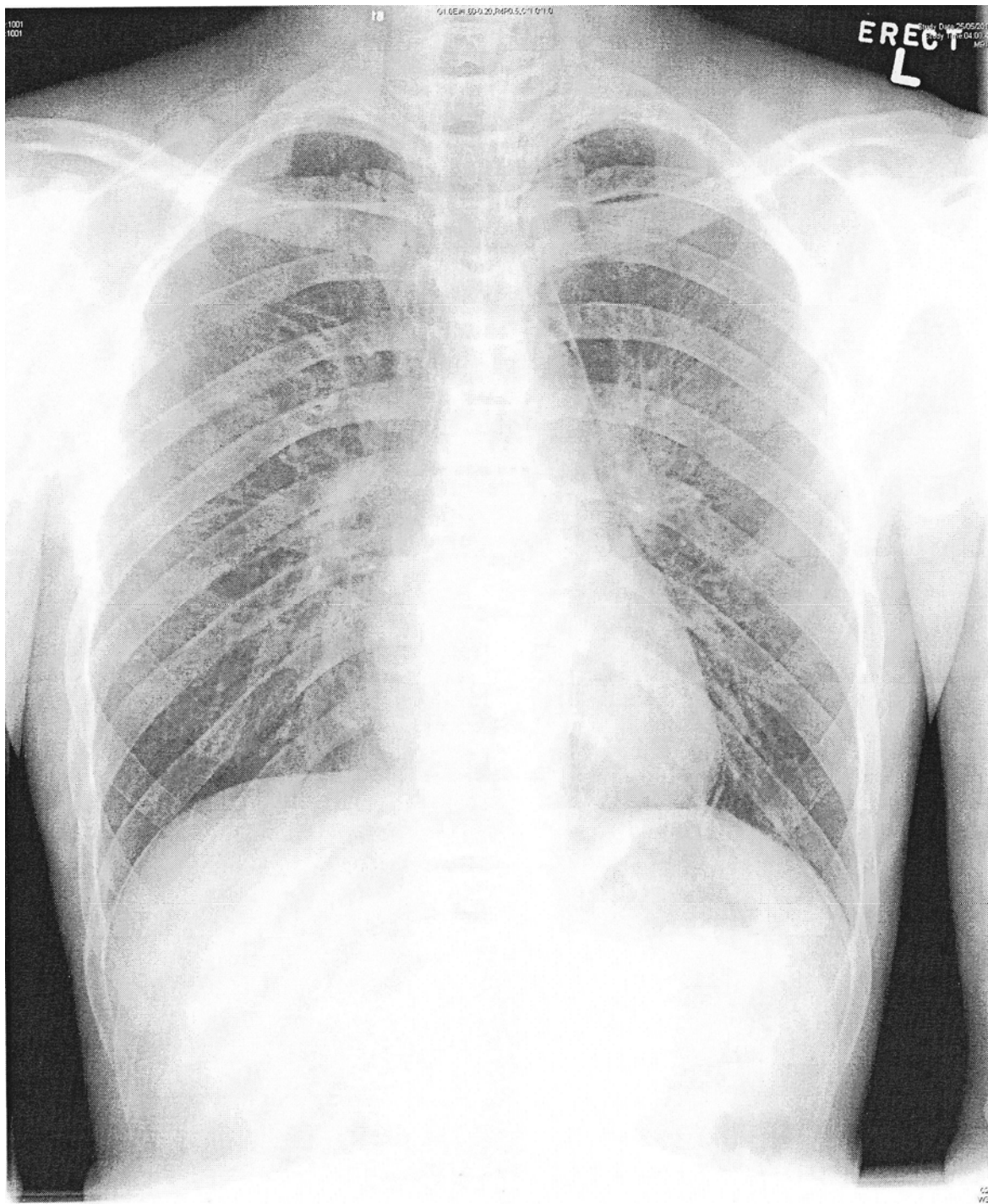
A 29 year old year old man complained of chest pain after ketamine inhalation.

Chest X-ray was taken. (Fig. 3)

(a) Describe the X-ray finding (1 mark)

(b) What is the diagnosis? (1 mark)

(c) Name three other possible causes for this condition (3 marks)



Question 4:

A 50 year old man complained of palpitation. On arrival, his BP was 138/78mmHg, pulse: 200/min.

ECG was taken. (Fig. 4)

- (a) Describe the ECG finding. (3 marks)
- (b) What is the diagnosis? (1 mark)
- (c) What is the treatment of choice (1 mark)

29-Jun-2010 14:55:28

NORTH DISTRICT HOSPITAL AED NO. 183078

(A&E)

Rate 199 . Extreme tachycardia, rate = 199
PR 0 . Right axis deviation
QRSD 133 . Right bundle branch block
QT 251 . Probable Lateral Subepicardial injury
QTc 457

--Axis--

P

QRS 236

T 44

- ABNORMAL ECG -

Unconfirmed diagnosis.

