OSCE

RHTSK A&E

4th September 2013

Case 1

- F/81
- PHx: Dementia/ Parkinsonism/ HT
- Decrease GC for few days
- Vital signs stable
- ECG done

ECG

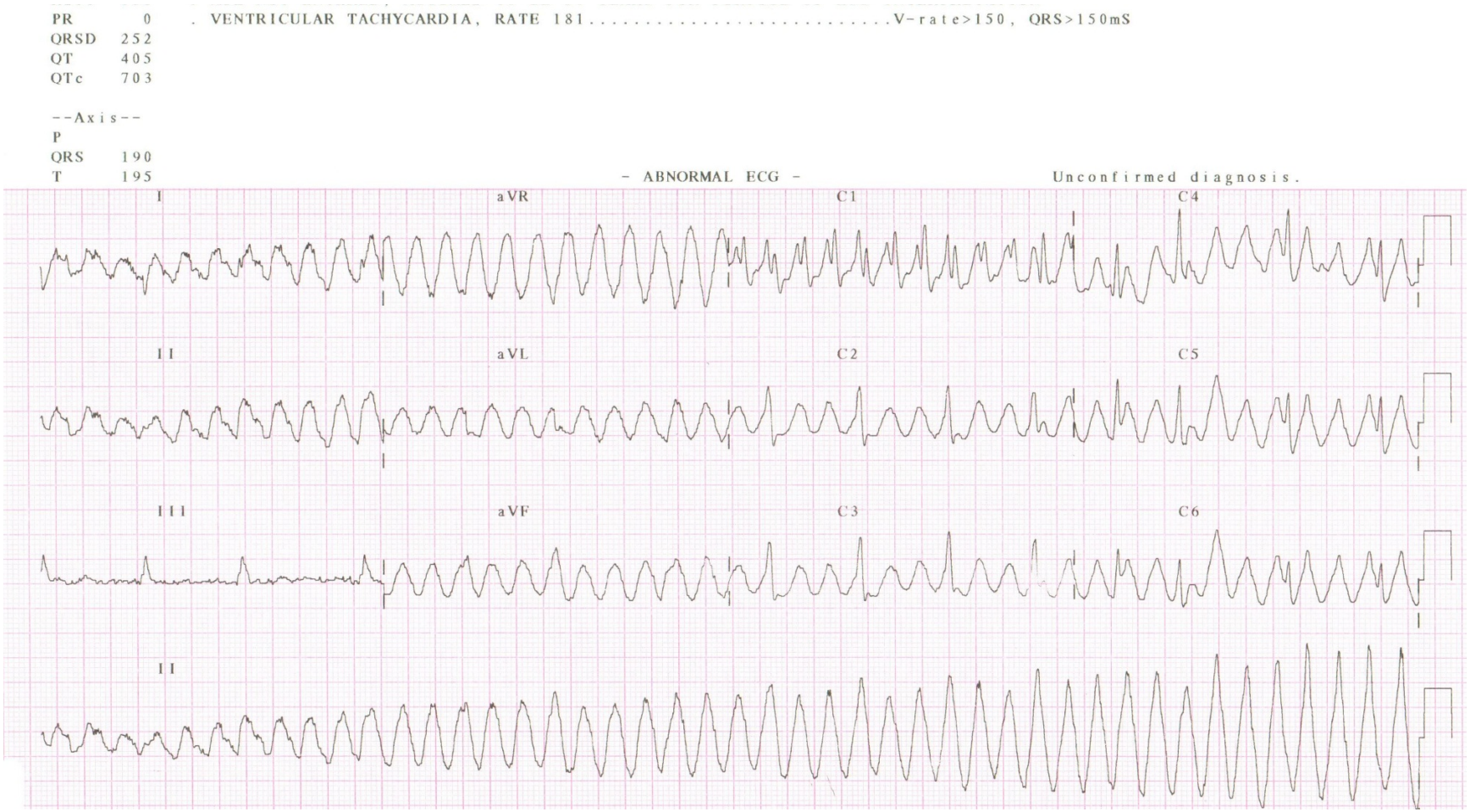
PR 0
QRSD 252
QT 405
QTc 703
. VENTRICULAR TACHYCARDIA, RATE 181.....V-rate>150, QRS>150mS
--Axis--
P
QRS 190
T 195
- ABNORMAL ECG -
Unconfirmed diagnosis.
I
aVR
C1
C4
II
aVL
C2
C5
III
aVF
C3
C6
II

Questions

1. The doctor considers the rhythm as VT. Do you agree? Give 1 reason.
2. What is your diagnosis and what can be done to confirm this?
3. Suggest 3 ECG features that suggest VT as the cause of wide-complex tachycardia.

Case 2

- F/53
- PHx: Good
- S/F resulting in left wrist painful swelling
- X-ray left wrist done

L

Se:2
Im:1
Study Date:04/04/2013
Study Time:16:14:25
MRN:
L
C16384
W16384

Question

1. Suggest 2 x-ray abnormalities?
2. What is the major pathophysiology of the deformity shown on the x-ray?
3. Suggest 1 image modality helpful to further delineate the injury
4. What is the management?

Case 3

- M/22
- PHx: Good
- c/o palpitation
- Vital signs stable except tachycardia
- ECG done

ECG

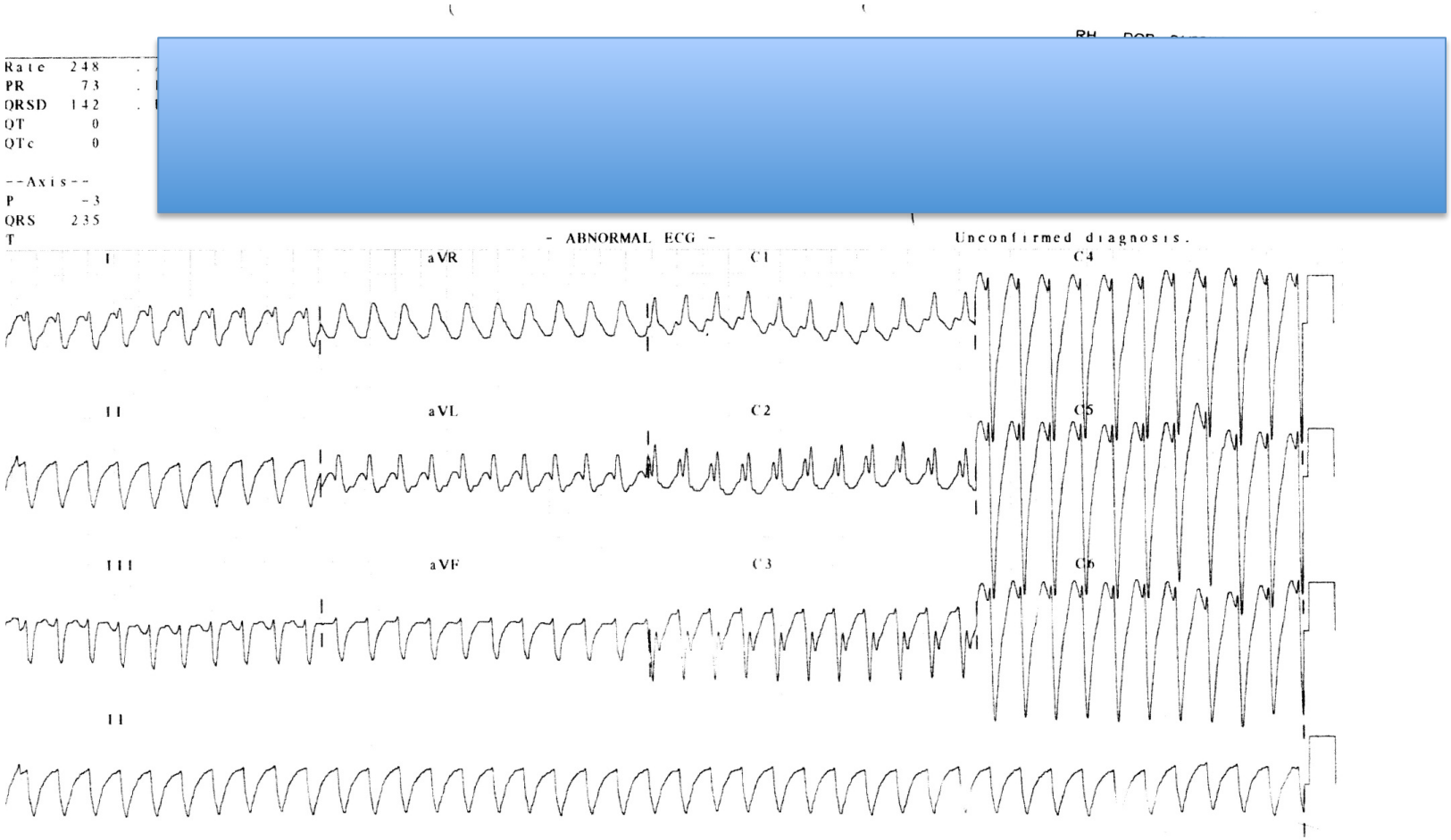
Rate 248
PR 73
QRSD 142
QT 0
QTc 0
--Axis--
P -3
QRS 235
T
- ABNORMAL ECG -
Unconfirmed diagnosis.
I
aVR
C1
C4
II
aVL
C2
C5
III
aVF
C3
C6
II

Question

1. What are the ECG findings?
2. What is the diagnosis?
3. Which class of drug should be used to terminate the rhythm?
4. What is the underlying pathophysiology of the rhythm?
5. Suggest 3 more investigations helpful to delineate the diagnosis
6. What is the definitive treatment?

Case 4

- F/41
- Good past health, on OCP
- Brought to AED after 1 episode of convulsion
- Regained consciousness few minutes later
- c/o headache in the past few days
- P/E: Fully conscious, no focal neurological sign, vital signs stable, h'stix 6.8
- No scalp wound
- Another episode of convulsion at AED, lasting for 1 minute

Case 4

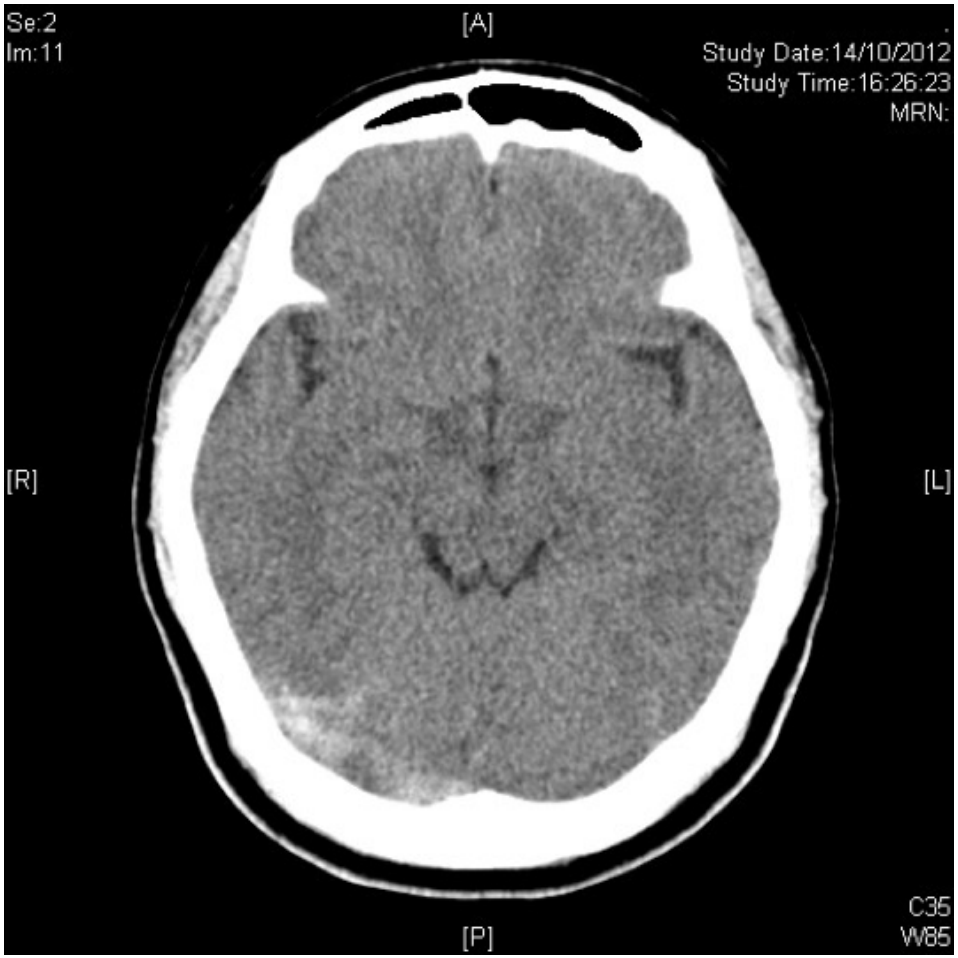
Se:2
Im:11
[A]
Study Date:14/10/2012
Study Time:16:26:23
MRN:
[R]
[L]
[P]
C35
W85

Question

1. Name 2 differential diagnosis
2. Name 1 investigation to confirm the diagnosis
3. Suggest 2 risk factors.
4. What is the treatment?

Case 5

- F/83
- PHx: Dementia
- Found painful swelling and bruise at left foot for 2 days, after falling from bed
- X-ray done

Study Date:21/08/201
Study Time:9:31:3
MRN
C1638
W1638

Se:2
Im:1
Study Date:21/08/2013
Study Time:9:31:39
MRN
C16384
W16384

Question

1. Suggest 2 radiological abnormalities
2. What other x-ray view can be done to confirm diagnosis?
3. Suggest 1 investigation that helps confirming diagnosis and guiding management
4. Name 1 classification based on this imaging modality.
5. Suggest 3 indications of operative management of this injury