

# HKCEM JCM OSCE by PMH

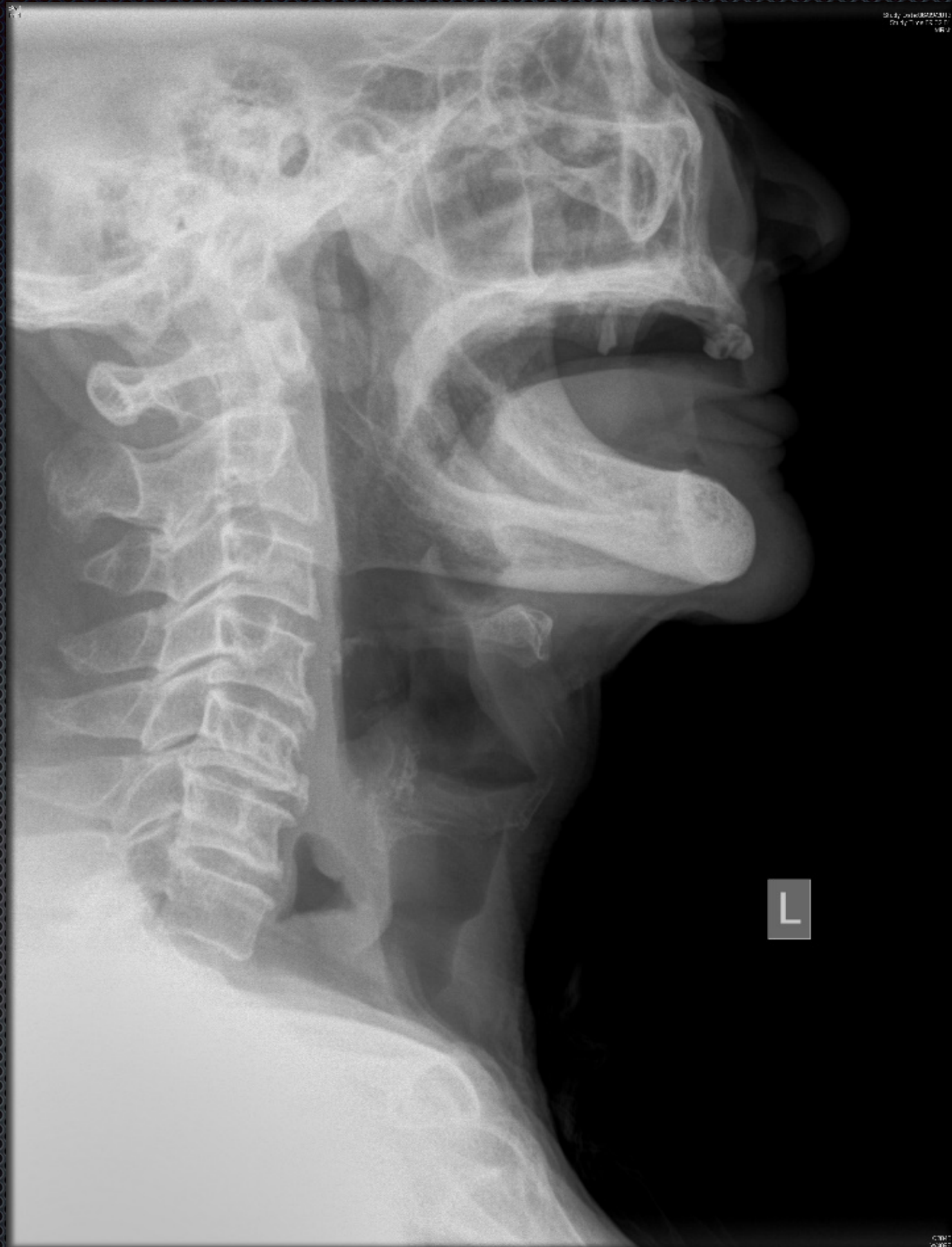4 Dec 2010



# Case 1

- ✦ M/74, PMHx: Alcoholic liver disease, depression
- ✦ C/O progressive sore throat for 1 week, worse today.
- ✦ Odynophagia and dysphagia now
- ✦ Tolerated soft diet only but difficult







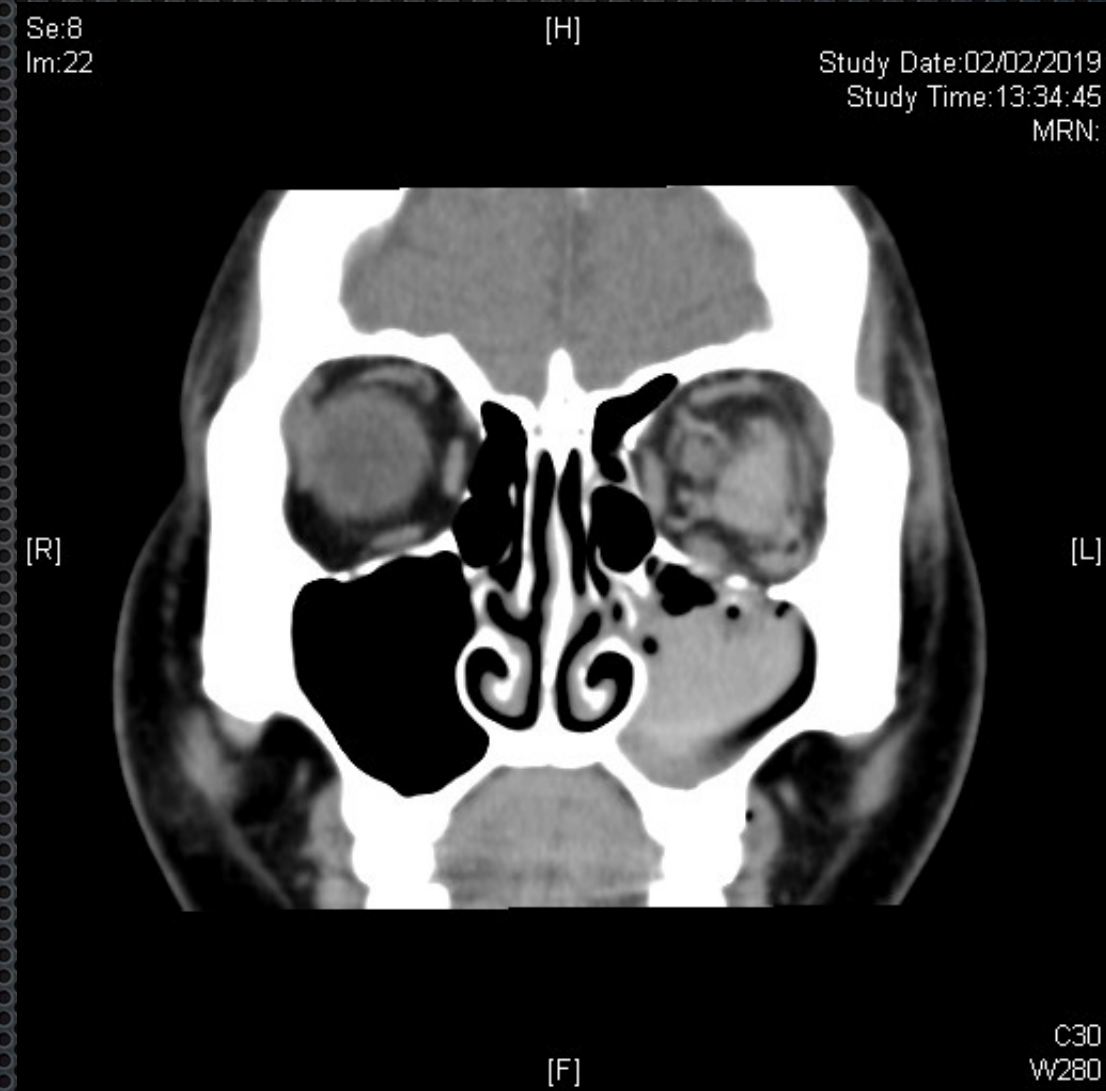
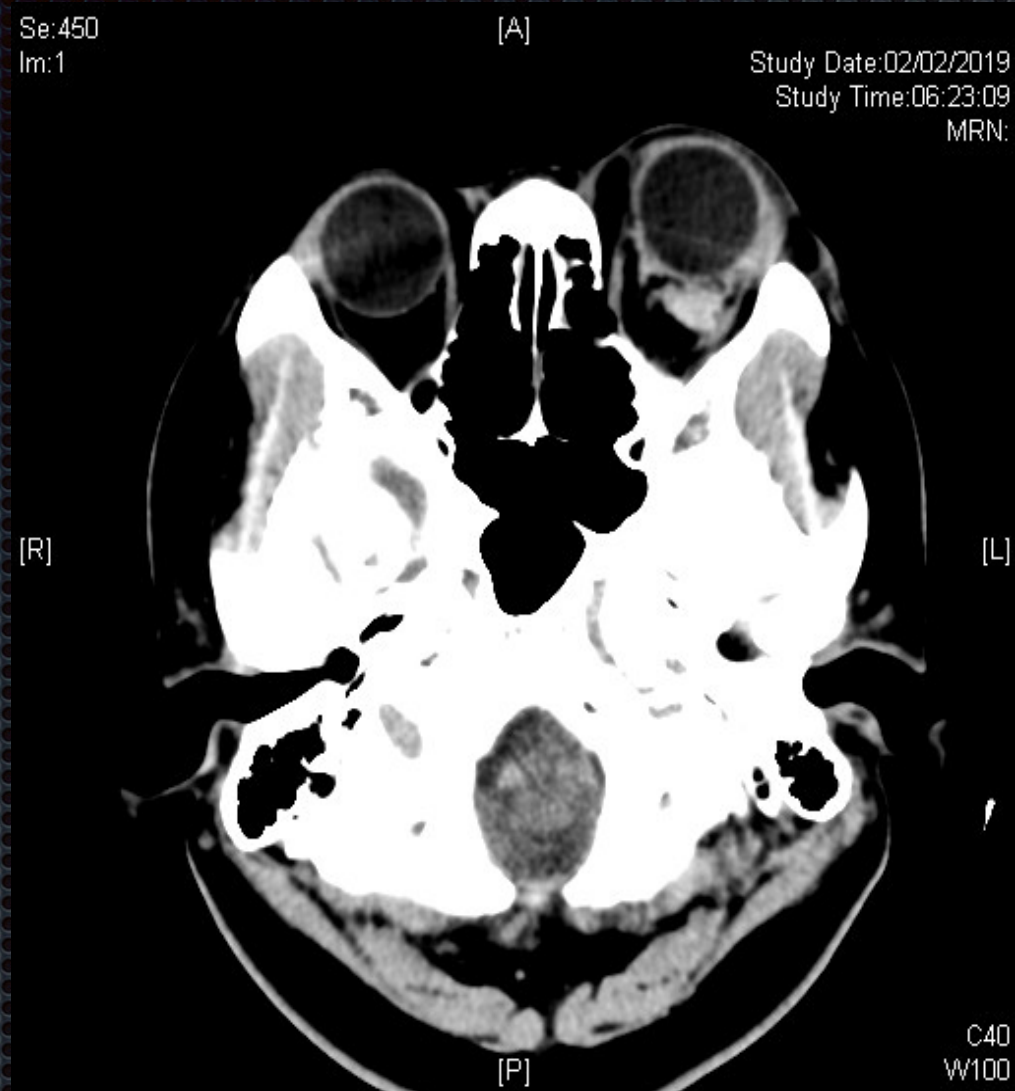
- ✦ 1. State 2 abnormalities on the x-ray. (1mark)
- ✦ 2 What is the most likely diagnosis.(0.5mark)
- ✦ 3. What is the most common focus of the condition in 2? (0.5mark) What about its usual causative agent? (1 mark)
- ✦ 4. What are the mainstay of management if CT neck confirmed your diagnosis? (1 mark)
- ✦ 5. Name 2 complications (1mark)



# Case 2

- ✦ F/27
- ✦ Battered spouse
- ✦ Argue with boyfriend after they both got drunk
- ✦ Left eye hit by her boyfriend's elbow during the fight
- ✦ Left eye and periorbital swelling, painful, cannot open





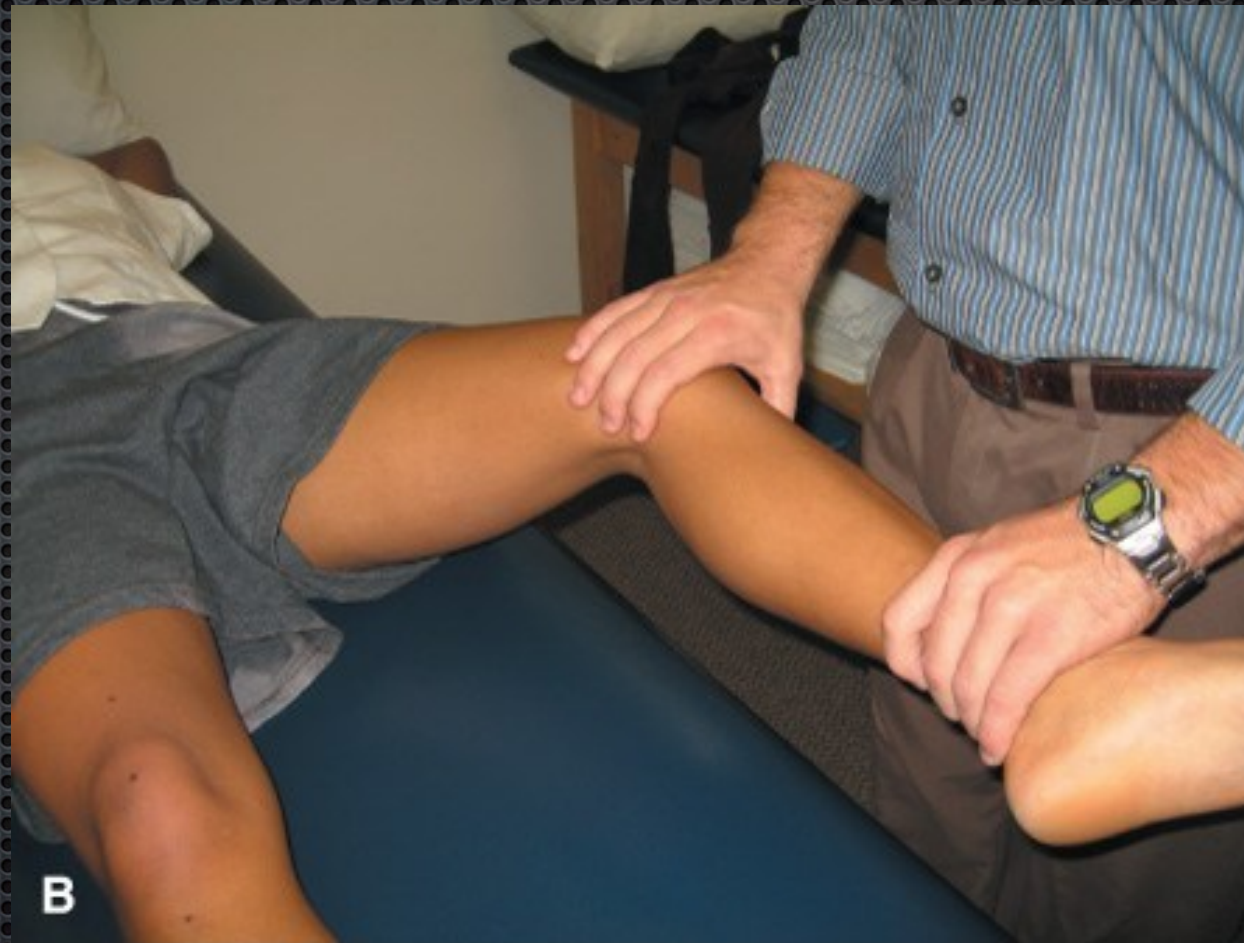

- ✦ 1. What's your expected physical exam finding if she could cooperate examination?(List 3, 1.5marks)
- ✦ 2. Name 3 abnormalities in CT scan. (1.5marks)
- ✦ 3. What is the diagnosis? (1 mark)
- ✦ 4. If the patient complained of left eye vision lost, Name an urgent ophthalmological complication that might arise.(0.5mark)  
And what would you do in AED if ophthalmological assessment is not readily available? (0.5mark)



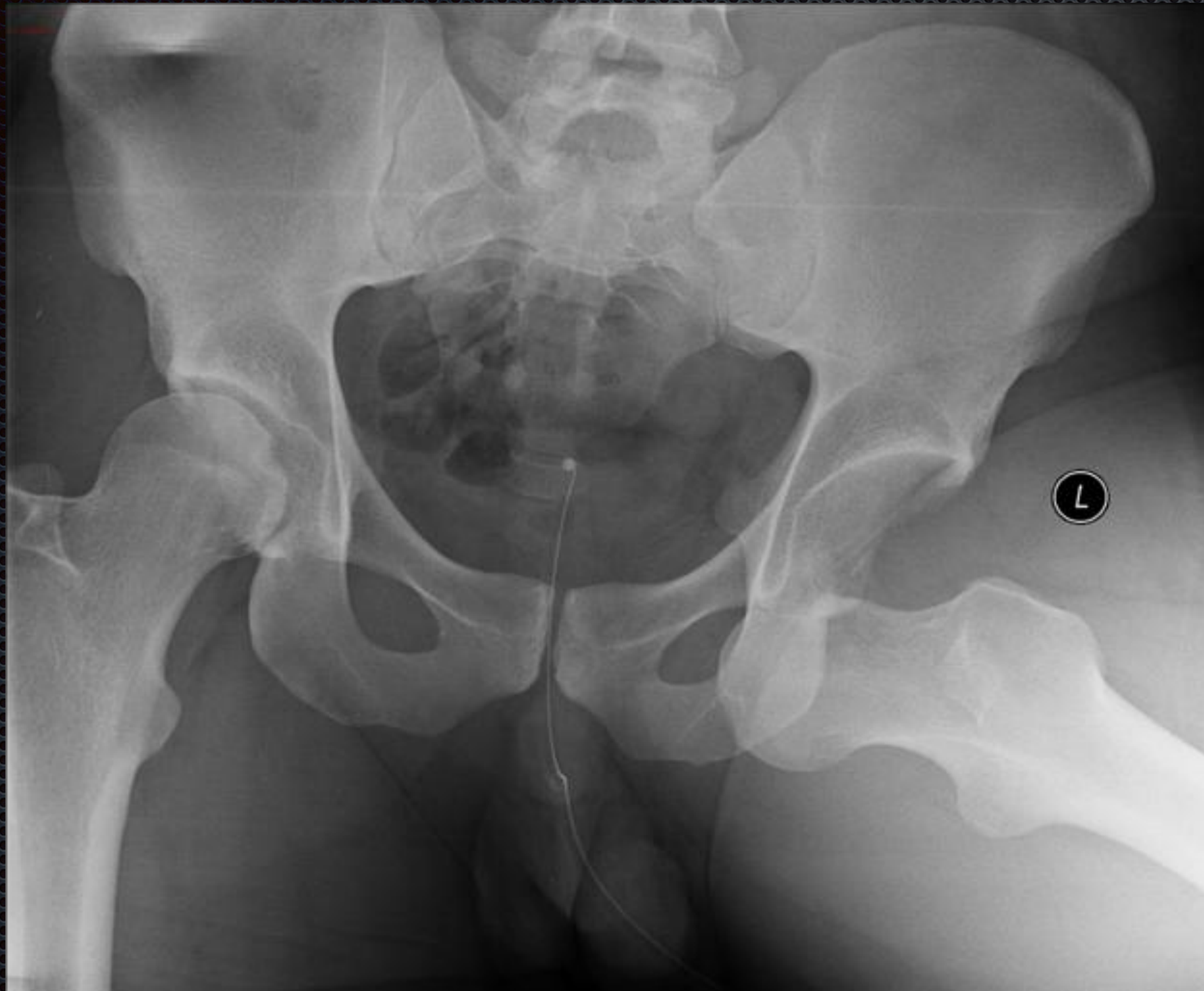
# Case 3

- ✦ M/69
- ✦ Fell off ladder while repairing air-conditioner at home



Source: Patel DR, Greydanus DE, Baker RJ: *Pediatric Practice: Sports Medicine*: [www.accesspediatrics.com](http://www.accesspediatrics.com)  
Copyright © The McGraw-Hill Companies, Inc. All rights reserved.





<https://radiopaedia.org/articles/anterior-dislocation-of-the-hip?lang=us>



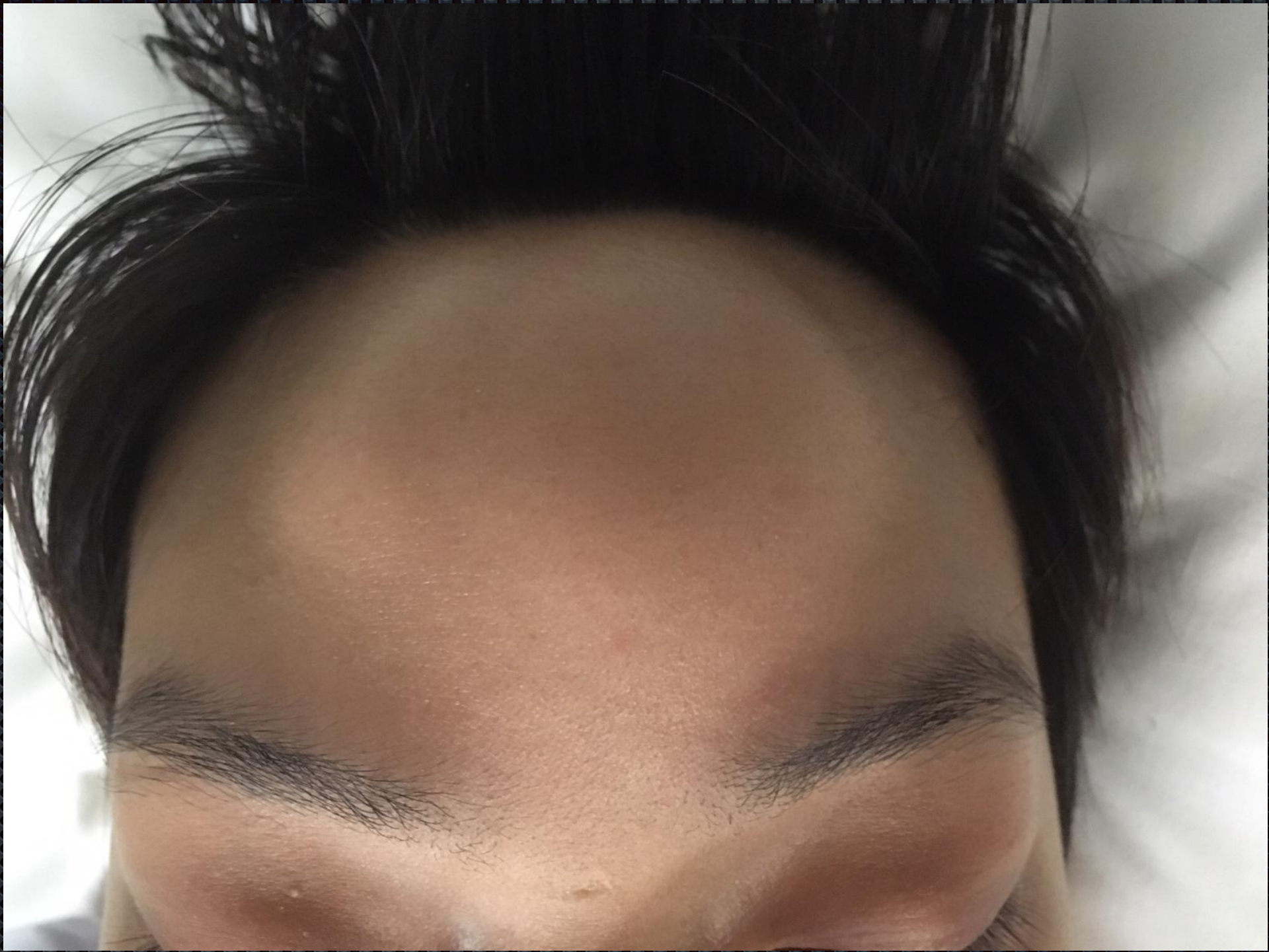- ✦ 1. Please describe the abnormality in the clinical photo. (1mark)
- ✦ 2. What is the Xray finding and your diagnosis? (1 mark)
- ✦ 3. What fracture is associated with your diagnosis stated above? List 2 (1mark)
- ✦ 4. How to treat this condition in AED? (1 mark)
- ✦ 5. What complications are associated with this injury? List 2 (1mark)



# Case 4

- ✦ M/25
- ✦ Good past health
- ✦ Headache for 1 week
- ✦ Fever 38.5C
- ✦ BP 120/85, Pulse 105/min
- ✦ Confusion, frontal swelling







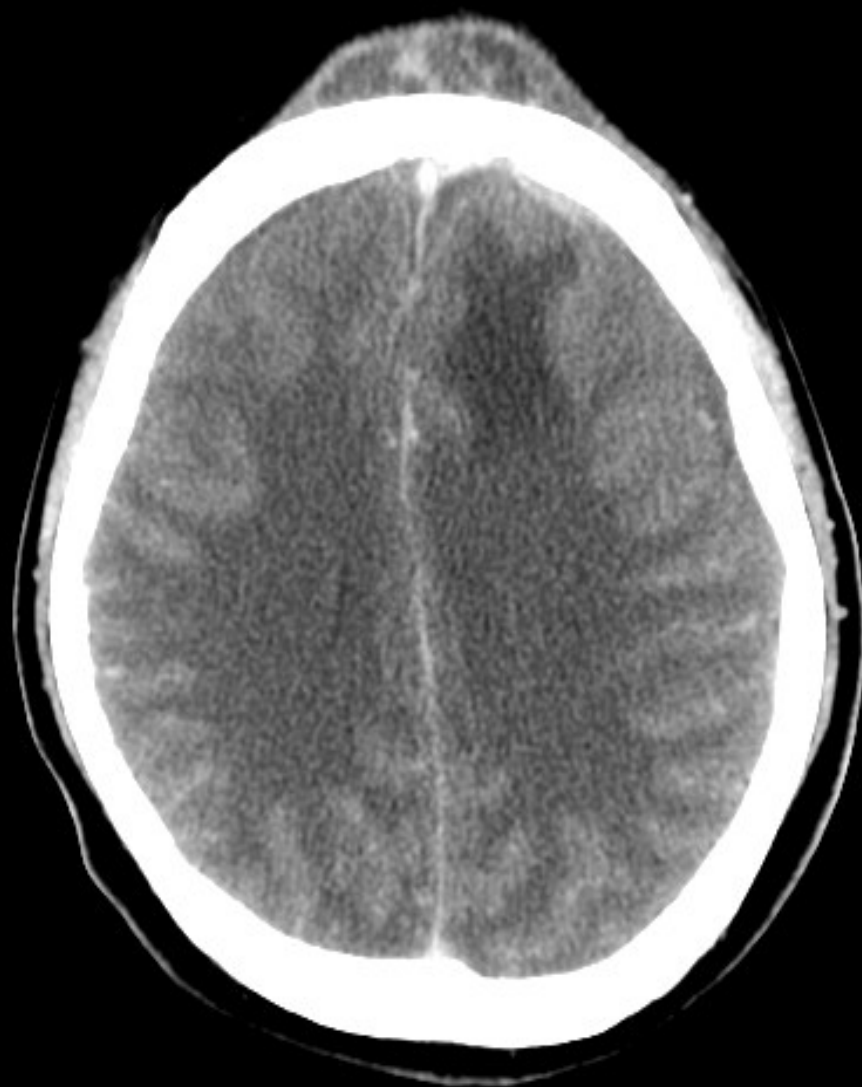Se:5  
Im:18

[AH]

5

Study Date:16/01/2019 5  
Study Time:07:02:31  
MRN:

[R]



50ml omni 300

[PF]

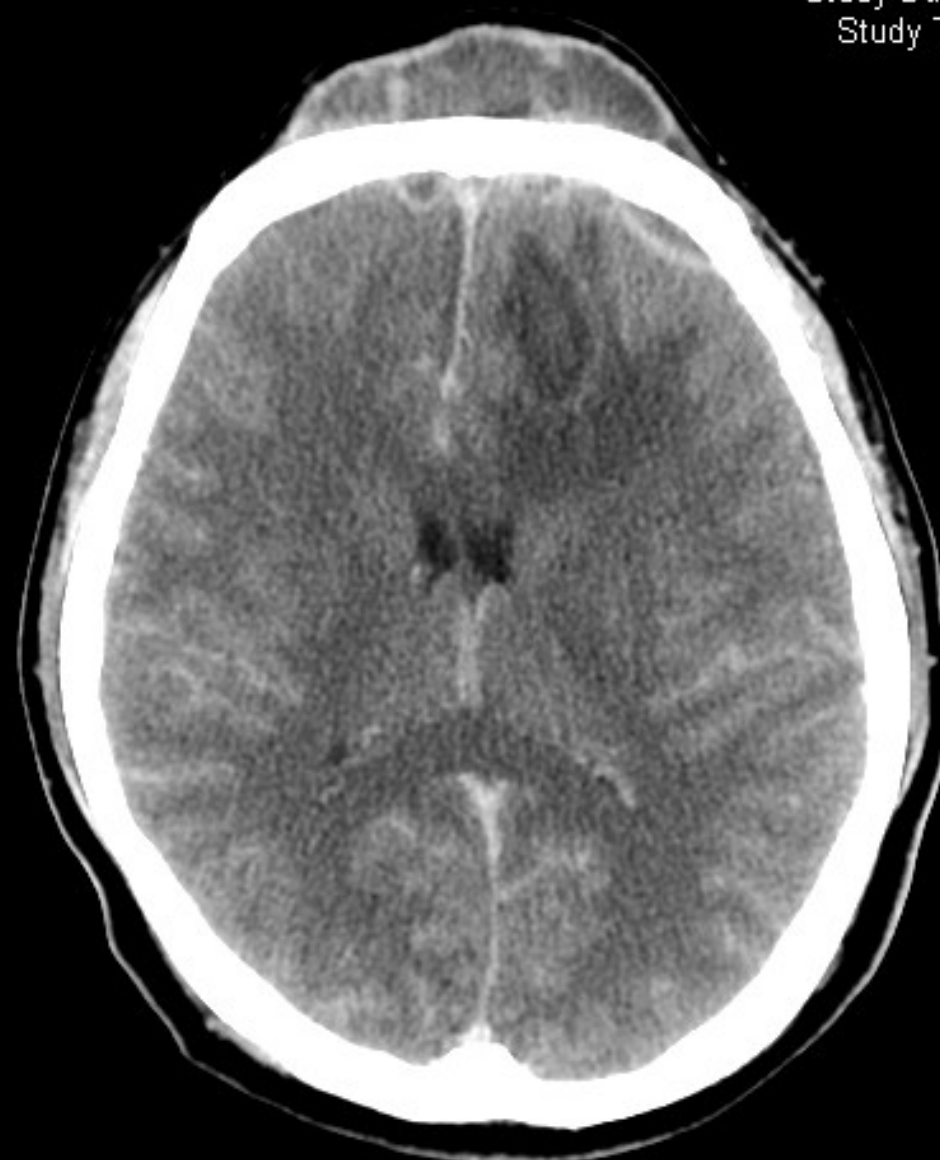
[L]

C40  
W100 il omni 300

[AH]

Study Date:16/01/2019  
Study Time:07:02:31  
MRN:

[L]



C40  
W100



- ✦ 1. State the abnormalities on contrast CT brain. Give 3 (1.5mark)
- ✦ 2. What is your diagnosis? (0.5mark)
- ✦ 3. What are the 2 commonest causes of the condition mentioned above? (2 marks)
- ✦ 4. What are the most common causative agents? List 2 (1mark)



• End