

HKCEM Primary Examination in Emergency Medicine (PEEM) Sample Questions

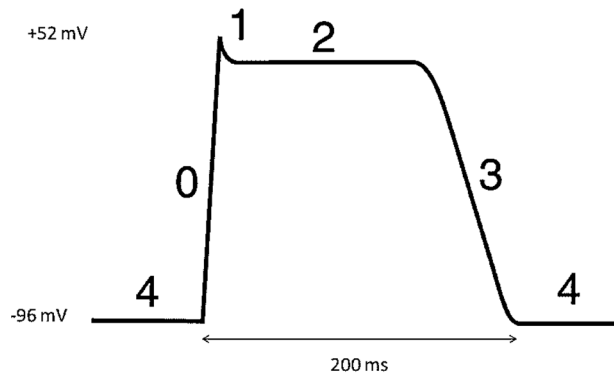
Updated May 2021

1. A 19-year-old woman with a history of asthma presents with shortness of breath.  
Which of the following blood gas parameters is the earliest abnormal result?
  - A. Low pH
  - B. Low pCO<sub>2</sub>
  - C. Low pO<sub>2</sub>
  - D. High HCO<sub>3</sub>
  - E. High base excess (BE)
  
2. A 62-year-old woman with a total hysterectomy and bilateral salpingo-oophorectomy performed one week ago for endometrial carcinoma presents with shortness of breath. Pulmonary embolism is suspected, and an electrocardiogram (ECG) is performed.  
Which of the following is the most common ECG finding in this patient?
  - A. Atrial fibrillation
  - B. Junctional rhythm
  - C. Left bundle branch block pattern
  - D. Sinus tachycardia
  - E. SIQIIITIII pattern
  
3. A 3-year-old boy presents with fever and diarrhoea. Rotavirus infection is suspected.  
Which of the following is the most common route of transmission for this virus?
  - A. Airborne
  - B. Contact
  - C. Droplet
  - D. Faecal-oral
  - E. Zoonotic

4. A 72-year-old man is admitted for a diazepam overdose. Which of the following is the dominant receptor triggered by this drug?
- A. Gamma-Aminobutyric acid (GABA)
  - B. Glutamate
  - C. N-Methyl-D-aspartic acid (NMDA)
  - D. Protein kinase
  - E. Serotonin
5. A 40-year-old woman presents with a right knee penetrating injury. Examination reveals a foot drop. Which of the following nerves is most likely to be injured?
- A. Deep peroneal
  - B. Obturator
  - C. Saphenous
  - D. Superficial peroneal
  - E. Tibial
6. A 50-year-old man presents with chest pain. An electrocardiogram shows ST-segment elevation over V1-V4. Which artery is most likely to be occluded?
- A. Left anterior descending
  - B. Left circumflex
  - C. Left main coronary
  - D. Posterior descending
  - E. Right coronary
7. A 32-year-old man develops a skin rash after intravenous analgesia for a femur supracondylar fracture. Histamine release is suspected. Which of the following is the most likely analgesia?
- A. Buprenorphine
  - B. Fentanyl
  - C. Morphine
  - D. Oxycodone
  - E. Tramadol

8. A 78-year-old man with chronic obstructive pulmonary disease presents with type II respiratory failure and carbon dioxide retention. Which is the predominant form of carbon dioxide transported in the blood?
- A. Bicarbonate
  - B. Carbaminohaemoglobin
  - C. Carbonic acid
  - D. Carboxyhaemoglobin
  - E. Dissolved carbon dioxide
9. A 6-year-old girl presents with fever and a temperature of 40.3 degrees Celsius. Which of the following areas of the brain contains the thermosensitive neurons that control the temperature set point in thermoregulation?
- A. Hypothalamus
  - B. Medullary oblongata
  - C. Pineal gland
  - D. Pituitary gland
  - E. Pons
10. A 4-year-old boy presents with general oedema and proteinuria. Nephrotic syndrome is suspected. Which of the following is the most probable renal pathological finding?
- A. Membranous glomerulonephropathy
  - B. Membranoproliferative glomerulosclerosis
  - C. Mesangial proliferation
  - D. Minimal change disease
  - E. Proliferative glomerulonephritis

11. A 54-year-old woman presents with recurrent syncopal episodes due to prolonged QT syndrome. The image below shows the different phases (0, 1, 2, 3 and 4) of the action potential of a normal ventricular myocyte.



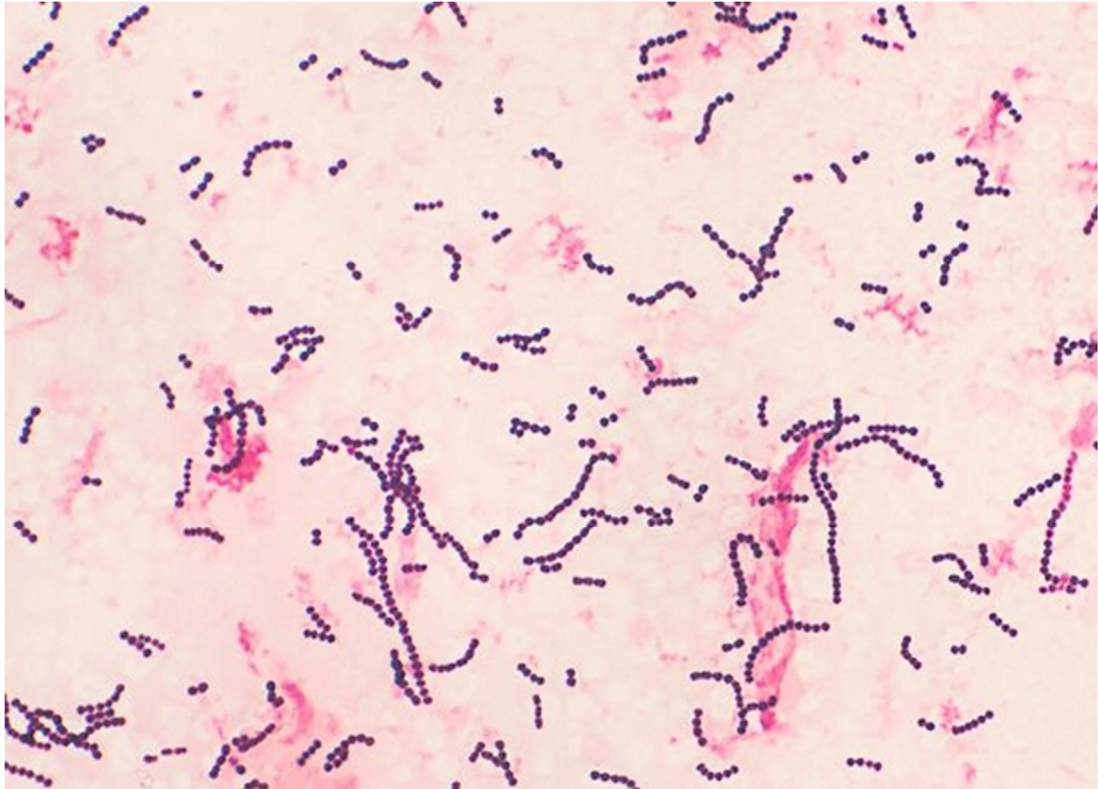Which phase is affected in her condition?

- A. 0
  - B. 1
  - C. 2
  - D. 3
  - E. 4
12. A 30-year-old woman presents with two days of fever associated with a generalized rash. She has oral ulcers and bilateral injected conjunctiva. She was recently treated for acne vulgaris. Which medication is the most likely cause of her condition?
- A. Benzoyl peroxide
  - B. Clindamycin
  - C. Co-trimoxazole
  - D. Erythromycin
  - E. Minocycline

13. A 35-year-old woman was diagnosed with hyperthyroidism and started on propylthiouracil.  
Which of the following system should be monitored for potentially severe side effects?
- A. Cardiovascular
  - B. Haematologic
  - C. Musculoskeletal
  - D. Neurologic
  - E. Renal
14. A 35-year-old man presents with bilateral epistaxis. Examination reveals bleeding in the nasopharyngeal region.  
What is the most likely type of bleeding structure?
- A. Arterial
  - B. Capillary
  - C. Haemangioma
  - D. Telangiectasia
  - E. Venous
15. A 24-year-old Malay woman presents with exertional dyspnea and a haemoglobin level of 6 g/dl. There is conjunctival pallor, frontal bossing, dental malocclusion and hepatosplenomegaly.  
What is the inheritance pattern of this condition?
- A. Autosomal dominant
  - B. Autosomal recessive
  - C. Mitochondrial
  - D. X-linked dominant
  - E. X-linked recessive

16. A 35-year-old man presents with right leg redness and swelling after getting injured while hiking. Examination reveals severe tenderness on palpation and the presence of bullous lesions.

Gram stain of the tissue is as shown.



What is the causative agent of this disease?

- A. *Clostridium difficile*
- B. Group A Streptococcus
- C. *Haemophilus influenzae*
- D. *Pseudomonas aeruginosa*
- E. *Staphylococcus aureus*

17. A 65-year-old woman with rheumatoid arthritis presents with a deformity of the left elbow for two months associated with pain around the medial epicondyle and numbness of the little finger.

Which motor function will remain fully preserved?

- A. Finger abduction
- B. Finger adduction
- C. Thumb adduction
- D. Thumb flexion
- E. Wrist flexion

18. A 70-year-old man presents with frequent falls over the past 6 months. He has mask-like facies, pill-rolling tremors, lead pipe rigidity and a shuffling gait.

Which neurotransmitter is involved?

- A. Dopamine
- B. Gamma-aminobutyric acid
- C. Glutamate
- D. Histamine
- E. Serotonin

19. A 20-year-old woman presents with recurrent breathlessness. She has a history of eczema and allergic rhinitis. Auscultation of her lungs reveals bilateral wheeze.

What is the most likely finding on spirometry?

- A. Bronchodilator Reversibility
- B. Decreased FVC
- C. Increased FEV1
- D. Increased FEV1/FVC
- E. Increased Peak Flow

20. A 26-year-old motorcyclist presents after a motor vehicle accident. After an initial loss of consciousness at the scene, his GCS is 15 at the Emergency Department. His CT brain scan shows a right temporoparietal extradural haemorrhage.

Which vessel is injured in this type of injury?

- A. Anterior cerebral artery
- B. Bridging cerebral vein
- C. Middle meningeal artery
- D. Posterior communicating artery
- E. Superior sagittal sinus

SAMPLE



**Answers**

1. B, Low pCO<sub>2</sub>
2. D, Sinus tachycardia
3. D, Faecal-oral
4. A, Gamma-Aminobutyric acid (GABA) receptor
5. A, Deep peroneal nerve
6. A, Left anterior descending artery
7. C, Morphine
8. A, Bicarbonate
9. A, Hypothalamus
10. D, Minimal change disease
11. C, 2
12. C, Co-trimoxazole
13. B, Haematologic
14. A, Arterial
15. B, Autosomal recessive
16. B, *Group A Streptococcus*
17. D, Thumb flexion
18. A, Dopamine
19. A, Bronchodilator reversibility
20. C, Middle meningeal artery